

Langerhans Cell Sarcoma – Review of Literature and a Rare Case Report

Lakshmaiah KC^{1*}, Smitha CS¹, LokanathaD¹, Linu AJ¹, Premalata CS², Usha A² and Aparna S¹

¹Department of Medical Oncology, KIDWAI Memorial Institute of Oncology, Bangalore, India

²Department of Pathology, KIDWAI Memorial Institute of Oncology, Bangalore, India

*Corresponding author: Lakshmaiah KC, Professor and Head, Department of Medical Oncology, KIDWAI Memorial Institute of Oncology, Bangalore 560029, Karnataka, India, Tel: +91 9448055949; E-mail: kcluck@gmail.com

Rec date: Mar 27, 2014; Acc date: Apr 24, 2014; Pub date: Apr 28, 2014

Copyright: © 2014 Lakshmaiah KC, et al. This is an open-access article distributed under the terms of the Creative Commons Attribution License, which permits unrestricted use, distribution, and reproduction in any medium, provided the original author and source are credited.

Abstract

Langerhans Cell Sarcoma (LCS) is extremely rare, with only 37 cases reported in English literature. We present the case of a 38 year old woman with a 2 month history of left neck swelling and pain. A diagnosis of LCS was made based on pathological findings of the biopsy of the tonsil. IHC on the neoplastic cells was positive for LCA, S100, CD 68 and CD1a (with membranous and paranuclear dot like patterns). A literature review is also presented to enhance the understanding of LCS and the importance of early diagnosis and treatment of this unusual lesion.

Keywords: Langerhans Cell Sarcoma; LCS; CD1a; Birbeck granules

Background

Langerhans Cell Sarcoma (LCS) is a rare high-grade neoplasm with overtly malignant cytologic features and aggressive clinical course [1]. Skin and underlying soft tissue are the most common sites involved, but other unusual locations, such as the bone [2], lung [3], gallbladder and peritoneal lymph nodes [4] are also described as being involved in literature. According to the English-language literature to date, only 37 LCS cases (including the present case) have been reported [5].

In this case report, the findings of a lady with only bilateral cervical lymphadenopathy, who was diagnosed to be suffering from Langerhans Cell Sarcoma are described. From our literature review and to the best of our knowledge, this is the first such reported case from India in literature.

Case Report

A 38 year lady presented to our outpatient department in February 2014 with complaints of swelling in both sides of neck since 2 months. The swelling was insidious in onset, with a sudden increase in size and pain since 2 weeks. There was no associated B symptoms, cough, headache, change in voice, dysphagia or any bony pains.

On clinical examination, ECOG performance status was 1 and vitals were stable. Examination of the oral cavity revealed an ulceroproliferative growth arising from the left tonsil, extending medially upto the uvula, anteriorly upto the posterior aspect of the anterior tonsillar pillar, and posteriorly upto the posterior pharyngeal wall. There was an enlarged conglomerate mass measuring 15×10 cms in the left cervical region involving level I, II, III, IV and V lymph nodes, firm to hard in consistency, non tender, with overlying skin stretched (Figure 1). Right level II and III lymph nodes were also enlarged, measuring 4×3 cms. Systemic examination was normal.

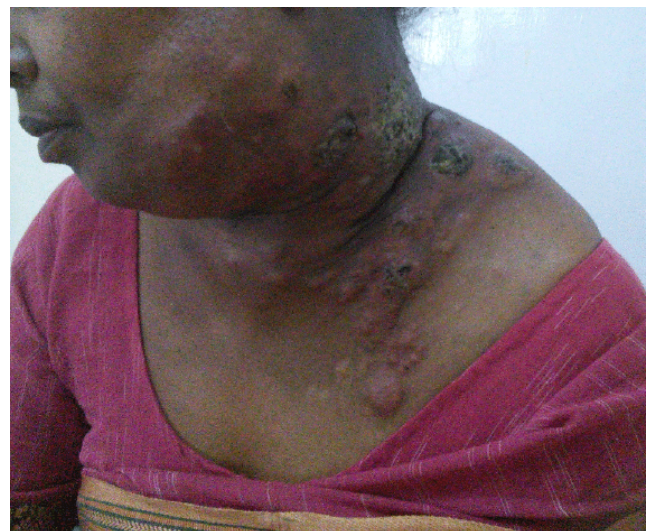

Figure 1: Enlarged conglomerate mass measuring 15×10 cms in the left cervical region involving level I, II, III, IV and V lymph nodes, lesion at presentation

Blood investigations showed the hemogram, liver function and renal function were normal. Serum LDH was found elevated.

CT scan imaging showed bulky left tonsil, left parapharyngeal and retropharyngeal space, heterogeneously enhancing conglomerate lymph node mass in bilateral cervical (left greater than right) areas, and left axillary and mediastinal lymphadenopathy (Figure 2).

FNAC of the cervical lymph node showed pleomorphic cells with large irregular nuclei with moderate amount of cytoplasm. Biopsy and IHC for categorization was advised. Tonsillar biopsy was done and H&E slides showed an undifferentiated malignant neoplasm showing sheets of large pleomorphic neoplastic cells with focal infiltration into overlying epithelium. The cells had irregular pleomorphic nuclei with some showing prominent nucleoli and moderate amount of

eosinophilic cytoplasm. IHC on the neoplastic cells was positive for LCA, S100, CD 68 and CD1a (with membranous and paranuclear dot like patterns) and negative for EMA, HMB45, CD30, CD5, CD7, CD79A, Pax5, MPO, CD3 CD20, ALK, MUM1, P16 and CK. (Figure 3) Bone scan showed multiple skeletal lesions.

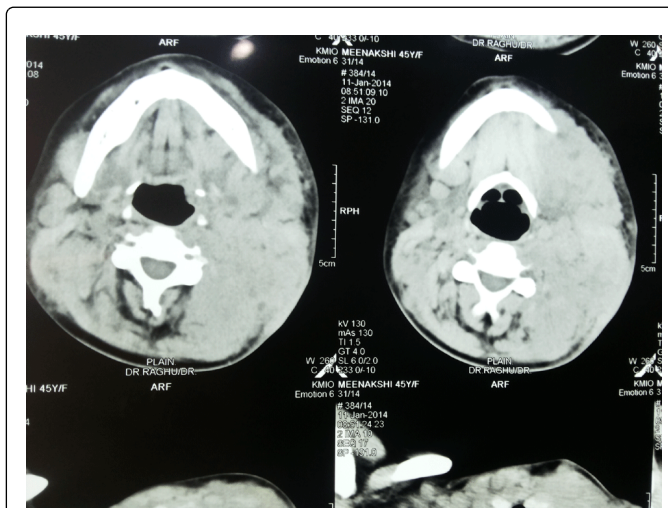


Figure 2: CT scan imaging showed bulky left tonsil, left parapharyngeal and retropharyngeal space, heterogeneously enhancing conglomerate lymph node mass in bilateral cervical areas, and left axillary and mediastinal lymphadenopathy

Cytogenetics revealed normal karyotype. The bone marrow was not involved. A final diagnosis of Langerhans Cell Sarcoma was made based on the clinical and pathological findings along with IHC report. Under electron microscopy, Birbeck granules were found to be negative.

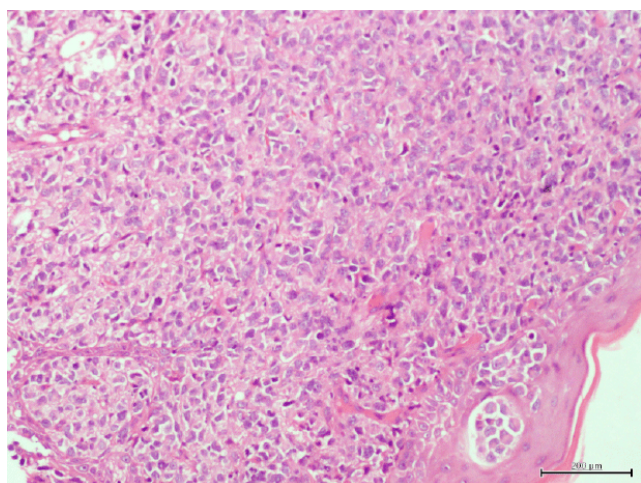


Figure 3a: Low power view

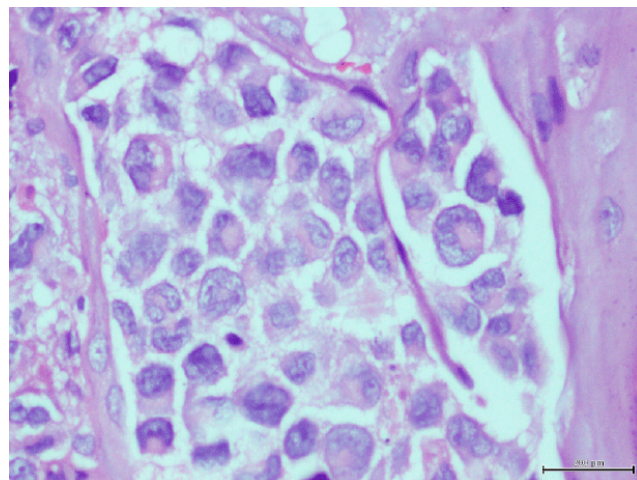


Figure 3B: High power view

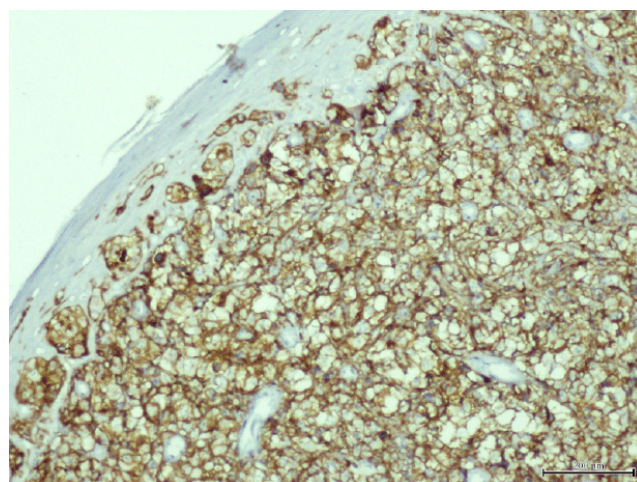


Figure 3C: LCA with positive and Membranous paranuclear dot

Discussion

The 2008 WHO Classification of Tumors of Hematopoietic and Lymphoid Tissues [1] classifies Langerhans Cell Sarcoma (LCS) as belonging to the category of histiocytic and dendritic cell neoplasms according to the degree of cytologic atypia and clinical aggressiveness [6]. It is a rare subtype of tumors derived from Langerhans cells, with a female predominance [1].

Langerhans cells are one subset of hematopoietic cells, thought to derive from monocyte-macrophage lineage. They are specialized dendritic cells in skin or mucosal sites devoted to antigen presentation to T cells upon activation. They then migrate to the lymph node through lymphatics. Physiologically, Langerhans cells can respond in a non-clonal fashion to certain reactive stimuli such as smoking, in the lung [7,8].

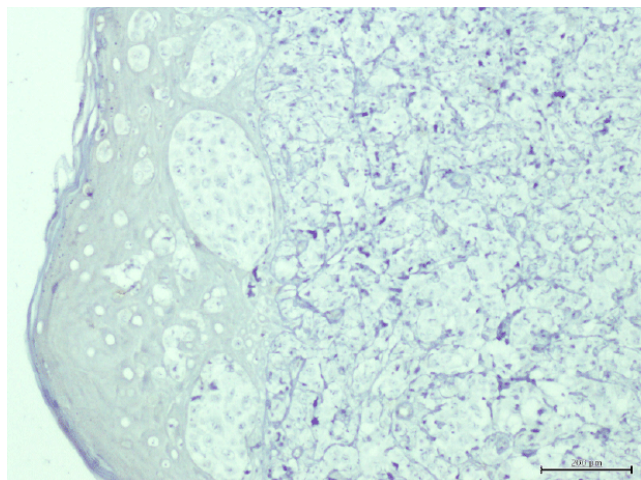


Figure 3D: S 100 with positive and Membranous paranuclear dot

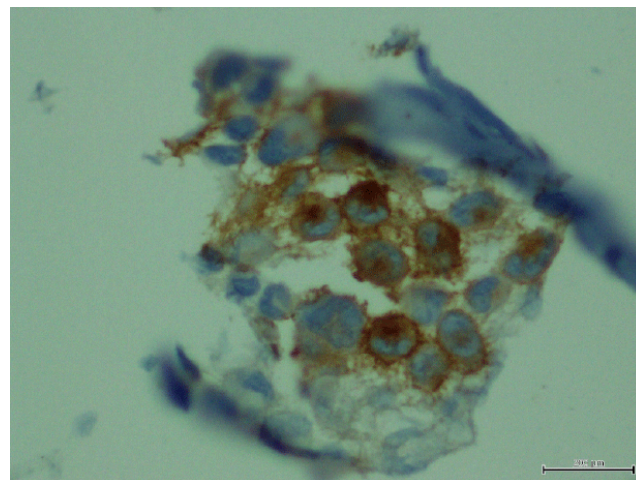


Figure 3F: CD 1a with positive and Membranous paranuclear dot

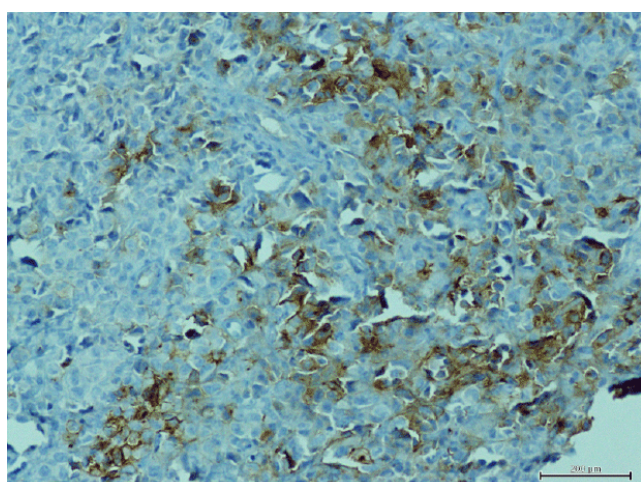


Figure 3E: CD 68 with positive and Membranous paranuclear dot

Langerhans Cell Sarcoma was first recognized by Wood and colleagues in 1984 as malignant histiocytosis X to describe a rapidly fatal cutaneous mass with massive tumor infiltration of multiple organs occurring in an elderly male patient [9]. In 1992, Tani et al. defined it as a “malignant neoplasm of Langerhans cells with the following criteria: (i) proliferation of typical Birbeck granule-containing tumor cells, and (ii) malignant cytological features such as Atypia and frequent mitotic figures” [10].

According to the WHO classification, tumors of dendritic cell lineage include follicular dendritic cell tumors, interdigitating dendritic cell tumors, langerhans cell tumors and other rare dendritic cell tumors. Langerhans cells and interdigitating dendritic cells share a common hematopoietic CD34+ precursor; in contrast, follicular dendritic cells do not have a hematopoietic origin. Langerhans cell tumors show expression of both CD1a and S-100 protein, however, interdigitating cells are positive for S-100 but negative for CD1a. By definition, indeterminate dendritic cells lack Birbeck granules on ultrastructural examination [8].

Ben-Ezra et al. reported that only 3 cases among 9 cases of LCS presented with Birbeck granules [11]. Deng et al. also described a cutaneous LCS without Birbeck granules and thought it might be an indeterminate cell sarcoma [12].

LCS needs to be differentially diagnosed from other epithelial or mesenchymal malignancy of skin, including metastatic cancer, malignant melanoma, anaplastic large cell lymphoma and myeloid sarcoma. All these diseases exhibit skin lesion and a frankly malignant cytologic appearance with highly aggressive clinical course and a poor prognosis, which may cause diagnostic confusion with LCS. Cutaneous squamous cell carcinoma or metastatic cancer shows an obvious nest structure with epithelial phenotype, such as pan-cytokeratin, CK7 or CK20. Melanoma shows S-100 protein positivity and also express other melanocytic markers, such as HMB45 and melan-A. Anaplastic large cell lymphomas are CD30+, EMA+ and may show ALK positivity. Rarely myeloid leukemia can initially present in skin, in which CD68 and lysozyme positivity will be observed and are difficult to be distinguished from LCS. The presence of myeloid specific markers, such as MPO, CD117, CD99 and CD34 is helpful in making diagnosis of myeloid leukemia first presenting in skin or cutaneous myeloid sarcoma [13].

In the present case, the tumor cells exhibited remarkably cellular atypia and higher mitotic activity with co-expression of CD1a, S-100 protein, consistent with a typical primary LCS, in spite of the absence of Birbeck granules in tumor cells.

The age of reported patients of LCS in literature range from 2 to 81 years, with a broad age distribution in adults and only 4 cases younger than 18 years of age [14-16]. The ages of the 5 cases reported in Chinese literature are 2, 18, 22, 41, 57 years (with a median age of 28 years), thus being significantly younger than that of cases reported in the English literature. LCSs show a multiple organs involvement. Most of the patients in literature have lymph node and skin involvement, although the lung, bone, mediastinum, liver, spleen and heart can also be involved [13]. 18 cases in literature involve an organ (6 cases from the skin, 6 cases from the lymph nodes, 1 case from the lungs, 1 case from the mediastinum and 4 cases from bone and bone marrow) [17,18]. The majority of the cases of LCS involve skin, lymph node, bone and bone marrow, and most cases involve only a single organ. Bohn, et al.

summarized 20 cases of LCS over 1992–2007 and found that most cases of LCS involved lymph node and skin and that only a small number of cases involved the lung, liver, spleen and bone marrow [19]. Lee et al. summarized 19 cases of LCS from 1973–2006 and concluded that most of the patients had lymph node, spleen, liver, bone marrow, thymus, lung and kidney involvement, in addition to skin [20].

The most effective treatment protocol for LCS is a combination of radiotherapy with chemotherapy. Few patients have been treated with surgery and local radiotherapy, but the results were less positive. LCS has been reported to be completely resolved after using MAID [21] or a modified ESHAP regimen (etoposide, carboplatin, cytarabine, and methylprednisolone) [22]. About 50% of patients in literature have died within 1.5 years after diagnosis and shows that LCS is a highly malignant tumor with a low survival rate and a poor prognosis [21]. From the patients with available follow-up data, 53.3% (16/30) died of their disease within 2 years despite conventional combination chemotherapy, surgery, and radiotherapy. Only 2 patients of 3 reported LCSs with only cutaneous involvement survived and were alive in complete remission [13]. A recent study has demonstrated that some cases of histiocytic sarcomas do not pursue an aggressive clinical course, particularly cases with clinically localized disease, and the tumor size appears to be an important prognostic factor [23]. Primary cutaneous LCSs without multiple organs involvement might have a somewhat smoldering stage. Once the tumor progresses, dissemination of extracutaneous sites might be presented and the patient might gain a poor prognosis with aggressive clinical course [13].

In this case, the patient received a course of chemotherapy with Anthracycline, Etoposide, Vincristine, Cyclophosphamide and Prednisolone. After 1 cycle of chemotherapy, there was significant reduction in the size of the lesions suggestive of good response to treatment (Figure 4). Her treatment was still ongoing at the time of this report being written.

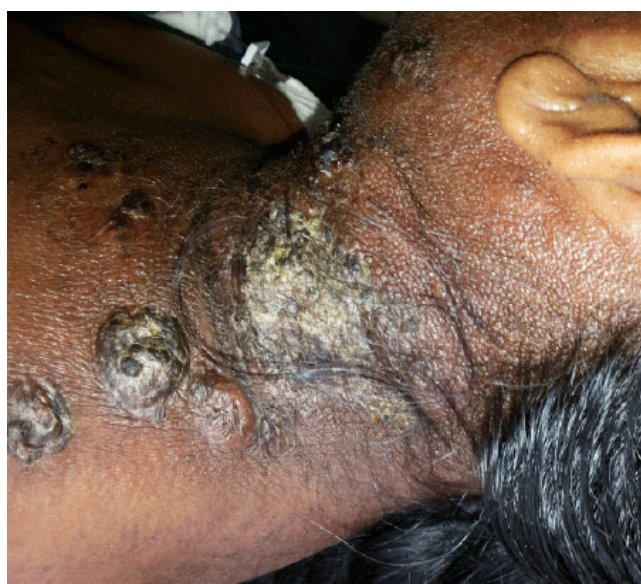

Figure 4: Post chemotherapy effects showing significant reduction in the size of the lesions

Conclusion

Langerhans Cell Sarcoma is a rare entity with varied presentation, which can be confirmed by IHC and electron microscopy only, and responds well to AnthracyclineEtoposide containing regimen. At present the standard treatment regimen is debatable.

References

1. Swerdlow SH, Campo E, Harris NL, Jaffe ES, Pileri SA, et al. (2008) WHO classification of tumors of haematopoietic and lymphoid tissues. France: International Agency for Research on Cancer.
2. Kawase T, Hamazaki M, Ogura M, Kawase Y, Murayama T, et al. (2005) CD56/NCAM-positive Langerhans cell sarcoma: a clinicopathologic study of 4 cases. *Int J Hematol* 81: 323-329.
3. Jülg BD, Weidner S, Mayr D (2006) Pulmonary manifestation of a Langerhans cell sarcoma: case report and review of the literature. *Virchows Arch* 448: 369-374.
4. Zhao G, Luo M, Wu ZY, Liu Q, Zhang B, et al. (2009) Langerhans cell sarcoma involving gallbladder and peritoneal lymph nodes: a case report. *Int J Surg Pathol* 17: 347-353.
5. Wang YN, Zhou XG, Wang Z (2013) Langerhans cell sarcoma in the cervical lymph node: a case report and literature review. *Acta Haematol* 129: 114-120.
6. Jaffe R, Weiss LM, Facchetti F (2008) Tumors derived from Langerhans cells. In WHO classification of tumors pathology and genetics of tumors of haematopoietic and lymphoid tissues. Lyon: IARC Press.
7. Tani M, Ishii N, Kumagai M, Ban M, Sasase A, et al. (1992) Malignant Langerhans cell tumour. *Br J Dermatol* 126: 398-403.
8. Weiss LM, Chan JKC, Fletcher CDM (2008) Other rare dendritic cell tumors. In WHO classification of tumors pathology and genetics of tumors of haematopoietic and lymphoid tissues. Lyon: IARC Press.
9. Wood C, Wood GS, Deneau DG, Oseroff A, Beckstead JH, et al. (1984) Malignant histiocytosis X. Report of a rapidly fatal case in an elderly man. *Cancer* 54: 347-352.
10. Tani M, Ishii N, Kumagai M, Ban M, Sasase A, et al. (1992) Malignant Langerhans cell tumour. *Br J Dermatol* 126: 398-403.
11. Ben-Ezra J, Bailey A, Azumi N, Delsol G, Stroup R, et al. (1991) Malignant histiocytosis X. A distinct clinicopathologic entity. *Cancer* 68: 1050-1060.
12. Deng A, Lee W, Pfau R, Harrington A, DiGiovanni J, et al. (2008) Primary cutaneous Langerhans cell sarcoma without Birbeck granules: indeterminate cell sarcoma? *J Cutan Pathol* 35: 849-854.
13. Li Y, Li B, Tian XY, Li Z (2013) Unusual cutaneous Langerhans cell sarcoma without extracutaneous involvement. *Diagn Pathol* 8: 20.
14. Shi-Yuan He X-LZ (2000) 2 cases of Langerhans cell sarcoma misdiagnosed. *J Guangxi Trad Chin Med University*. 17: 93-95.
15. Jing Chen J-YT, Ci PAN, et al. (2007) Langerhans cell sarcoma: the clinical features and diagnosis. *J China Pediatr Blood Cancer* 12: 213-214.
16. Lian YL, He HY, Liao SL, Yin LJ, Han ZH, et al. (2006) [Langerhans cell sarcoma of talus: report of a case]. *Zhonghua Bing Li Xue Za Zhi* 35: 697-698.
17. Langfort R, Radzikowska E, Czarnowska E, Wiatr E, Grajkowska W, et al. (2009) Langerhans cell sarcoma with pulmonary manifestation, mediastinum involvement and bronchoesophageal fistula. A rare location and difficulties in histopathological diagnosis. *Pneumonol Alergol Pol* 77: 327-334.
18. Zhao G, Luo M, Wu ZY, Liu Q, Zhang B, et al. (2009) Langerhans cell sarcoma involving gallbladder and peritoneal lymph nodes: a case report. *Int J Surg Pathol* 17: 347-353.
19. Bohn OL, Ruiz-Argüelles G, Navarro L, Saldivar J, Sanchez-Sosa S (2007) Cutaneous Langerhans cell sarcoma: a case report and review of the literature. *Int J Hematol* 85: 116-120.

-
20. Lee JS, Ko GH, Kim HC, Jang IS, Jeon KN, et al. (2006) Langerhans cell sarcoma arising from Langerhans cell histiocytosis: a case report. J Korean Med Sci 21: 577-580.
 21. Uchida K, Kobayashi S, Inukai T, Noriki S, Imamura Y, et al. (2008) Langerhans cell sarcoma emanating from the upper arm skin: successful treatment by MAID regimen. J OrthopSci 13: 89-93.
 22. Yoshimi A, Kumano K, Motokura T, Takazawa Y, Oota S, et al. (2008) ESHAP therapy effective in a patient with Langerhans cell sarcoma. Int J Hematol 87: 532-537.
 23. Hornick JL, Jaffe ES, Fletcher CD (2004) Extranodalhistiocytic sarcoma: clinicopathologic analysis of 14 cases of a rare epithelioid malignancy. Am J SurgPathol 28: 1133-1144.