

Laptop Computer Induced Erythema ab igne: A Systematic Review of Case Reports

Alsharif S*

Dermatology Residency Program, Western region, Saudi Arabia

*Corresponding author: Sahar Hasan Alsharif, PGY-2 at the Dermatology Residency Program, Saudi Arabia, Tel: 00966555539141; E-mail: s.h.alsharif@hotmail.com

Received date: November 23, 2015; Accepted date: December 24, 2015; Published date: January 02, 2016

Copyright: © 2015 Alsharif S. This is an open-access article distributed under the terms of the Creative Commons Attribution License, which permits unrestricted use, distribution, and reproduction in any medium, provided the original author and source are credited.

Abstract

Background

Erythema ab igne (EAI) is a localized skin lesion characterized by areas of reticulated erythema and hyperpigmentation. It is caused by prolonged and repeated exposure to infrared radiation.

Methods

We conducted a structured search using online databases to collect case reports and short case series on laptop computer-induced erythema ab igne. We restricted search to those studies involving case reports publication type, but we did not restrict the search by country of publication or publication dates or language.

Results

Records screened were 116, and 94 were excluded through titles and abstract evaluation. Of 22 full-text articles assessed for eligibility, 22 were included in qualitative analysis. Eventually the number of cases analyzed was 22.

There are 22 case reports of laptop induced erythema ab igne from different countries. In these reports, 13 of the 22 patients were females (62%), while 8 of the 22 patients were males (38%). The average age is 23.5 years. The majority of the cases located on the thighs. The duration of laptop exposure ranged from two weeks to two years.

Conclusion

Laptop computer induced erythema ab igne is increasing in the last years. One of the important questions in evaluation erythema ab igne a patient is about the history of prolongs laptop exposure. We recommend awareness programs development in the future to laptop users about this condition and advise them to avoid placing laptops on their body for prolonged periods of time and direct them to place laptops on a solid barrier.

Keywords: Erythema ab igne; Laptop computer

Background

Erythema ab igne (EAI) is a localized skin lesion characterized by areas of reticulated erythema and hyperpigmentation. It is caused by prolonged and repeated exposure to heat (infrared radiation). The course of the lesion started with evanescent net-like erythema or transient reticulated macular erythema, it associated with slightly increase in skin temperature. After repeated heat exposures, the reticular erythema turn out to be persist and, later, finally it become gradually hyperpigmented [1,2]. Although the pathophysiology of this condition is poorly understood, There are some theories that may explain it. One of them is chronic heat exposure can causes damage to the epidermis and superficial vascular plexus due to cutaneous hyperthermia. In vitro study has been reported that moderate heat had synergistic effect with ultraviolet radiation to denature DNA in squamous cells [3]. Another explanation is dilation and deposition of hemosiderin in a reticulate distribution of the injured superficial blood

vessels due to prolonged heat exposure [2]. Many heat sources may lead to this condition such as hot water bottles, heating blankets or heat pads, heated car seats, space heaters, or fireplaces. In the last decade, there was markedly increase in the use of the modern technology, laptop computers is one of these technology that has been implicated as the modern cause of Erythema ab igne [4]. So according to this different causes, Erythema ab igne is also termed hot water bottle rash, fire stains, laptop thigh [5,6].

The diagnosis of erythema ab igne is based on the history and clinical picture. A history will typically reveal prolonged and repeated exposure to thermal radiation at level lower than that which causes a thermal burn [1]. If the diagnosis of erythema ab igne is uncertain, we can perform a 3-mm or 4-mm punch biopsy, the histopathological findings depend on multiple parameters; the type of heat, the length of exposure, and the area of the body involved. Histologically, it is mimic solar-damaged skin, demonstrating in early lesions epidermal atrophy, then hyperkeratosis, melanin incontinence with abundant melanophages in dermis, and elastic fibre alterations [4]. Until now, there is no definitive treatment for erythema ab igne. In the

management of erythema ab igne, start with non-pharmacological approach by eradicating the heat source. On the one hand, early removing of the heat source will give good prognosis that may resolute the reticulated erythema within more than a few months. On the other hand, chronic exposure to the heat source can cause permanent hyperpigmentation and may need tretinoin, and 5-fluorouracil cream to clear epithelial atypia [7,8]. Unfortunately, there is risk of malignant transformation with chronic erythema ab igne [9].

Moreover, there are still gaps in knowledge regarding this dermatological condition, especially the more recent one, Laptop computer-induced erythema ab igne. Our aim was to systematically review case reports of laptop computer-induced erythema ab igne, in order to outline the main features of it and increase the knowledge about this new skin condition.

Methods

We reviewed all cases of laptop computer-induced erythema ab igne from the first published case in 2004 to December 2013 using the online databases of PubMed, MEDLINE, Trip database, and Google Scholar. We limited our search only to those studies involving case

reports publication type, but we did not restrict the search by country of publication or publication dates or language.

The electronic search strategy was as follows: (laptop[All Fields] AND ("computers"[MeSH Terms] OR "computers"[All Fields] OR "computer"[All Fields])) AND induced[All Fields] AND (("erythema"[MeSH Terms] OR "erythema"[All Fields]) AND ("abnormalities"[Subheading] OR "abnormalities"[All Fields] OR "ab"[All Fields]) AND igne[All Fields]) AND ("case reports"[Publication Type] OR "case report"[All Fields])

We screened the titles and the abstracts of the articles that found during the search and excluded any that were considered irrelevant or not a case report. We also checked the references of all obtained literature and all included papers to identify any further possibly related studies.

Result

The table below illustrates some of the main characteristics of the all case reports that we were reviewed:

References	Description of the lesion	Location of the lesion	Daily use of laptop	Duration of exposure	Nationality	Gender	Age	Year of publication	Case
10	well-defined, brown, mildly erythematous, reticulated patch	The left anterior thigh	considerable amount of time each day	2 weeks	Not reported	Male	50	2004	1
11	patchy reticulate pigmentation	The right thigh more than the left.	Not reported	Not reported	Dutch	Female	48	2004	2
12	patchy reticulated mildly erythematous to brownish lesions, non blanchable	The front of the thighs, more pronounced on the left thigh	6-8 hours	1 year	French	Female	17	2006	3
13	patch of reticulated hyperpigmentation	right thigh	6 hours	Not reported	Indian-American	Female	26	2007	4
14	reddish-brown, reticulated eruption	The thighs	Not reported	Not reported	American	Female	40	2007	5
15	reticular and macular, brown pigmentation, fixed, nonmigrating, and not blanchable.	The anterior aspect of the right thigh, more discrete on the left thigh	several hours every day	Not reported	French	Male	26	2009	6
16	asymmetrical, discrete erythematous lesions initially, having evolved into a fixed pigmentation, painless, non-itchy.	The front two legs, predominantly on the left thigh	6 hours	6 months	French	Female	25	2009	7

17	reticulated, dark reddish brown pigmented patch with an undefined border	The left thigh	Not reported	3 months	Turkish	Male	21	2009	8
18	a livedo reticularis-like eruption	both thighs, but more pronounced on the left.	daily	Several months	American	Male	15	2010	9
19	brown, reticular, nonblanchable cutis marmorata with burning and itching	the left anterior thigh	Not reported	1 year	Italian	Female	17	2010	10
20	Reticular hyperpigmentation	The left thigh	Not reported	Not reported	Swedish	Male	9	2010	11
21	well defined, brownish-pigmented, reticulate, livedolike lesion, mildly erythematous with telangiectasias	left upper thigh only	several hours per day	Not reported	Swiss	Male	12	2010	12
22	pigmentation in a net-like distribution	The front of the thighs	daily	longstanding	Canadian	Female	20	2010	13
23	20-cm brownish macules with mild erythema along the edges. The lesion was affecting both thighs, but was more visible on the dorsal surface of the right thigh	the anterior surface of the both thighs, but more visible on the dorsal surface of the right thigh	several hours	11 months	Brazilian	Female	12	2011	14
24	8*6-cm area of reticulated, brownish, macular pigmentation on a background of faint dusky erythema	The left breast, mainly over the upper medial quadrant	frequently	Not reported	Not reported	Female	18	2011	15
25	reticulated, erythematous to dull brown pattern	The anterolateral aspect of the thighs	Not reported	9 months	Canadian	Female	24	2011	16
26	diffuse reticular brownish hyperpigmentation	one side of the abdomen	2 to 3 hours	2 years	Indian	Male	20	2012	17
27	patch diffusely hyperpigmented, reticulate, and morbilliform violaceous-brown with minimal scaliness, warm to touch.	Mid of the left thigh and progressed upwards toward the groin.	on a daily basis	Not reported	Canadian	Male	16	2012	18

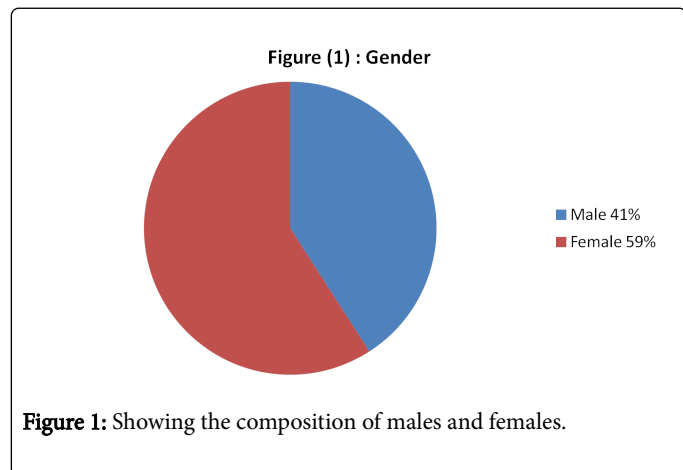
28	reticulated hyperpigmented macule with poorly defined borders	The anterior aspect of the left thigh	several hours a day	Not reported	Spanish	Female	20	2012	19
28	hyperpigmented macule with ill-defined borders	The anterior aspect of the left thigh	Not reported	Not reported	Spanish	Male	24	2012	20
2	net-like Hyperpigmented, reticulated lesions	lower legs more pronounced on the left	Not reported	2 years	Not reported	Female	21	2012	21
29	reticulated, reddish-brown macules with an ill-defined border	the anterior aspect of both thighs	1 hour	18 months	German	Female	36	2013	22

Discussion

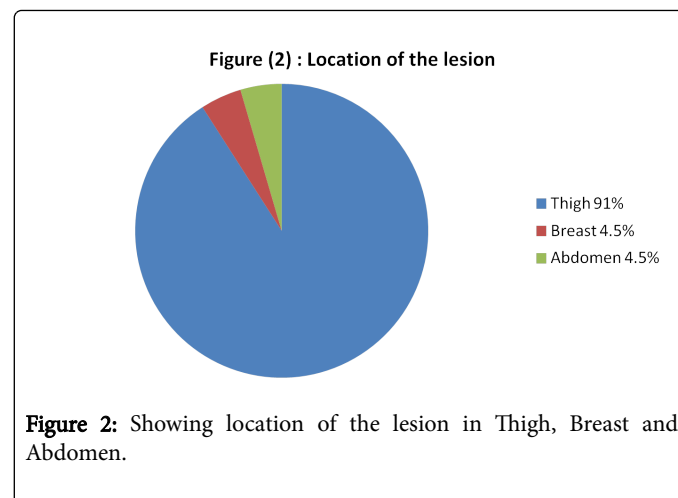
Erythema ab igne (EAI) is a reticular erythematous pigmented dermatosis consequential from repeated exposures to infrared radiation or reasonable heat in the range of 43-47°C; it is usually insufficient to bring into being a burn [2]. It can arise at any site of the skin of the body depending on the heat or radiation source, usually it occur in an asymmetrical distribution corresponds to the different sources of heat that are currently in use [4].

Previously, EAI was first started as an occupational disease in the shins who work nearly to heat source such as open fires or coal stoves. Recently, the typical EAI has been declined in this group of populations due to use of central heating [29]. In the other hand, it has been notice in the individuals who appliance of heating pads on the back or the abdomen to decrease the chronic pain [5]. In the more recent, with increase the modern technology, the rising incidence of the use of electronic devices which can generate thermal radiation that may cause Erythema ab igne [15].

In our review of the literature, there are 22 case reports of laptop induced erythema ab igne from different countries; Netherland, France, India, America, Turkey, Italy, Sweden, Switzerland, Canada, Brazil, Spain, and Germany [2,10-29]. In these reports, 13 of the 22 patients were females (62%), while 8 of the 22 patients were males (38%) (Figure 1).



The average age is 23.5 years when the condition was discovered. The site of the erythema ab igne lesion is corresponding to the area of contact with the laptop's heating element. The majority of the laptop induced erythema ab igne cases located on the thighs (20 of 22 cases, 91%). (Figure2) Over half of those cases reported that the lesion is predominantly on the left thigh (13 of 22 cases, 65% on the left thigh, while 4 of 22 cases, 15% on the right thigh, and 3 of 22 cases, 20% on the both thighs).



(Figure3) There is only one report of laptop induced erythema ab igne located in left breast for 18-year-old girl who was use of her laptop computer while reclining [24]. There is another one report of laptop induced erythema ab igne located in left side of the abdomen for a 20-year-old male engineering student who had the habit of placing the laptop computer on the bare skin of his abdomen [26].

Figure (3) : Location of the lesion predominantly on the thighs

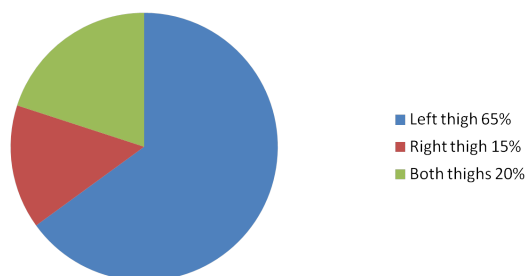


Figure 3: Showing the Location of the lesion predominantly on the thighs.

Almost all of the laptop induced erythema ab igne cases were asymptomatic macular, erythematous and hyperpigmented, reticulated lesion except one case that was associated with burning and itching [19]. The duration of laptop exposure ranged from two weeks to two years (Figure 4).

Figure (4) : Duration of laptop exposure

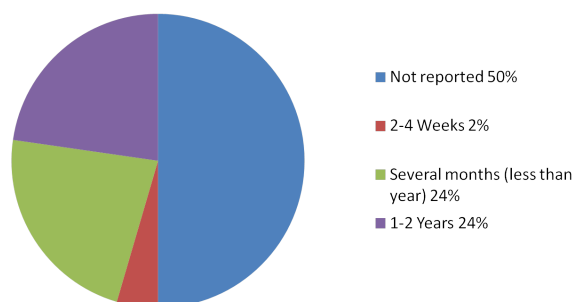


Figure 4: Showing duration of the laptop exposure.

Biopsy was not frequently performed. In fact, in case of laptop computer induced erythema ab igne the diagnosis is easily made by history and direct examination [1]. Biopsy would be most useful in chronic erythema ab igne, while in patients who are in risk of malignant transformation [9].

Figure (5) : Year of publication

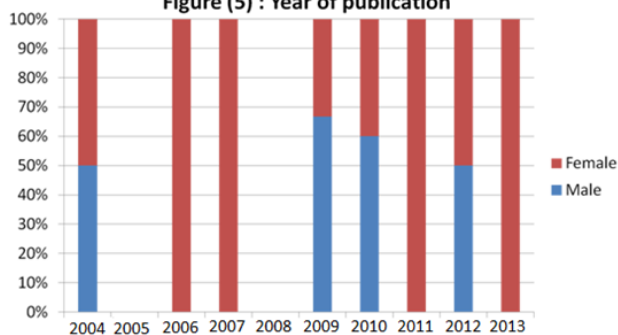


Figure 5: Showing the year of publication.

Limitations

Limits in our results are due to incomplete information in the cases about the exact duration of laptop exposure and the duration and frequency of the daily use of laptop. Actually, 50% of the reports did not mention the exact duration of laptop exposure. (Figure 4) Moreover, publication bias is a potential problem in systematically reviewing case reports. Lack of publications about the laptop computer induced erythema ab igne during two years; 2005 and 2008, hence it is not possible to rule out present of this condition during this period. (Figure 5) Unfortunately it was not possible to extract from the case reports the type of the laptops.

Conclusion

Erythema ab igne is a localized reticulated erythema and hyperpigmentation lesion by prolonged and repeated exposure to heat. Laptop computer induced erythema ab igne is increasing in the last years. One of the important questions in evaluation erythema ab igne patients are about the history of prolonged laptop exposure. We recommend awareness programs development in the future to laptop users about this condition and advise them to avoid placing laptops on their body for prolonged periods of time and direct them to place laptops on a solid barrier.

References

- Dvoretzky I, Silverman NR (1991) Reticular erythema of the lower back. Erythema ab igne. See comment in PubMed Commons below Arch Dermatol 127: 405-409.
- R R Riahi, P R Cohen (2012) "Laptop-induced erythema ab igne: Report and review of literature.," Dermatology online journal 18: 5.
- D. Roth, M London (1977) "ACRIDINE PROBE STUDY INTO SYNERGISTIC DNA-DENATURING ACTION OF HEAT AND ULTRAVIOLET LIGHT IN SQUAMOUS CELLS." Journal of Investigative Dermatology 69: 368-372.
- Tan S, Bertucci V (2000) Erythema ab igne: an old condition new again. See comment in PubMed Commons below CMAJ 162: 77-78.
- CM Rudolph, H P Soyer, P Wolf, H Kerl (1998) "Hot-water-bottle rash: not only a sign of chronic pancreatitis," Lancet 351: 677.
- Rapini, Ronald P, Bologna, Jean L, Jorizzo et al. (2007) Dermatology: 2-Volume Set. St. Louis: Mosby : 87.
- J J Meffert and B M Davis (1996) "Furniture-induced erythema ab igne" Journal of the American Academy of Dermatology 34: 516-517.
- Riahi RR, Cohen PR, Robinson FW, Gray JM (2010) Erythema ab igne mimicking livedo reticularis. Int J Dermatol 49: 1314-1317.
- Sahl WJ Jr1, Taira JW (1992) Erythema ab igne: treatment with 5-fluorouracil cream. J Am Acad Dermatol 27: 109-110.
- Bilic M, Adams BB (2004) Erythema ab igne induced by a laptop computer. J Am Acad Dermatol 50: 973-974.
- Jagtman BA (2004) Erythema ab igne due to a laptop computer. Contact Dermatitis 50: 105.
- Maalouf E, Simantov A, Rosenbaum F, Chosidow O (2006) Erythema ab igne as an unexpected computer side-effect. Dermatology 212: 392-393.
- M. R. Mohr, K. A. Scott, R. M. Pariser,, A. F. Hood (2007) "Laptop computer-induced erythema ab igne: a case report.," Cutis; cutaneous medicine for the practitioner 79: 59-60.

14. W. S. Levinbook, J. Mallett, J. M. Grant-Kels (2007) "Laptop computer--associated erythema ab igne," *Cutis; cutaneous medicine for the practitioner* 80: 319-320.
15. Bachmeyer C, Bensaid P, Bégon E (2009) Laptop computer as a modern cause of erythema ab igne. *J Eur Acad Dermatol Venereol* 23: 736-737.
16. Fite C, Bouscarat F (2009) [Laptop computer-induced erythema Ab Igne]. *Presse Med* 38: 1164-1165.
17. KÄ¼Å§Ä¼ktaÄ M, Demirkesen C, Aslan C, Aydemir EH (2010) Laptop-induced erythema ab igne. *Clin Exp Dermatol* 35: 449-450.
18. Andersen F1 (2010) [Laptop-thighs--laptop-induced erythema ab igne]. *Ugeskr Laeger* 172: 635.
19. Søholm Secher LL, Vind-Kezunovic D, Zachariae CO (2010) Side-effects to the use of laptop computers: erythema ab igne. *Dermatol Reports* 2: e11.
20. M. Karlsson, Y W Linde (2010) "[Erythema ab igne--classical dermatological diagnosis hot again. Laptop computer dermatitis most common in young people]." *Läkartidningen*, 107: 32-33.
21. Arnold AW, Itin PH (2010) Laptop computer-induced erythema ab igne in a child and review of the literature. *Pediatrics* 126: e1227-1230.
22. D Botten, RGB Langley, A Webb (2010) "Academic branding: erythema ab igne and use of laptop computers." *CMAJ*?: Canadian Medical Association journal = journal de l'Association medicale canadienne 182: E857.
23. S Giraldi, F Diettrich, K T Abbage, V de O.Carvalho, LP Marinoni (2011) "Erythema Ab Igne induced by a laptop computer in an adolescent." *Anais brasileiros de dermatologia* 86: 128-130.
24. Boffa MJ (2011) Laptop computer-induced erythema ab igne on the left breast. *Cutis* 87: 175-176.
25. Li K, Barankin B (2011) Cutaneous manifestations of modern technology use. *J Cutan Med Surg* 15: 347-353.
26. Nayak SU, Shenoi SD, Prabhu S (2012) Laptop induced erythema ab igne. *Indian J Dermatol* 57: 131-132.
27. Fu LW, Vender R (2012) Erythema ab igne caused by laptop computer gaming--a case report. *Int J Dermatol* 51: 716-717.
28. T Fernández-Portilla, B Escutia-Muñoz, M Navarro-Mira, C. Pujol-Marco () "[Erythema ab igne caused by laptop computer use]." *Actas dermo-sifiliográficas* 103: 559-560.
29. Gauglitz GG, Ruzicka T, Herzinger T (2013) Erythema a computatro. *Case Rep Dermatol* 5: 111-113.