

## Large Extra-pleural Hematoma: A Rare Delayed Presentation after Blunt Thoracic Trauma

Annu B, Vishal K, Sushma S, Subodh K and Amit G\*

Department of Trauma Surgery and Critical Care, JPN Apex Trauma Centre, All India Institute of Medical Sciences, New Delhi, India

### Abstract

Blunt thoracic trauma is among the major causes of mortality in setting of acute trauma. Early mortality in chest trauma is often preventable; however, chest trauma can lead to delayed complications. Extra pleural hematoma is among one of them. Owing to the scarcity of literature present on the extra pleural hematoma and its management after blunt thoracic trauma, we, hereby, report a case of 50 year old man who sustained bilateral multiple rib fractures with no hemothorax after blunt thoracic trauma. Patient developed large radio-opaque shadow in right hemithorax four days after injury which later was diagnosed as extra pleural hematoma and was successfully managed with limited thoracotomy.

**Keywords:** Extrapleural hematoma; Thoracic trauma; Limited thoracotomy

### Introduction

Thoracic trauma accounts for 25-50% of all traumatic injuries, with a high mortality in all age groups [1]. Blunt trauma of the chest following motor vehicle collision is among the major cause. Early mortality (within the first 30 minutes to 3 hours) in thoracic trauma is often preventable. Since conditions like tension pneumothorax, cardiac tamponade, airway obstruction, and uncontrolled haemorrhage are often manageable and patient can be stabilised temporarily, it is indispensable for an emergency physicians to be acquainted with their pathophysiology, clinical presentation, diagnosis, and treatment [2]. Approximately 85% of all thoracic trauma can be managed by supplemental oxygen, tube thoracostomy, chest physiotherapy and pain control [3].

Blunt thoracic trauma can lead to fracture of the bony skeleton like ribs, clavicles, scapulae, sternum and many other injuries to lungs parenchyma, pleurae, tracheobronchial tree, esophagus, heart, great vessels of the chest, and to the diaphragm. Major pulmonary and bronchial complications includes atelectasis, pneumonia, pulmonary abscess, empyema, pneumatocele, lung cyst, clotted haemothorax, fibrothorax, broncho-pleural fistula and bronchial repair disruption [4]. Most of primary injuries can be definitely diagnosed by a chest radiograph and CECT of chest. Rarely, chest trauma may result in a collection of blood between the parietal pleura and the endothoracic fascia, termed extrapleural hematoma [2]. A large extrapleural hematoma appears as opacity of the affected hemithorax on the chest X-ray mimicking a hemothorax. We report a case of 50 year old man who sustained bilateral multiple rib fractures with no hemothorax after blunt thoracic trauma. Patient developed large radio-opaque shadow in right hemithorax four days after injury which later was diagnosed as extra pleural hematoma and was successfully managed with limited thoracotomy.

### Case Report

A 50-year-old man presented with blunt thoracic trauma to our emergency department, He was a bicyclist hit by a four wheeled light motor vehicle. On initial evaluation, the airway was patent but the patient had decreased breath sounds on the left side of chest. Chest Compression Test (tenderness and crepitus on palpation) was positive on both sides. Subcutaneous emphysema was present on the left side of chest. There were abrasions present over left anterolateral chest wall.

The chest radiograph revealed 2<sup>nd</sup> to 6<sup>th</sup> rib fracture with pneumothorax and subcutaneous emphysema over left side of chest and fracture of 1<sup>st</sup> to 3<sup>rd</sup> ribs on the right side without any evidence of haemothorax or pneumothorax (Figure 1).

A Tube thoracostomy was done immediately on left side to relieve the pneumothorax. The patient was managed non-operatively under vigilant monitoring. A follow up Chest X-Ray on day 4 after injury revealed a radio-opaque shadow involving the upper 2/3<sup>rd</sup> of the right hemi-thorax (Figure 2). Left side of chest was within normal limits.

The right costo-phrenic angle was clear thereby making the possibility of pleural effusion/ haemothorax less likely. A Contrast Enhanced CT of chest was done and it showed organised extra-pleural hematoma with no radiological signs suggestive of active bleeding (Figure 3).

Patient was stable with no cardiorespiratory compromise; although his haematological parameters did show a fall in haemoglobin level from 14 gm/dl to 10 gm/dl, all other blood parameters including platelet count (2.2 lac/cubic mm), INR (1.10), kidney function test and liver function test were within normal limits. He was maintaining saturation (SpO<sub>2</sub>) of 100% on room air. In view of an organised extra-pleural hematoma, patient was planned for limited thoracotomy for drainage of this hematoma. Intra-operatively patient was found to have large extra pleural haematoma of about 2 litres. The haematoma was evacuated (Figure 4) and a 36 Fr chest tube was placed in situ. Patient recovered satisfactorily in post-operative period. The right lung field became clear on 5<sup>th</sup> postoperative day and patient was discharged on 10<sup>th</sup> postoperative day (Figure 5).

### Discussion

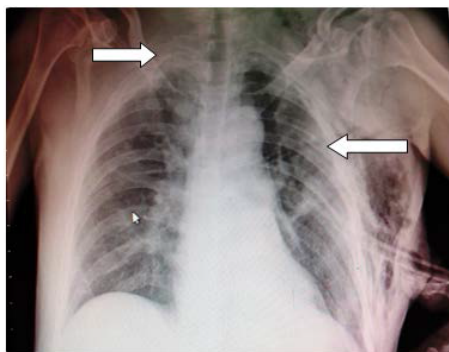
According to the mechanism chest injuries can be either blunt or penetrating. Blunt and penetrating injuries have

\*Corresponding author: Amit G, Department of Trauma Surgery and Critical Care, JPN Apex Trauma Centre, All India Institute of Medical Sciences, New Delhi, India, E-mail: amitguptaaiims@gmail.com

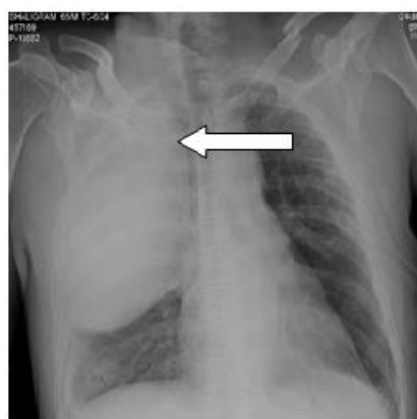
Received February 23, 2015; Accepted March 30, 2015; Published April 01, 2015

**Citation:** Annu B, Vishal K, Sushma S, Subodh K, Amit G (2015) Large Extrapleural Hematoma: A Rare Delayed Presentation after Blunt Thoracic Trauma. J Trauma Treat 4: 241. doi:10.4172/2167-1222.1000241

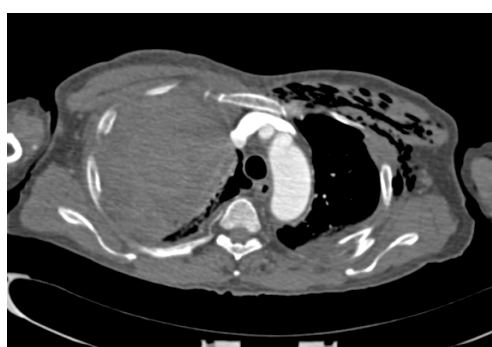
**Copyright:** © 2015 Annu B, et al. This is an open-access article distributed under the terms of the Creative Commons Attribution License, which permits unrestricted use, distribution, and reproduction in any medium, provided the original author and source are credited.



**Figure 1:** Chest radiograph on admission: shows fracture of the left 2nd 3rd 4th 5th and 6th ribs with left subcutaneous emphysema; and fracture of 1st 2nd and 3rd ribs on right side (arrow).



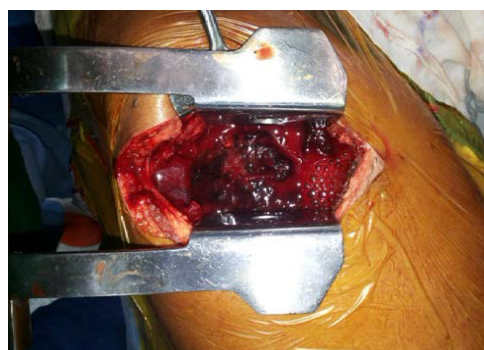
**Figure 2:** Chest x-ray done 4 days after injury showing large radio-opaque shadow in upper 2/3<sup>rd</sup> of the right hemi-thorax but right costophrenic angle is free.



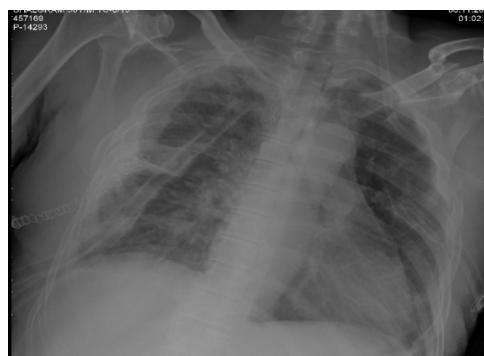
**Figure 3:** Preoperative CECT chest showing organised extra-pleural hematoma on right side.

different physiological impacts, clinical courses and outcomes. Blunt thoracic trauma mainly occurs as a result of one or more of the three mechanisms, i.e. direct transfer of energy following a direct impact to the thoracic wall; rapid deceleration, or compression of the mediastinum between the sternum and the spine [5]. Severity of injury depends on the amount of energy transferred to chest wall which in turn depends upon speed and mass of objects. Extra pleural hematomas due to blunt thoracic trauma are sparsely reported. The incidence might be underestimated due to lack of knowledge among

the trauma surgeons. Rashid et al reported the incidence of traumatic extra pleural hematoma as 7.1% [6]. In blunt trauma, rib fractures can result in injury to the vasculature of the chest wall, especially the intercostal vessels. If the parietal pleura is not torn or the tear is relatively small, blood accumulates in the extra-pleural space causing an extra-pleural hematoma [7]. The typical radiographic feature of an extra-pleural hematoma is a D-shaped opacity with its base located against the corresponding part of the chest wall [6]. However, this typical D-shaped outline may not be delineated in a huge extrapleural hematoma which tends to appear as a near complete opacity of the hemithorax mimicking a hemothorax. As seen in our patient, the massive radio-opacity in the right hemithorax was initially diagnosed as traumatic haemothorax. Although, it is difficult to differentiate a huge extrapleural hematoma from a haemothorax but several clinical and radiographic findings can help to make the diagnosis. A trauma patient with opacity of the hemithorax on a chest radiograph with unsuccessful drainage of the collection after insertion of a chest tube may suggest an extrapleural hematoma or a clotted hemothorax. However, unlike a hemothorax, the pleural reflection may be identified at the lower margin and the costophrenic angle is not obliterated in an extrapleural hematoma (Figure 2) [2,7,8]. Though, most reported cases of extrapleural hematoma could be diagnosed only using the chest radiograph, a contrast enhanced CT is useful tool to determine the location and nature of the extrapleural collections and aid preoperative diagnosis [8]. Treatment of extrapleural hematomas closely depends on the clinical condition of patient. Treatment options include non-operative management, tube thoracostomy, VATS, surgical evacuation and or along with angio-embolisation of bleeding vessels [9]. A stable patient and a small hematoma can be managed without any intervention. Aspiration and tube thoracostomy drainage might



**Figure 4:** Intraoperative picture: limited thoracotomy for drainage of extrapleural hematoma.



**Figure 5:** Postoperative chest x ray showing clear lung fields bilaterally.

prove unsatisfactory when hematoma is clotted [10]. Evacuation of blood clots may be required in a large extrapleural hematoma because respiratory and circulatory compromise might occur [11]. In some patients VATS has been shown to be effective in exploring the pleural space and evacuating the hematoma [12]. Due to poor visualization and prolonged surgical time, Rashid et al suggested video-assisted thoracic surgery was not suited to approach the extra-pleural hematoma, and that a limited thoracotomy was mostly needed [13]. Authors are of the opinion that contrast CT of chest is a good modality to diagnose extrapleural hematoma and a limited thoracotomy is better modality as compared to VATS for evacuation of such hematoma particularly considering its delayed presentation and organised nature.

## Conclusion

Extra pleural hematoma is of rare occurrence after blunt thoracic trauma and its delayed presentation should be kept in mind. The chest radiograph is generally sufficient for diagnosis, however, contrast enhanced CT scan of chest leads to better characterisation of hematoma. Limited thoracotomy for drainage of the haematoma is a safe and reliable surgical option.

## References

1. Francisco C, André LB, Rodrigo FE, Paulo CE, José MPDG (2009) Rates of thoracic trauma and mortality due to accidents in Brazil. *Ann Thorac Med* 4: 25-26.
2. Hii CH, Huong SS, Lo SE, Chiang YH, Tan CK (2008) Extrapleural haematoma: a diagnostic pitfall in blunt chest trauma. *Resuscitation* 79: 348-349.
3. Douglas B, Kenneth B (2002) Pattern of injury in motor vehicle accidents world wide wound.
4. Mary CM, John G (2014) Blunt Chest Trauma. *Med scape*
5. James V (2004) Trauma nursing: Blunt chest injuries. *RN* 67: 47-54
6. Rashid MA, Wikstrom T, Ortenwall P (2000) Nomenclature, classification, and significance of traumatic extrapleural hematoma. *J Trauma* 49: 286-290.
7. Goh BK, Koong HN (2006) Massive traumatic extrapleural hematoma mimicking hemothorax: a potential pitfall of penetrating chest trauma. *J Trauma* 61: 995-997.
8. Jeong JY, Lee J (2012) Huge extrapleural hematoma by blunt trauma mimicking traumatic hemothorax. *J Trauma Acute Care Surg* 72: 118.
9. Hagiwara A, Iwamoto S (2009) Usefulness of transcatheter arterial embolization for intercostal arterial bleeding in a patient with burst fractures of the thoracic vertebrae. *Emerg Radiol* 16: 489-491.
10. Petros M, Konstantinos P, Ioannis G, Sotiria S (2007) Huge Extrapleural Hematoma After a Blunt Chest Trauma: An Unusual Presentation. *European Journal of Trauma and Emergency Surgery* 33: 651-653.
11. Poyraz AS, Kilic D, Gultekin B, Ozulku M, Hatipoglu A (2005) Extrapleural hematoma: when is surgery indicated?. *Monaldi Arch Chest Dis* 63: 166-169.
12. Yueh-Feng T, Chih-Cheng L Huge (2013) Extrapleural Hematoma Initially Diagnosed as Massive Hemothorax. *J Med Cases* 4: 247-249.
13. Rashid MA (1999) Value of video-assisted thoracic surgery in traumatic extrapleural hematoma. *Thorac Cardiovasc Surg* 47: 255-257.