

Large Tear of the Pectoralis Major Muscle in an Athlete. Results after Treatment with Intratissue Percutaneous Electrolysis (EPI®)

Abat F^{1*}, Gelber PE^{2,3}, Monllau JC^{2,4} and Sánchez-Ibáñez JM⁵

¹Department of Sports Orthopedics, Cerede Sports Medicine, Barcelona, Spain

²Department of Orthopedics, ICATME – Institut Universitari Quiron Dexeus, University Autònoma of Barcelona. Barcelona, Spain

³Department of Orthopedic Surgery, Hospital de la Santa Creu i Sant Pau, University Autònoma of Barcelona, Barcelona, Spain

⁴Department of Orthopedics and Traumatology, Parc de Salut Mar, University Autònoma of Barcelona, Barcelona, Spain

⁵Department of Sports Rehabilitation, Cerede Sports Medicine, Barcelona, Spain

*Corresponding author: Abat Ferran, Department of Sports Orthopedics, Cerede Sports Medicine.c/ Dr. Roux 8-10. 08017, Barcelona, Spain, Tel: +34934523510; E-mail: drabat@cerede.es

Copyright: © 2014 Abat F, et al. This is an open-access article distributed under the terms of the Creative Commons Attribution License, which permits unrestricted use, distribution, and reproduction in any medium, provided the original author and source are credited.

Received date: April 09, 2014; **Accepted date:** May 25, 2014; **Published date:** May 31, 2014

Abstract

Background: Injuries to the pectoralis major muscle can result in functional limitation. Previous reports on conservative treatment on large tears of the pectoralis major muscle showed inconsistent results with several treatment modalities. The best option to treat this pathology is still under discussion.

Methods: A 30 year-old male patient with a large pectoralis major muscle tear was treated with ultrasound-guided EPI® technique once a week and eccentric exercise. Echography study was performed during the follow-up. Functional evaluation was assessed with Tegner scale, the criteria described by Bak et al. and the subjective outcomes described by Anthony et al.

Results: Ultrasound scan showed a correct arrangement of muscle fibers. Functional evaluation showed excellent results and at four weeks of treatment, the patient had returned to their level of activity prior to the injury.

Conclusion: Treatment with the US-guided EPI® technique on pectoralis major muscle tear resulted in a high improvement in function and a rapid return to the previous level of activity after few sessions. The procedure has proven to be safe with no recurrences at one-year follow-up.

Keywords: Pectoralis major; Muscle; Tear; Athlete; Treatment; Intratissue percutaneous electrolysis; EPI

Introduction

Injuries to the pectoralis major muscle are important because as they can result in functional and aesthetic deficiencies of the upper extremity. They typically arise through indirect means, with the muscle being in a state of maximum elongation and contraction at a point of sudden overload [1-3]. This type of injury has been observed in activities like weight lifting, wrestling, American football and water skiing [4,5].

A purely clinical assessment of the pectoralis major injury may be deficient, so additional tests with imaging are needed to refine the diagnosis. Magnetic resonance imaging has been successfully used to assess the characteristics of injuries to the pectoralis major [6]. Similarly, ultrasound has been used to determine the extent and location of the lesion [7,8]. However, diagnosing with imaging is not without problems due to the anatomical complexity of the distal tendon of the pectoralis major as this has a 180° twist that comprises the sternal and clavicular portions [7,8]. The anatomical location of the muscle tear is very important because an avulsion of the tendon at its insertion into the humerus requires surgical repair, while

myotendinous junction lesions are usually treated with conservative treatment [2,5,9].

Among the conservative treatment options, Intratissue percutaneous electrolysis (EPI®) stands out. This is a minimally invasive medical and physiotherapeutic technique that involves the application of a high-intensity galvanic current through a conductive stylus that provokes a rapid and localized regenerative process in the target tissue [10,11]. This allows for phagocytosis and the subsequent repair of affected tissue while making it possible to aspirate the hematic content of the injury and reducing the production of a secondary fibrotic lesion [12]. This is vitally important because it decreases the fibrous scar that occurs in muscle injuries and therefore the risk of re-rupture.

With this paper, the aim is to present the clinical and functional results in the treatment of an athlete affected by a large partial tear of the pectoralis major muscle treated with the EPI® technique.

Materials and Methods

A 30 year-old male patient who came to our clinic with pain and a functional limitation in the upper left extremity. The pain appeared suddenly during his usual gymnastic practice when performing a pull-up on the horizontal bar. The patient had no relevant medical history

or concomitant therapies and had never received injections to the affected area.

Clinical examination showed a clear indentation in the musculature of the left pectoralis major that became more pronounced when the patient pressed their palms together to contract the large pectoral muscles bilaterally. An obvious indentation was seen on the left upon comparing it to the right pectoral, which indicated a major tear of the muscle.

Ultrasound evaluation of the pectoralis major was performed longitudinally and transversally to the muscle fibers and the tendons were evaluated from origin to insertion. The distal pectoral tendon was identified and evaluated on the transverse plane at the level of the bicipital groove of the humerus, where the pectoral tendon and the tendon of the long head of biceps brachii cross. Equally, an evaluation of the flow was performed with high-resolution color Doppler. The images were compared to the contralateral side, placing the patient's shoulder in abduction and external rotation for the examination.

The ultrasound study was performed by two specialists in musculoskeletal ultrasound using a color Doppler device and lineal probe of 5-16 Mhz and longitudinal and transverse views. At the same time, a radiographic study of the shoulder was performed with AP projection, an axillary "Y" view as well as in internal and external rotation.

The functional assessment was performed according to the criteria described by Bak et al. [13] in which results for patients without symptoms with normal range mobility without cosmetic changes, without adduction weakness and able to return to their sport activity were considered as excellent. Those results with almost normal range of mobility without cosmetic changes and less than a 20% deficit in peak torque in the isokinetic test were considered good. The poor results are those in which there is limited range of mobility, poor cosmetic results and the patient is unable to return to their sport activity. Finally, those results where the pain persists and revision surgery is needed were considered bad.

As a second item in the functional assessment, the test for assessing subjective outcomes described by Schepesis et al. [14] was used for the evaluation of lesions of the pectoralis major. Patient follow-up was conducted over a year while getting clinical and functional results before treatment, at one month as well as 2, 6 and 12 months. The Tegner scale was used to rate the level of activity of patients before and after the injury.

Treatment was consisted of the application of the ultrasound-guided EPI® technique once a week and eccentric exercise twice a week. The EPI® technique was performed with the patient supine using the device designed specifically to carry out this technique, the EPI Medical Tissue Remover® (EPI Advanced Medicine, Barcelona, Spain).

A 40 mm-long sterile 20G needles were used. The application was performed by means of stratified ultrasound-guided puncturing. In the first treatment session, a puncture was performed in the center of the hematic injury to do the first EPI® pulse of 5 seconds duration (Figure 1a), activating then the vacuum system (Figure 1b) of the device itself so as to get quick closure of the muscle injury.

Once the closure of the lesion was successful (Figure 1c), EPI® was continued at the edges of the lesion without removing the needle and applying 4 pulses of 10 seconds each in the geographical margins of the lesion. In 3 subsequent weekly sessions, 0.3 × 30 mm needles were

used to apply the EPI® technique to minimize the pain of the puncture, using 4 pulses of 10 seconds in the length of remnant muscle scar.

Results

According to the classification of Tietjen [15], it was a pectoralis major muscle injury type II at the mid-portion of the muscle. Ultrasound examination detected a marked accumulation of fluid (hypoechoic) in the pectoralis major muscle (Figure 1). The diameter of the lesion was 30 × 7 millimeters with plenty of hematic content. The radiographic studies showed no abnormalities or bony avulsions.

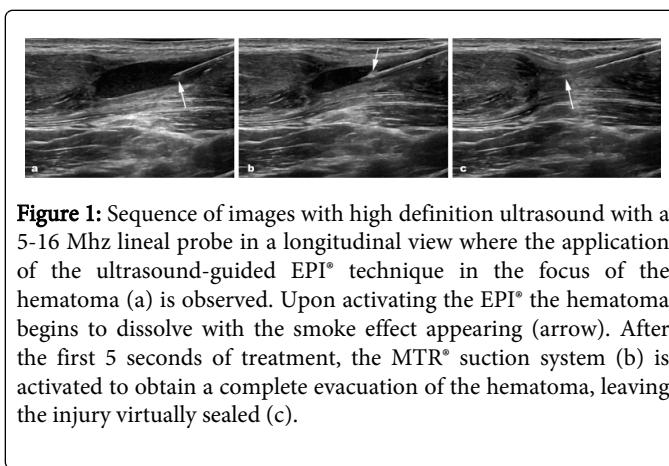


Figure 1: Sequence of images with high definition ultrasound with a 5-16 Mhz lineal probe in a longitudinal view where the application of the ultrasound-guided EPI® technique in the focus of the hematoma (a) is observed. Upon activating the EPI® the hematoma begins to dissolve with the smoke effect appearing (arrow). After the first 5 seconds of treatment, the MTR® suction system (b) is activated to obtain a complete evacuation of the hematoma, leaving the injury virtually sealed (c).

In the functional evaluation, according to the criteria of Bak et al. [13], the good results that were seen at one month passed to excellent at 2 months and remained at the same level at 12 months.

The results obtained according to the criteria of Schepesis et al. [14] are shown in Table 1. Four weeks after the treatment starts, the patient had returned to their level of activity prior to the injury that was 8 points on the Tegner scale. These results were maintained in controls at 2, 6 and 12 months.

Question	1 month FU	2 months FU	6 months FU	1 year FU
Pain Relief	98	98	98	98
Range of Motion	95	100	100	100
Return to strength	96	97	100	100
Cosmetic satisfaction	86	86	95	95
Treatment Satisfaction	98	100	100	100

Average answers from the subjective questionnaire described for Schepesis et al. Values presented as percentages based on 100%.

Table 1: Results obtained according to the criteria of Schepesis et al. [14] during the follow-up

The ultrasound scan performed during follow-up showed a correct arrangement of muscle fibers without evidence of fibrous scarring or accumulations of hematic residuals (Figure 2). During the procedure, no medical complications related to treatment presented.

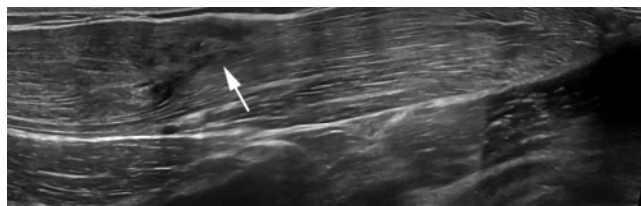


Figure 2: Ultrasound control with a 5-16 Mhz lineal probe in a longitudinal panoramic view at 1 month after treatment in which a correct disposition of the pectoralis major muscle fibers without evidence of fibrotic scarring or complications.

Discussion

This paper shows that the treatment of injury in the pectoralis major of a gymnast treated with the Intratissue percutaneous electrolysis (EPI®) technique obtained excellent results and allowed for an early return to sports activity.

The pectoralis major muscle is a powerful internal rotator, flexor, and adductor of the arm and has its origin in the collarbone, sternum and the cartilages of the first six ribs. The pectoralis major muscle fibers converge in three bundles that rotate 180° that join to form a tendon which inserts into the lateral aspect of the humeral bicipital groove [8]. Patients with lesions of the pectoralis major muscle are clinically characterized by pain, bruising, swelling, and decreased range of motion. Clinically speaking, it is difficult to assess the extent and location of this type of injury except through ultrasound or magnetic resonance imaging evaluation. It is possible that a small initial injury of the pectoralis major muscle associated with lifting weights is not identified by ultrasound, but the patient may have pain in the anterior region of the chest [7,8,16,17]. In these cases, the immediate suspension of strength training is important so as to avoid further muscle ruptures of a serious nature within the first 6 weeks [1,4].

Tears of this muscle occur more frequently in the myotendinous junction or the insertion of the humerus and partial tears are more frequent than complete tears. The most commonly used clinical classification of this lesion is described by Tietjen [15]. It focuses on both the type of injury and the location of the lesion in relation to the origin or insertion. A type I injury refers to a concussion; a partial tear refers to type II, and type III to a complete rupture. On the other hand, it also stands out if the location of the lesion is in the sternal origin in the muscle, at the myotendinous junction or the humeral insertion.

The injuries of the pectoralis major muscle usually occurs during a high intensity eccentric action when the muscle is exposed to high tensile forces [4,5,7]. The main sports injury associated with the pectoralis major muscle are weightlifting, wrestling, gymnastics or wind-surfing.

Although MRI has been used to evaluate injuries of the pectoralis major muscle [6,7], ultrasound may also be useful in the assessment of this type of injury. A hypoechoic image corresponding to hematic collection inside the rupture of the pectoralis major muscle can be seen [18].

Treatment options for an injury of the pectoralis major muscle are based on an accurate assessment of the extent and location of the

lesion. Treatment is usually conservative in partial tears and sometimes in total ruptures in non-athletes. Surgical repair is used for complete tears and ruptures of the distal tendon in athlete patients [1-4]. The chosen method of treatment varies greatly depending on the literature consulted.

The Intratissue percutaneous electrolysis (EPI®) technique has proven effective in the treatment of soft tissue injuries [10,11] and experimental studies [12] have demonstrated that the early use of this technique reduces the fibrotic reactions secondary to these lesions. By using a high-intensity galvanic current, directed through a needle, rapid regeneration of damaged tissue is achieved. At the same time, the suction capacity provided by the EPI Medical Tissue Remover® device during the application of the technique makes it possible to evacuate the hematic content of the lesion, thereby facilitating healing and preventing potential later complications.

In the case presented, the ultrasound findings showed a large partial tear of the pectoralis major muscle with a large collection of blood. After treatment with the eco-guided Intratissue percutaneous electrolysis (EPI®) technique, the hematic fluid significantly decreased and proper remodeling of injured tissue was obtained, allowing the athlete to return to sports competition at 4 weeks after injury. The study with ultrasonographic images showed a repair of the myotendinous junction of the pectoralis major muscle with no signs of the formation of fibrotic scar tissue and no signs of hypoechoic thickening of the tendon.

Conclusion

Treatment with the US-guided EPI® technique on pectoralis major muscle tear resulted in a high improvement in function and a rapid return to the previous level of activity after few sessions. The procedure has proven to be safe with no recurrences at one-year follow-up.

Acknowledgments

We are grateful to E. Goode for his help in correcting the manuscript.

References

1. de Castro Pochini A, Andreoli CV, Belangero PS, Figueiredo EA, Terra BB, et al. (2014) Clinical considerations for the surgical treatment of pectoralis major muscle ruptures based on 60 cases: a prospective study and literature review. *Am J Sports Med* 42: 95-102.
2. Ziskoven C, Patzer T, Ritsch M, Krauspe R, Kircher J (2011) [Current treatment options for complete ruptures of the pectoralis major tendon]. *Sportverletz Sportschaden* 25: 147-152.
3. Garrigues GE, Kraeutler MJ, Gillespie RJ, O'Brien DF, Lazarus MD (2012) Repair of pectoralis major ruptures: single-surgeon case series. *Orthopedics* 35: e1184-1190.
4. de Castro Pochini A, Ejnisman B, Andreoli CV, Monteiro GC, Silva AC, et al. (2010) Pectoralis major muscle rupture in athletes: a prospective study. *Am J Sports Med* 38: 92-98.
5. ElMaraghy AW, Devereaux MW (2012) A systematic review and comprehensive classification of pectoralis major tears. *J Shoulder Elbow Surg* 21: 412-422.
6. El-Essawy MT, Al-Jassir FF, Al-Nakshabandi NA (2010) Magnetic resonance imaging assessment of the pectoralis major muscle rupture. *Saudi Med J* 31: 937-938.

7. Provencher MT, Handfield K, Boniquit NT, Reiff SN, Sekiya JK, et al. (2010) Injuries to the pectoralis major muscle: diagnosis and management. *Am J Sports Med* 38: 1693-1705.
8. Ball V, Maskell K, Pink J (2012) Case series of pectoralis major muscle tears in joint special operations task force-Philippines soldiers diagnosed by bedside ultrasound. *J Spec Oper Med* 12: 5-9.
9. Fleury AM, Silva AC, de Castro Pochini A, Ejnisman B, Lira CA, et al. (2011) Isokinetic muscle assessment after treatment of pectoralis major muscle rupture using surgical or non-surgical procedures. *Clinics (Sao Paulo)* 66: 313-320.
10. Abat F, Gelber PE, Polidori F, Monllau JC, Sanchez-Ibáñez JM (2014) Clinical results after ultrasound-guided intratissue percutaneous electrolysis (EPI®) and eccentric exercise in the treatment of patellar tendinopathy. *Knee Surg Sports Traumatol Arthrosc*.
11. Abat F, Diesel WJ, Gelber PE, Polidori F, Monllau JC, et al. (2014) Effectiveness of the Intratissue Percutaneous Electrolysis (EPI®) technique and isoinertial eccentric exercise in the treatment of patellar tendinopathy at two years follow-up. *Muscles Ligaments Tendons J* 4: 188-193.
12. Abat F, Valles SL, Gelber PE, Polidori F, Stitik TP, et al. (2014) Molecular repair mechanisms using the Intratissue Percutaneous Electrolysis technique in patellar tendonitis. *Rev Esp Cir Ortop Traumatol*.
13. Bak K, Cameron EA, Henderson IJ (2000) Rupture of the pectoralis major: a meta-analysis of 112 cases. *Knee Surg Sports Traumatol Arthrosc* 8: 113-119.
14. Schepsis AA, Grafe MW, Jones HP, Lemos MJ (2000) Rupture of the pectoralis major muscle. Outcome after repair of acute and chronic injuries. *Am J Sports Med* 28: 9-15.
15. Tietjen R (1980) Closed injuries of the pectoralis major muscle. *J Trauma* 20: 262-264.
16. Hasegawa K, Schofer JM (2010) Rupture of the pectoralis major: a case report and review. *J Emerg Med* 38: 196-200.
17. Ho LC, Chiang CK, Huang JW, Hung KY, Wu KD (2009) Rupture of pectoralis major muscle in an elderly patient receiving long-term hemodialysis: case report and literature review. *Clin Nephrol* 71: 451-453.
18. Lee SJ, Jacobson JA, Kim SM, Fessell D, Jiang Y, et al. (2013) Distal pectoralis major tears: sonographic characterization and potential diagnostic pitfalls. *J Ultrasound Med* 32: 2075-2081.