

Life-Threatening Upper Airway Obstruction as a Complication of Corrective Spinal Surgery in a Patient with Parkinson's Disease: A Case Report

Takashi Kobayashi^{1*}, Naohisa Miyakoshi², Toshiaki Abe¹, Kazuma Kikuchi¹, Eiji Abe¹, Kaori Fujiwara³ and Yoichi Shimada²

¹Department of Orthopedic Surgery, Akita Kousei Medical Center, 1-1-1 Iijima, Nishifukuro, Akita 011-0948, Japan

²Department of Orthopedic Surgery, Akita University Graduate School of Medicine, 1-1-1 Hondo, Akita 010-8543, Japan

³Department of Rehabilitation, Akita Kousei Medical Center, 1-1-1 Iijima, Nishifukuro, Akita 011-0948, Japan

Abstract

A 74-year-old female with a 10-year history of Parkinson's disease visited our hospital complaining of severe kyphoscoliosis deformity. Corrective spinal surgery was performed through a posterior approach. Oral anti-Parkinson medication was continued until the day of surgery, when continuous intravenous dopamine infusion was initiated; dopamine was discontinued and oral medication restarted on the day after surgery. Four weeks after surgery, the patient developed dyspnea. Laryngeal examination revealed rigidity of the neck muscles causing upper airway obstruction. Emergency tracheotomy was performed and the patient's respiratory condition improved immediately. Because of difficulty of swallowing, gastrostomy was performed 2 weeks after tracheotomy. After tracheotomy and gastrostomy, the patient's respiratory condition improved. Life-threatening upper airway obstruction can occur after corrective spine surgery in patients with Parkinson's disease. It is important to ensure the oral administration of anti-Parkinson medication after surgery.

Keywords: Parkinson's disease; Corrective spinal surgery; Complication; Upper airway obstruction; Lumbar kyphoscoliosis; Cervical kyphosis

Introduction

Patients with Parkinson's disease have a higher risk of complications following spine surgery than other patients. There are two categories of complications related to spine surgery in patients with Parkinson's disease. The first includes spine surgery-related complications, such as bleeding, surgical site infection, neurovascular injury, epidural hematoma, dura mater injury, and instrumentation failure [1-3]. The second includes complications related to Parkinson's itself, such as urinary tract infection, aspiration pneumonia, bacterial infection, post-operative delirium, and hypotension [4].

We report a rare case of life-threatening upper airway obstruction after corrective spinal surgery in a patient with Parkinson's disease and discuss its cause.

Case Report

A 74-year-old female with a pathologic fracture at L2 presented with gradually progressive kyphoscoliosis without trauma. The patient had a 10-year history of Parkinson's disease, which was Stage 5 at presentation [5]. Camptocormia was seen on standing. She could stand only briefly with support, had difficulty with transfer from bed to wheelchair, and was unstable even when sitting. She had no signs of airway obstruction or mouth-opening restriction before surgery and could feed herself. Her medications consisted of oral levodopa/benserazide (100 mg/10 mg five times daily), amantadine hydrochloride (50 mg five times daily), ropinirole (2 mg five times daily), and selegiline hydrochloride (2.5 mg three times daily). The patient's preoperative blood pressure was 100/60 mmHg with medication. Radiological examination revealed severe kyphoscoliosis deformity (Figures 1a and 1b) with vertebral compression fracture of L2 (Figures 1c and 1d).

The L2 vertebra was resected and replaced with two rectangular cages through a posterior approach. Instrumentation with pedicle screws and alar-iliac screws was placed from T4 to the pelvis (Figures 2a and 2b). Oral anti-Parkinson medication was continued until the day of surgery, when continuous intravenous dopamine was initiated and continued until the day after surgery. Operation time was 6 hours 30

minutes; total blood loss was 750 mL. After 5 hours of surgery, arterial systolic blood pressure suddenly elevated to 190 mmHg. The patient's blood pressure did not decrease with intravenous injection of 5 mg of diltiazem. After oral administration of hypertension medication, the patient's systolic blood pressure decreased to 120 to 150 mmHg. The patient received her regular dose of levodopa/benserazide and other oral medications on the morning after surgery.

After surgery, the patient experienced swallowing disturbance. Although she could be ingested a meal somehow on her own, dysphasia had worsened. Although we decided that she could take medicine exactly, anti-Parkinson medication was occasionally aspirated from the trachea during suctioning via an aspirator.

Four weeks after surgery, the patient developed dyspnea. Lifting her chin improved her dyspnea. Without her chin up, the patient could not breathe smoothly because of upper airway obstruction, and her systolic blood pressure fell to 30 mmHg. Laryngeal examination revealed neck muscle rigidity causing upper airway obstruction. Supine X-ray of cervical spine showed that the airway was closed (Figure 3). Emergency tracheotomy was performed and the patient's respiratory condition improved immediately. Because of difficulty of swallowing, gastrostomy was performed 2 weeks after tracheotomy. After tracheotomy and gastrostomy, the patient's respiratory condition and blood pressure improved.

The patient's swallowing function gradually recovered. Five months after surgery, laryngeal examination revealed improvement in the neck

***Corresponding author:** Takashi Kobayashi, Department of Orthopedic Surgery, Akita Kousei Medical Center, 1-1-1 Iijima-Nishifukuro, Akita 011-0948, Japan, Tel: +81-18-880-3000; Fax: +81-18-880-3040; E-mail: takakoba825@hotmail.com

Received November 18, 2016; **Accepted** December 06, 2016; **Published** December 08, 2016

Citation: Kobayashi T, Miyakoshi N, Abe T, Kikuchi K, Abe E, et al. (2016) Life-Threatening Upper Airway Obstruction as a Complication of Corrective Spinal Surgery in a Patient with Parkinson's Disease: A Case Report. J Spine 5: 348. doi: [10.4172/2165-7939.1000348](https://doi.org/10.4172/2165-7939.1000348)

Copyright: © 2016 Kobayashi T, et al. This is an open-access article distributed under the terms of the Creative Commons Attribution License, which permits unrestricted use, distribution, and reproduction in any medium, provided the original author and source are credited.

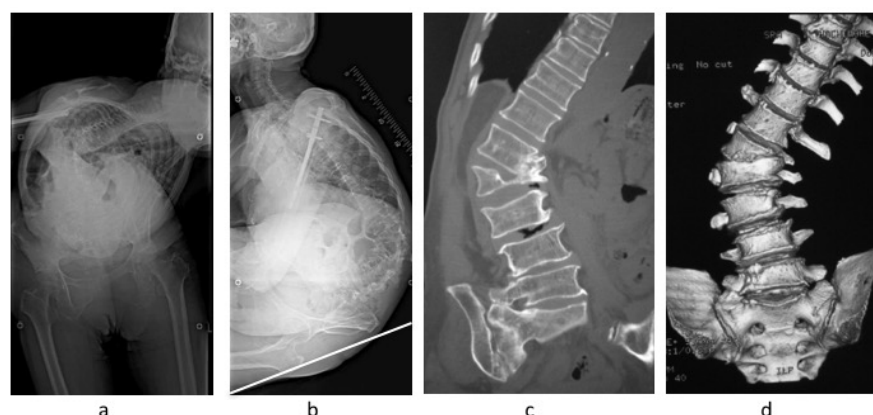


Figure 1: Preoperative standing X-ray and computed tomography. (a) Anterior-posterior radiograph. C7 plumb line was 30 mm lateral to sacral center. (b) Excessive kyphoscoliosis of the thoracolumbar spine is present; the cervical spine is in extension. White line shows gravity line. (c) A vertebral compression fracture is present at L2. (d) L1 vertebra is migrating to L2.

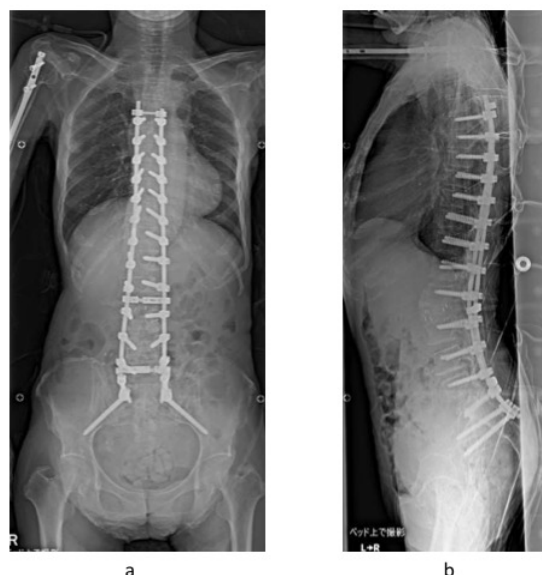


Figure 2: Postoperative X-ray in supine position. (a) Anterior-posterior radiograph. Corrective spinal surgery with resection of L2 and instrumentation from T4 to pelvis was performed. Good coronal alignment is achieved. (b) Lateral radiograph. Proper lumbar lordosis is achieved.

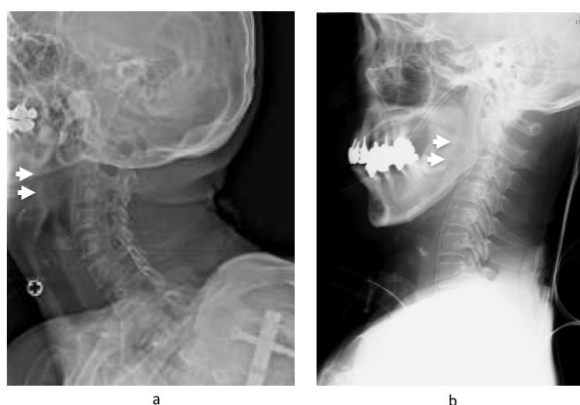


Figure 3: Pre- and postoperative X-ray of cervical spine. (a) Preoperative standing X-ray of cervical spine. Airway is open (arrowhead). (b) Postoperative supine X-ray of cervical spine at airway obstruction. Airway is closed (arrowhead).

muscle rigidity. A swallowing test showed no accidental aspiration. The patient started oral intake, and 1 year after surgery could again feed herself; her respiratory condition also improved. The patient was able to maintain a sitting position in her wheelchair, and could walk with walker support.

Discussion

Camptocormia in Parkinson's disease can be a great source of disability. Patients benefit from corrective surgery, despite the high complication rate [6]. Although many complications related to spine surgery have been reported in patients with Parkinson's disease [1-4], life-threatening upper airway obstruction has rarely been reported [7,8].

If patients are unable to take oral anti-Parkinson medication easily after surgery, upper airway obstruction can occur. Patients with Parkinson's disease are at greater risk for specific complications after abdominal or spine surgery, including urinary-tract infection, aspiration pneumonia, bacterial infection [4], and blood pressure instability [9]. Post-operative laryngospasm, sialorrhea, dysphagia, and esophageal dysmotility increase the risk of aspiration pneumonia [10]. There are only two reports of upper airway obstruction in a patient with Parkinson's disease [7,8]. One case experienced upper airway obstruction immediately after extubation caused by laryngospasm [7]. The patient required tracheal intubation for over 12 hours because of respiratory arrest caused by side effect of medicine. Her post-extubation laryngospasm was thought to be related to Parkinson's disease. Another case experienced upper airway obstruction caused by withdrawal of L-dopa in a patient with Parkinson's disease who was fasted before surgery [8]. The patient omitted anti-Parkinson medication for 2 days before surgery, and had an obstructed upper airway. In the present case, the cause of upper airway obstruction was suspected due to worsening of Parkinson's disease itself because this patient had not taken anti-Parkinson drugs properly until the occurrence of the current complication (during 4 weeks after surgery). Not only the post-operative sagittal alignment must have been fine but also cervical spine had never been fixed, therefore, the corrective surgery of the thoracolumbar spine seemed to have an insignificant effect.

Conclusion

In conclusion, life-threatening upper airway obstruction can occur after corrective spine surgery in patients with Parkinson's

disease. It is important to ensure oral administration of anti-Parkinson medication after surgery. If post-operative oral administration is difficult, a nasogastric tube can be considered to ensure medication administration.

Acknowledgments

The authors wish to thank Mamiko Kondo for her valuable assistance with the editing of this manuscript.

Ethics Approval and Consent to Participate

Not applicable.

Consent for Publication

Written informed consent was obtained from the patient for publication of this case report and accompanying images. A copy of the written consent is available for review by the editor-in-chief of this journal.

Availability of Data and Materials

All data supporting our findings are contained within the manuscript.

Competing Interests

The authors declare that they have no competing interests.

Funding

No funding has been received for this project.

Authors' Contributions

T.K. was the major contributor in writing the manuscript. N.M., E.A., T.A., K.K., K.H. and Y.S. supervised the whole work. All authors read and approved the final manuscript.

References

1. Babat LB, McLain RF, Bingaman W, Bingaman W, Kalfas I, et al. (2004) Spinal surgery in patients with Parkinson's disease: Construct failure and progressive deformity. *Spine* 29: 2006-2012.
2. Koller H, Acosta F, Zenner J, Ferraris L, Hitzl W, et al. (2010) Spinal surgery in patients with Parkinson's disease: experiences with the challenges posed by sagittal imbalance and the Parkinson's spine. *Eur Spine J* 19: 1785-1794.
3. Moon SH, Lee HM, Chun HJ, Kang KT, Kim HS, et al. (2012) Surgical outcome of lumbar fusion surgery in patients with Parkinson disease. *J Spinal Disord Tech* 25: 351-355.
4. Pepper PV, Goldstein MK (1999) Post-operative complications in Parkinson's disease. *J Am Geriatr Soc* 47: 967-972.
5. Hoehn MM, Yahr MD (1967) Parkinsonism: Onset, progression, and mortality. *Neurology* 17: S11-26.
6. Wadia PM, Tan G, Munhoz RP, Fox SH, Lewis SJ, et al. (2011) Surgical correction of kyphosis in patients with camptocormia due to Parkinson's disease: a retrospective evaluation. *J Neurol Neurosurg Psychiatry* 82: 364-368.
7. Backus WW, Ward RR, Vitkun SA, Fitzgerald D, Askanazi J (1991) Post-extubation laryngeal spasm in an unanesthetized patient with Parkinson's disease. *J Clin Anesth* 3: 314-316.
8. Fitzpatrick AJ (1995) Upper airway obstruction in Parkinson's disease. *Anaesth Intensive Care* 23: 367-369.
9. Van De Minkelis JL, Arts MP, Gutierrez Leon A, Pöhl JS (2011) Severe post-operative blood pressure instability in a patient with long standing Parkinson's disease. *Acta Anaesthesiol Belg* 62: 59-61.
10. Mariscal A, Medrano IH, Cánovas AA, Lobo E (2012) Perioperative management of Parkinson's disease. *Neurologia* 27: 46-50.