

Long Term Results of Pterygium Excision Using Different Surgical Techniques: A Retrospective Study

Ahmed Lubbad¹, Athanassios Giarmoukakis², Christina Skatharoudi², Nikos Astyrakakis¹ and Charalambos S Siganos^{1,2*}

¹Laboratory of Vision and Optics, School of Medicine, University of Crete, Heraklion, Crete, Greece

²Department of Ophthalmology, Heraklion University Hospital, Greece

*Corresponding author: Charalambos S. Siganos, Department of Ophthalmology, Heraklion University Hospital (P.A.G.N.I.), Crete 71110, Greece, Tel: +30-2810-371800; Fax: +30-2810-542094; E-mail: siganos@gmail.com

Received date: November 25, 2016; Accepted date: January 10, 2017; Published date: January 28, 2017

Copyright: ©2017 Lubbad A, et al. This is an open-access article distributed under the terms of the Creative Commons Attribution License, which permits unrestricted use, distribution, and reproduction in any medium, provided the original author and source are credited.

Abstract

Purpose: To retrospectively analyze data related to results of different techniques of pterygium surgery performed in the Cornea Service of the Department of Ophthalmology at the Heraklion University Hospital of Crete between the years 1998-2015.

Methods: Data from patients that completed at least 10 months of follow up were included in the study. Out of 115 eyes of 110 patients 80 eyes were operated for primary and 35 for recurrent pterygium. The surgical techniques included surgical excision with bare sclera (BSE), with and without the intraoperative 4 minute use of Mitomycin-C 0.02% (BSE+MMC), as well as surgical excision with conjunctival autograft (CAU) or amniotic membrane transplantation (AMT)

Results: During the mean follow up of 20+16.3 months, the overall recurrence rate was 9.6% (11 cases). BSE technique resulted in 16.7% recurrence (2 cases) in 12 primary pterygia, while 6 out of 68 primary pterygia (8.8%) recurred after BSE+MMC. Recurrent cases operated with BSE+MMC had 13% recurrence rate (3 out of 23), while none of the eyes that underwent CAU (9 cases) or AMT (3 cases) had another recurrence.

Conclusion: The long term results of the current study for different surgical techniques of pterygium excision are in accordance with the literature reports. Authors recommend the use of BSE+MMC for primary and quiet recurrent pterygia cases as being fairly effective, and CAU or AMT for invasive recurrent or even "angry" primary pterygia.

Keywords: Ocular surface; Pterygium; Mitomycin; Conjunctival graft; Amniotic membrane transplantation

Introduction

Pterygium is a common ocular surface degenerative condition, pathologically demonstrating elastoid degeneration of the conjunctiva, presenting as wing-shaped fibrovascular tissue, arising from the bulbar conjunctiva and invading on to the cornea [1]. The predisposition is attributed mainly to ultraviolet light exposure, thus the increasing reported prevalence (up to 22%) in countries within the area of 400 of the equator [2]. Other reported factors include Oxidative DNA damage, down-regulation of p53 gene [3]. In addition to the undesired cosmetic effect, pterygium can be symptomatic specially when inflamed causing redness, tearing and foreign body sensation. It can also affect vision by inducing astigmatism or even block visual axis if left to grow up to the cornea center [4]. The mainstay of pterygium treatment is surgical excision. Since however, simple excision was reported to have high recurrence rate up to 89% [4], adjuvant therapeutic modalities, such as beta irradiation, 5-fluorouracil, mitomycin-C as well as conjunctival or amniotic membrane transplantation, have been used to improve the results [5-12]. The current study presents the long term results of four methods, namely

surgical excision with bare sclera (BSE), its combination with bare sclera and intraoperative mitomycin-C (BSE+MMC), conjunctival autograft (SE+CAU) or amniotic membrane transplantation (SE+AMT).

Methods

Patient data collection

The study included retrospective analysis of data regarding surgeries conducted for pterygium, at the Cornea Service of the Department of Ophthalmology at the Heraklion University Hospital of Crete. Comprehensive preoperative ophthalmic examination was done for all patients; in addition to Schirmer test which when positive patient was excluded from the use of Mitomycin-C.

Data gathered for the period 1998-2015, and included: Number of eyes, number of patients, age, gender, pterygium type (primary or recurrent), and surgical method used (Table 1). All procedures were performed by the same surgeon (CSS) and the mean follow up period was 20 months (range: 10.2-98.5 months). The healing (epithelialization time), the recurrence rate as well as other complications related to surgery were looked for.

Pterygium type	Surgical procedure	n (eyes)	n (patients)	Mean age (years)	Gender
Primary	BSE	12	12	53.5	9 F/3 M
	BSE+MMC	68	64	53.3	33 F/31 M
Recurrent	BSE+MMC	23	22	52.5	14 F/8 M
	SE+CAU	9	9	55.4	6 F/3 M
	SE+AMT	3	3	59.6	1 F/2 M
Total		115	110	52.82	63F/47M

BSE: Bare Sclera Excision; MMC: Mitomycin-C; SE: Surgical Excision; CAU: Conjunctival Autograft; AMT: Amniotic Membrane Transplantation

Table 1: Patient demographics and different pterygium excision techniques.

Surgical techniques

Pterygium surgical excision with bare sclera: The procedure was performed under topical anesthesia with 0.2% benoxinate hydrochloride drops alone or with additional peribulbar injection of 0.5 ml 2% lidocaine with 1:200,000 epinephrines. The pterygium head after removing from its edges corneal epithelium to find a cleavage plane was dissected from the cornea using a Beaver 64 surgical blade (Rudolph Beaver, Inc, Belmont, MA). Subconjunctival fibrovascular tissue under the pterygium body and more widely inferior to the area of the pterygium was dissected and excised. The area was manually

polished using a crescent blade, while cauterization was applied when absolutely necessary. Pterygium body, including the adjacent tenon capsule, were dissected and excised using spring scissors, leaving the bare sclera exposed. Conjunctiva was resutured to the sclera using 10/0 nylon sutures leaving around 2 mm of bare sclera. At the end of surgery topical antibiotic ointment and steroid drops were instilled followed by eye patching. The sutures were removed after complete epithelialization of the cornea and the bare sclera area. The mean healing time for this procedure was 7.5+5.4 days (Table 2).

Pterygium	Surgery	n (eyes)	MHT ± SD	MFU ± SD	Recurrences	MRT ± SD	Gender-MA
Primary	BSE	12	7.5 ± 5.4	18.6 ± 6.9	2 (16.7%)	5.1 ± 4.1	1F/1M-59.5
	BSE+MMC	68	9.9 ± 7.2	21.8 ± 19.8	6 (8.8%)	15.1 ± 13.2	4F/2M-45.5
Recurrent	BSE+MMC	23	9.2 ± 4.8	18.13 ± 14.9	3 (13%)	11.3 ± 9.6	2F/1M-53.6
	SE+CAU	9	6.4 ± 2.9	15.3 ± 1.1	-	-	-
	SE+AMT	3	9.7 ± 7	13.6 ± 12.4	-	-	-
Total		115		20 ± 16.3	11 (9.6%)		73/61-52.82

MHT: Mean Healing Time (days); MFU: Mean Follow Up time (months); MRT (Mean Recurrence Time from surgery (months); MA: Mean Age (years)

Table 2: Outcome of different surgical techniques.

Intraoperative mitomycin-C (MMC)

After pterygium excision, in case of combination with Mitomycin-C, a 2 × 5-mm sponge was soaked in MMC diluted in saline solution 0.02% (0.2 mg/ml). The sponge was placed over the exposed sclera and the adjacent cornea. The remaining conjunctiva and tenon capsule were pulled over the sponge with 0.12 mm forceps, and the sponge was held in contact with the tissues for 4 minutes. The sponge was then removed and the area copiously irrigated with 30 ml balanced salt solution. Conjunctiva was resutured to the sclera using interrupted 10/0 nylon sutures leaving around 2 mm of bare sclera. At the end of surgery topical antibiotic ointment and steroid drops were instilled and followed by eye patching. The sutures were removed after complete epithelialization of the cornea as well as the bare sclera area. The mean healing time for this procedure was 9.9+7.2 and 9.2+4.8 days for primary and recurrent case respectively (Table 2).

Conjunctival autograft (CAU)

In case of conjunctival autografts, after pterygium excision the bare sclera area was measured with a caliper and a similar size conjunctival graft was obtained preferably from the superotemporal bulbar conjunctiva by splitting at the anatomic limbus. After polishing, graft was sutured and secured to the sclera up to the limbus, using interrupted 10/0 nylon sutures. At the end of surgery topical antibiotic ointment and steroid drops were instilled and followed by eye patching. The sutures were removed after complete epithelialization of the cornea as well as the graft area. The mean healing time for this procedure was 6.4+2.9 days (Table 2).

Amniotic membrane transplantation (AMT)

In case of AMT, after pterygium excision the bare sclera area was measured with a caliper and a 2 mm larger in size amniotic tissue was

prepared and sutured basement membrane side up, to the sclera up to the limbus. Care was taken in peripheral suturing to include remaining conjunctiva thus having amniotic membrane under it in order promote conjunctival epithelialization over the membrane and to inhibit subconjunctival fibrous tissue growth. At the end of surgery, topical antibiotic ointment and steroid drops were instilled followed by eye patching. The sutures were removed after complete epithelialization of the cornea as well as the sclera area covered with amniotic graft. The mean healing time for this procedure was 9.7+7 days (Table 2).

Postoperatively all patients were treated with topical antibiotic-steroid eye drops combination 6 times a day tapered over a period of three months, in addition to preservative free artificial tears. Patients were instructed to return for follow up at day 1, week 1 and 2, month 1,3,6,12 and yearly thereafter. Recurrence was defined as more than 1 mm fibrovascular growth over the peripheral cornea.

Results

The study included data from 115 eyes of 110 patients (47 males/63 females) that had pterygium excision surgery between the years 1998 and 2015 and follow up more than 10 months. Out of 115 eyes 80 had primary (69.6%) while 35 (30.4%) had recurrent pterygia. In 68 primary cases BSE+MMC were performed, while the rest 12 eyes were treated with BSE alone. In 23 out of the 35 recurrent cases BSE+MMC was performed, while of the rest 12 eyes 9 had SE+CAU and 3 had SE+AMT (Table 1). The mean age of patients was 52.82 years (range 18-84) and the mean follow-up time was 20 months (range 10.2-98.5). There were no significant differences in age, follow up time or healing time between the groups (One-way ANOVA test, $P>0.05$). During the first postoperative week, all patients had mild to moderate pain, foreign body sensation, and lacrimation. The severity and duration of symptoms were similar in all cases in this study. In all patients except two, complete epithelialization had taken place within the first 2 weeks after surgery. Three cases of delen developed postoperatively, 2 in the BSE group and one in BSE+MMC and were managed with bandage contact lens and topical treatment. No other complications were reported.

During the follow-up period, 11 out of the 115 cases experienced recurrence (overall 9.6%). Out of the 11 recurrences, 3 were operated for recurrent pterygium with BSE+MMC, while 8 cases were operated for primary pterygium (2 with BSE and 6 with BSE+MMC). No recurrences were reported for SE+CAU and SE+AMT cases. Surgical excision alone had 16.7% recurrence rate in primary cases, whereas combined with intraoperative Mitomycin-C the recurrence rate was 8.8% for primary and 13% for recurrent pterygia. The surgery to recurrence time ranged from 1.8 to 35.3 months (Table 2). Comparing the recurrence outcome for primary pterygia, between the BSE and the BSE+MMC groups, no statistical significance was found (Chi-square test, $p>0.05$).

Discussion

The current study retrospectively analyze data regarding pterygium surgery that took place between the years 1998-2015 in the Cornea Service of the Department of Ophthalmology at the Heraklion University Hospital of Crete. Patients enrolled only when completed at least 10 months of follow up (mean: 20 months, range: 10.2-98.5). From the records obviously many patients failed to show for longer follow up.

The study included 115 eyes of 110 patients that underwent pterygium surgery. Meticulous complete excision respecting conjunctival tissue is important in preventing recurrence. In our study the surgical excision with bare sclera technique in a follow up of 18.6 months (range: 11.6-32.7), resulted in 2 recurrences (16.7%) out of 13 primary pterygium cases occurring 2.2 and 7.1 months postoperatively. This was a small number of cases but the recurrence rate is in accordance or even lower than the range of values reported in the literature (24-89%) [4,5,13]. In the surgical technique used as described also before [5] healthy conjunctival tissue is respected, thorough resection of subconjunctival fibrous tissue is performed and remaining conjunctiva is secured with sutures to the sclera. Those steps intend to as much as possible delay fibrovascular proliferation and promote epithelialization.

The use of mitomycin whether topical or intraoperative is a well-known adjuvant treatment for ocular surface surgery in order to reduce recurrence [5-7,9,10,14]. In fact, a prospective study with the use of the same surgical technique, resulted in lower recurrence rate with MMC intraoperatively for 5 minutes [5]. In our cases 4 minutes use of 0.02% MMC for primary pterygia followed up as long as 21.8 months (range: 10.4-98.4), resulted in recurrence of 6 out of 68 cases (8.8%) that occurred 15.1 months after surgery (range: 1.8-25.6). Also, in recurrent pterygia followed up as long as 18.13 months postoperatively (range 10.7-79.1), use of MMC resulted in 13% (3 out of 23) recurrent cases 11.3 months after surgery (range: 9.5-35.3). Such results are in accordance with the lower values of recurrence range in the literature which is 6.7%-43.8% for primary and 16-25.5% for recurrent pterygia [15-19].

In only one out of the 3 cases of postoperative delen formation MMC was used. We assume that it is probably more related to the suturing technique and to the approximation of conjunctival tissue near the limbus area. No other complications related to mitomycin, such as delayed healing, scleral melting or iridocyclitis were reported. It is emphasized that a positive Schirmer test in the current study was an exclusion criterion for the use of MMC as also reported in previous work [14].

Nine cases operated for of recurrent pterygium were treated with conjunctival autograft, while 3 were treated with amniotic membrane transplantation followed up for 15.3 months (range: 11.4-26.8) and 13.6 months (range 12.3-14.3) respectively. This is a small number of cases, and the fact that there was no recurrence during follow up, cannot exclude this possibility. In the literature the reported recurrence rate for conjunctival grafts is 5-30%, while for AMT is 5-40% [20]. In those cases, and the fact that these techniques are usually performed for big recurrent pterygia, a good cover with conjunctival epithelium or amnion is essential in promoting healing and inhibiting proliferation of fibrovascular tissue.

In pterygium surgery as mentioned in the AAO report factors such as availability of resources, primary or recurrent status of pterygium, age of patient, and surgeon or patient preference, may influence the surgeon's choice of adjuvant because there are insufficient data to recommend a specific adjuvant as superior [21].

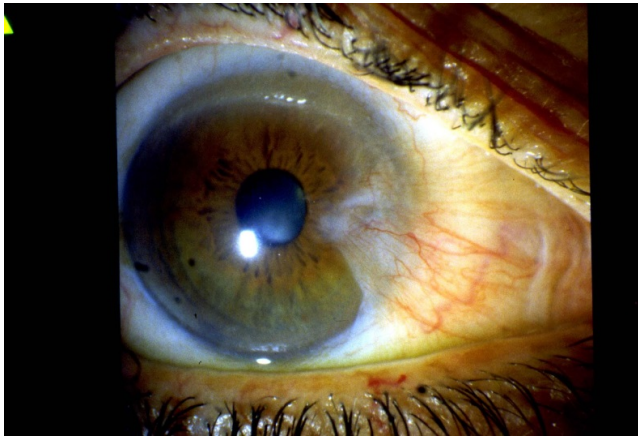


Figure 1: Primary pterygium.

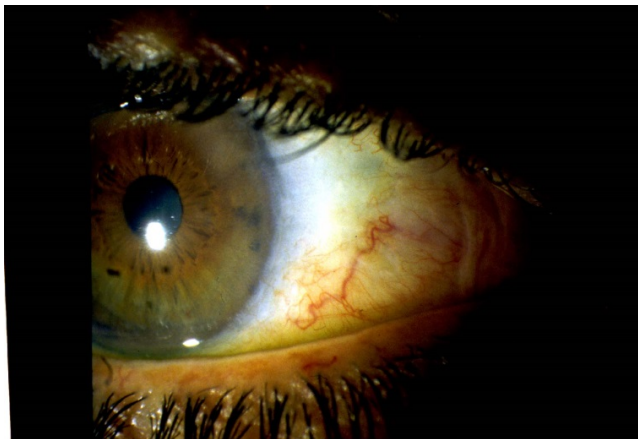


Figure 2: No recurrence of pterygium in fig.1, after excision combined with intraoperative Mitomycin.

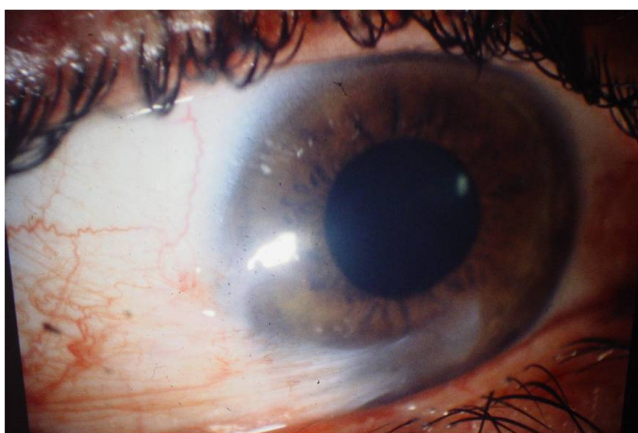


Figure 3: Recurrent pterygium.

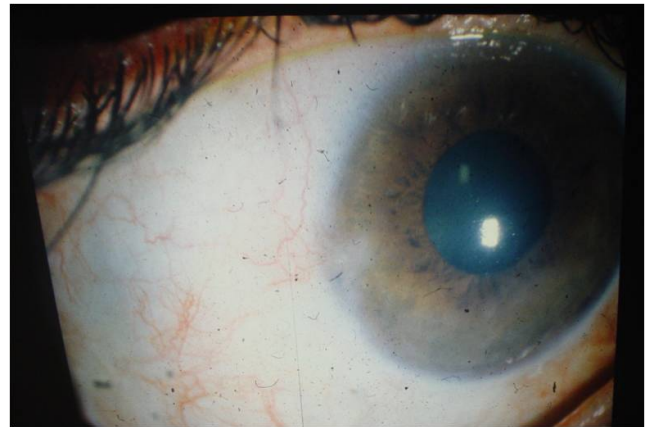

Figure 4: No recurrence of pterygium in Figure 3, after excision combined with conjunctival autograft.

Therefore, pterygium surgery like all ocular surface reconstruction procedures, is not a step by step operation but a unique for each patient management plan, with different factors affecting the outcome. Taking that and the above mentioned reservations in consideration, in conclusion, from retrospectively studying 115 pterygium surgeries with long term follow up of up to 98.5 months, we believe that small primary or recurrent pterygia when there is no contraindication, it is fairly safe and effective for reducing recurrence, to be managed with proper excision in combination with Mitomycin-C 0.02% for 4 minutes (Figures 1 and 2). On the other hand, in cases of big fleshy vascular either recurrent or even primary pterygia, more complex surgery technique, combined with conjunctival autograft (Figures 3 and 4) or amniotic membrane graft, should be considered.

References

1. Hill JC, Maske R (1989) Pathogenesis of pterygium. *Eye (Lond)* 3: 218-226.
2. Hilgers JH (1960) Pterygium: its incidence, heredity and etiology. *Am J Ophthalmol* 50: 635-644.
3. Maxia C, Perra MT, Demurtas P, Minerba L, Murtas D, et al. (2008) Expression of survivin protein in pterygium and relationship with oxidative DNA damage. *J Cell Mol Med* 12: 2372-2380.
4. Jaros PA, DeLuise VP (1988) Pingueculae and pterygia. *Surv Ophthalmol* 33: 41-49.
5. Frucht-Pery J, Siganos CS, Ilsar M (1996) Intraoperative application of topical mitomycin C for pterygium surgery. *Ophthalmology* 103: 674-677.
6. Frucht-Pery J, Siganos CS (2000) Adjunctive Medical Therapy for pterygium surgery. In: Taylor HR, ed. *Pterygium*. The Hague, Kugler Publications, The Netherlands, pp: 115-124.
7. Frucht-Pery J, Siganos CS (2000) Antiproliferative Therapy for pterygium surgery. In: Lucio Buratto ed. *Pterygium Surgery*. Slack Incorporated, Thorofare, NJ, USA, pp: 157-163.
8. Chan CM, Chew PT, Alsagoff Z, Wong JS, Tan DT (2001) Vascular patterns in pterygium and conjunctival autografting: a pilot study using indocyanine green anterior segment angiography. *Br J Ophthalmol* 85: 350-353.
9. Helal M, MessihaN, AmayemA, el-Maghraby A, Elsharif Z, et al. (1996) Intraoperative mitomycin-C versus postoperative topical mitomycin-C drops for the treatment of pterygium. *Ophthalmic Surg Lasers* 27: 674-678.

10. Siemczek-Thorin JC, Rocha G, Yelin JB (1998) Meta-analysis on the recurrence rates after bare sclera resection with and without mitomycin C use and conjunctival autograft placement in surgery for primary pterygium. *Br J Ophthalmol* 82: 661-665.
11. Shimmura S, Shimazaki J, Ohashi Y, Tsubota K (2001) Antiinflammatory effects of amniotic membrane transplantation in ocular surface disorders. *Cornea* 20: 408-413.
12. Hirst LW (2003) The treatment of pterygium. *Surv Ophthalmol* 48: 145-180.
13. Olander K, Haik KG, Haik GM (1978) Management of pterygia: should thiotepa be used? *Ann Ophthalmol* 10: 853-862.
14. Siganos CS, Kozobolis VP, Christodoulakis EV (2002) The intraoperative use of mitomycin-C in excision of ocular surface neoplasia with or without limbal autograft transplantation. *Cornea* 21: 12-16.
15. Keklikci U, Celik Y, Cakmak SS, Unlu MK, Bilek B (2007) Conjunctival limbal autograft, amniotic membrane transplantation, and intraoperative mitomycin C for primary pterygium. *Ann Ophthalmology* 39: 296-301.
16. Mahar PS, Manzar N (2013) Pterygium recurrence related to its size and corneal involvement. *J Coll Physicians Surg Pak* 23: 120-123.
17. Thakur SK, Khaini KR, Panda A (2012) Role of low dose mitomycin C in pterygium surgery. *Nepal J Ophthalmol* 4: 203-205.
18. Paracha Q, Ayoob M, Dawood Z, Mirza SA (2014) Recurrence rate with use of intraoperative mitomycin C versus conjunctival autograft following pterygium excision. *Pak J Med Sci* 30: 1243-1246.
19. Young AL, Ho M, Jhanji V, Cheng LL (2013) Ten-year results of a randomized controlled trial comparing 0.02% mitomycin C and limbal conjunctival autograft in pterygium surgery. *Ophthalmology* 120: 2390-2395.
20. Hacıoğlu D, Erdöl H2 (2016) Developments and current approaches in the treatment of pterygium. *Int Ophthalmol*.
21. Kaufman SC, Jacobs DS, Lee WB, Deng SX, Rosenblatt MI, et al. (2013) Options and adjuvants in surgery for pterygium: a report by the American Academy of Ophthalmology. *Ophthalmology* 120: 201-208.