

Long-Term Cardiovascular Symptoms in a Patient with a Large Diaphragmatic Hernia

Zhi-Tong Li, Xin-Wei Han, Feng Ji, Li Wang, Miao Xu and Zhong-Gao Wang*

Department of Interventional Radiology, First Affiliated Hospital of Zhengzhou University, China

Abstract

Large diaphragmatic hernia resulting in chest tightness and shortness of breath is a rare. A 74-year-old woman with cardiovascular presented was diagnosed with coronary heart disease secondary to diaphragmatic hernia after physical exertion. After laparoscopic diaphragmatic hernia repair, the symptoms disappeared.

Keywords: Cardiovascular symptoms; Diaphragmatic hernia; Laparoscop

Introduction

Chest pain and shortness of breath may have different background. The most common cause is CAD. But more than 20% of patients do not have abnormal coronary arteries [1], these who mainly are X syndrome and esophageal functional disorders [2]. We report a case of CAD presenting as chest pain and shortness of breath due to diaphragmatic hernia.

Case Presentation

A 74-year-old woman with cardiovascular disease presented was hospitalized with 10-year history of chest pain, shortness of breath, palpitation and slight acid reflux. She did not take any treatment. Two years ago coronary angiography found coronary stenosis, a coronary stent was implanted, but symptom relief was not obvious. Vital signs were normal. Physical examination found no abnormalities. Laboratory tests were normal, including complete blood count and myocardial enzymes.

A barium-contrast study of the upper gastrointestinal tract showed a small hiatal hernia and a large air-liquid in the bottom of the right lung (Figure 1). Subsequently, a chest radiography revealed a giant air-barium shadow closed to the lower right retrocardiac position (Figure 2). A computed tomography revealed that a huge mass containing air and barium herniated into the chest (Figure 3), which were mainly composed of right hepatic flexure and partial gastric tissue, and confirmed the presence of a large diaphragmatic hernia. On endoscopic examination, esophagitis was only found. Coronary Artery also was normal. The patient underwent laparoscopic diaphragmatic hernia repair with polypropylene mesh patch, hiatal hernia repair and Nissen fundoplication. The patient was asymptomatic at the time of discharge and had no recurrence of symptoms in three-month follow-

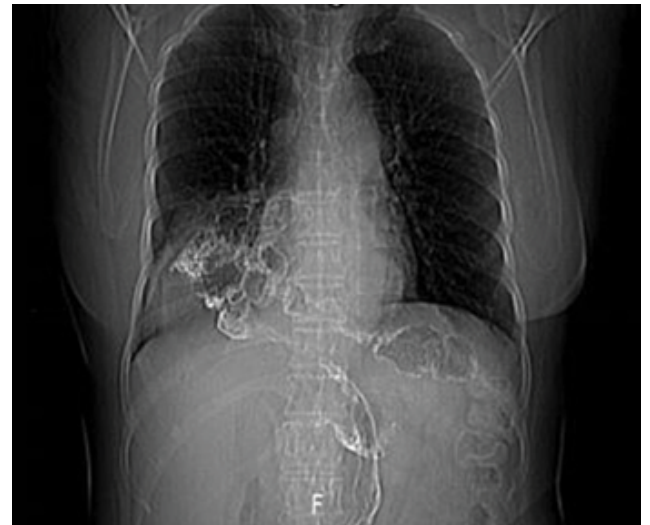


Figure 2: Chest radiography, a giant air-barium shadow in the right chest.

up. Diaphragmatic hernia disappeared and diaphragmatic damage had been repaired (Figure 4).

Discussion and Conclusion

Chest pain and shortness of breath are a common coronary heart disease chief complaint. The differentiation of cardiac versus noncardiac chest pain can be an especially difficult thing when patients present with symptoms of CAD [3]. Acute chest pain could be secondary to spontaneous gastric mesenteric vessel rupture due to a non-strangulated hiatal hernia [4]. The patient's chief complaint was CAD. The initial portable barium-contrast revealed a diaphragmatic hernia. The CT chest show a rare diagnosis of CAD secondary to right hepatic flexure and partial gastric tissue herniated into the chest. The patient had normal coronary artery. The large hernial sac may exert

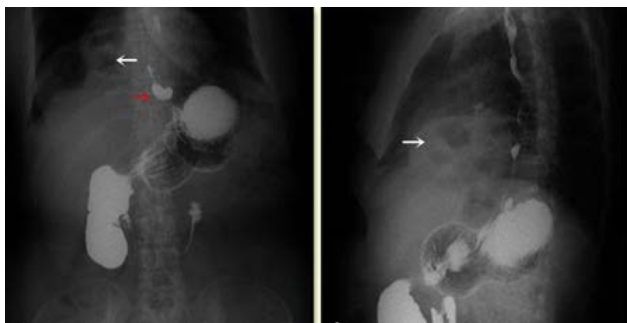

Figure 1: Upper gastrointestinal barium examination, the red arrow indicates a small hiatal hernia; the white arrow indicates a large air-liquid in the bottom of the right lung.

*Corresponding author: Zhong-Gao Wang, Department of Interventional Radiology and GERD, The First Affiliated Hospital of Zhengzhou University, Zhengzhou, Henan Province, P.R. China, Tel: 008618339943726; Fax: 008601062015718; E-mail: zhonggaowangfirst@126.com

Received March 04, 2017; Accepted March 20, 2017; Published March 25, 2017

Citation: Li ZT, Han XW, Feng J, Wang L, Xu M, et al. (2017) Long-Term Cardiovascular Symptoms in a Patient with a Large Diaphragmatic Hernia. Surgery Curr Res 7: 288. doi: 10.4172/2161-1076.1000288

Copyright: © 2017 Li ZT, et al. This is an open-access article distributed under the terms of the Creative Commons Attribution License, which permits unrestricted use, distribution, and reproduction in any medium, provided the original author and source are credited.

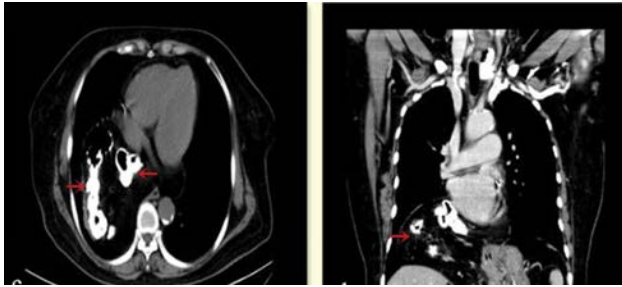


Figure 3: Chest CT, the red arrow indicates a huge mass containing air and barium in the chest.

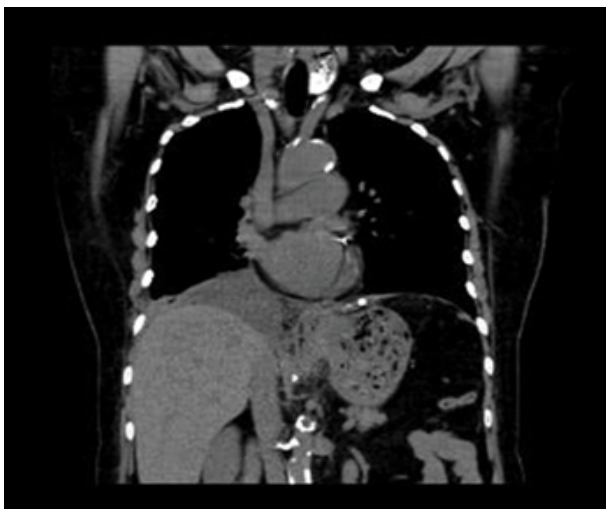

Figure 4: Chest CT, diaphragmatic hernia disappears and diaphragm is intact.

pressure on the surrounding tissues in the chest and lead to recurrent pneumonia, atelectasis, and compression of the heart [5,6]. These may be the cause of long-term obstructive symptoms in this patient.

The laparoscopic repair of large diaphragmatic hernia is a relatively safe method with significant long-term efficacy in terms of symptom control and quality of life [7]. Our patient may be the first diaphragmatic hernia associated symptoms of CAD and responded well to treatment. After hernia repair, symptoms of the patient disappeared and had no postoperative complications. This case illustrates the importance of patient's medical history, timely imaging examination and underlying pathogenesis analysis. The clinician overlooks other factors that contribute to cardiovascular symptoms. Written informed consent was obtained from the parents of the patients who participated in this study.

Conflict of Interest

There is no conflict of interest.

References

1. Trainor D, Duffy M, Kennedy A, Glover P, Mullan B (2007) Gastric perforation secondary to incarcerated hiatus hernia: an important differential in the diagnosis of central crushing chest pain. *Emerg Med J* 24: 603-604.
2. Scumpia AJ, Dekok ME, Aronovich DM (2015) Acute chest pain in a patient with a non-strangulated hiatal hernia. *Journal of Acute Disease* 4: 344-346.
3. Hsu JY, Chen SJ, Wang JK, Ni YH, Chang MH, et al. (2005) Clinical implication of hiatal hernia in patients with right isomerism. *Acta Paediatr* 94: 1248-1252.
4. Oishi Y, Ishimoto T, Nagase N, Mori K, Fujimoto S, et al. (2004) Syncope upon swallowing caused by an esophageal hiatal hernia compressing the left atrium: A case report. *Echocardiography* 21: 61-64.
5. Hsu JY, Chen SJ, Wang JK, Ni YH, Chang MH, et al. (2005) Clinical implication of hiatal hernia in patients with right isomerism. *Acta Paediatr* 94: 1248-1252.
6. Oishi Y, Ishimoto T, Nagase N, Mori K, Fujimoto S, et al. (2004) Syncope upon swallowing caused by an esophageal hiatal hernia compressing the left atrium: A case report. *Echocardiography* 21: 61-64.
7. Prassas D, Rolfs TM, Schumacher FJ (2015) Laparoscopic repair of giant hiatal hernia: A single center experience. *Int J Surg* 20: 149-152.