

Low Dose Fibrinolytic Therapy for Treating Right Heart Thrombus

Ali Bayraktar*

Trabzon Ahi Evren Gogus Kalp Ve Damar Cerrahisi Egitim Ve Arastirma Hastanesi, Trabzon, Turkey

Keywords: Heart; Thrombus; Pulmonary; Case report; Fibrinolysis; Hernia; Hypotension

Introduction

Right heart thrombus is a rare phenomenon specially in the absence of structural heart disease, presence of hypercoaguable status, malignant tumors or catheters in-situ may be the cause. It almost exclusively associated with pulmonary embolism and high mortality rates. Optimal therapy with least complications remains controversial. We represent a case with a floating right heart thrombi that we treated with low dose of fibrinolysis therapy.

Case Report

A 75 year old female patient was referred to our hospital due to epigastric pain, hypotension and elevated serum troponin level. She had a history of lumbar hernia operation 4 months ago with pulmonary embolism after operation, which had been treated with 3 months of vitamin K antagonist. She had decreased motor functions of the upper and lower extremities due to polyneuropathy and she was receiving physiotherapy. She was on Telmisartan/hydrochlorothiazide and Nifedipine for hypertension. She had no history of other chronic diseases. She had mild dyspnoea, on physical examination her blood pressure was 90/50 mmhg, a pulse rate of 120 beat/minute, cardiovascular examination revealed irregular first and second heart sounds, with systolic murmur at tricuspid area. Other system examinations were normal. Electrocardiography reveal an atrial fibrillation with a heart rate of 122 beat/minute. Transthoracic two dimensional echocardiography (TTE) revealed a mobile floating thrombus inside the right atrium extending sometimes into the right ventricle with each heart beat with a worm-like configuration (Figures 1 and 2). The patient have a normal left ventricular ejection fraction, mild pericardial effusion, moderate tricuspid regurgitation, dilated right atrium and ventricle, with a systolic pulmonary artery pressure of 55 mmHg. Parasternal short axes view showed a dilated main pulmonary artery, with thrombus occluding the ostium of right and left pulmonary artery, with thrombus occluding the ostium of right and

left pulmonary arteries (Figure 3). Patients pulmonary CT (Computed Tomographic) angiography revealed massive bilateral pulmonary embolism. Cardiovascular consultation was asked for surgical treatment but a high operative mortality suggest medical treatment to be safer. The patient treated with Intravenous low dose of Tissue Plasminogen Activator (t-PA) 25 mg for 6 h. After that two dimensional

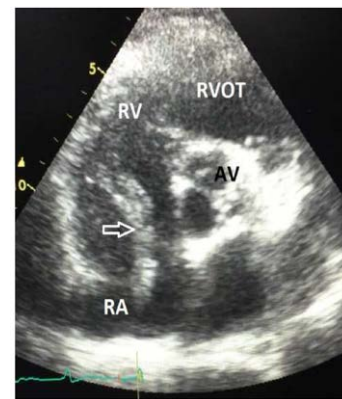

Figure 2: (TTE) Revealed a mobile floating thrombus inside the right atrium extending sometimes into the right ventricular with each heart beat with a Worm-like configuration.

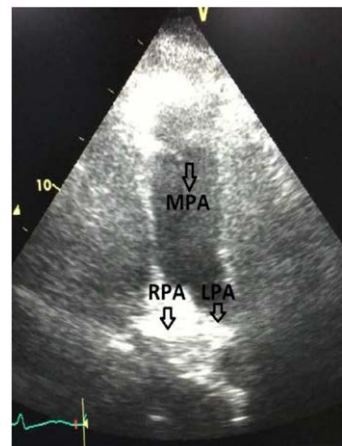


Figure 3: Parasternal short axes view showed a dilated main pulmonary artery, with thrombus occluding the ostium of right and left pulmonary arteries.

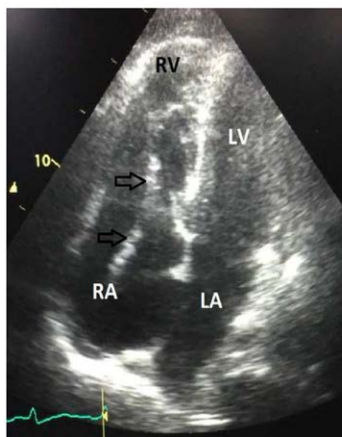


Figure 1: (TTE) Revealed a mobile floating thrombus inside the right atrium extending sometimes into the right ventricular with each heart beat with a Worm-like configuration.

*Corresponding author: Ali Bayraktar, MD, Trabzon Ahi Evren Gogus Kalp Ve Damar Cerrahisi Egitim Ve Arastirma Hastanesi, Trabzon, Turkey, Tel: +90 462 231 04 67; E-mail: alibayraktar76@yahoo.com

Received April 12, 2017; Accepted April 18, 2017; Published April 25, 2017

Citation: Bayraktar A (2017) Low Dose Fibrinolytic Therapy for Treating Right Heart Thrombus. Med Rep Case Stud 2: 131. doi: [10.4172/2572-5130.1000131](https://doi.org/10.4172/2572-5130.1000131)

Copyright: © 2017 Bayraktar A. This is an open-access article distributed under the terms of the Creative Commons Attribution License, which permits unrestricted use, distribution, and reproduction in any medium, provided the original author and source are credited.

TTE done and the thrombus was completely resolved (Figures 4 and 5). The patient felt better and her vital signs improved.

Discussion

Right heart thrombi can divide into two types depending on its morphology, may develop within the right heart chambers (Type B) the right-heart-thrombi-insitu. Whereas a floating right heart thrombi have a worm-like unusual shape and it commonly represents clots travelling from distal extremities to the pulmonary arteries (Type A) which is also called as thrombi-in-transit. This type is a rare phenomenon in the absence of structural heart disease, or the absence of devices like catheter or pace maker lead inside the right atrium. Free floating right heart thrombi are seen in 4-18% of patients presenting with acute massive pulmonary embolism [1-3]. Case series report high in hospital mortality 44.7% due to sudden pulmonary embolism [4]. The overall mortality rate in type A has been reported as 28% and as high as 100% in untreated patients [5]. Presenting symptoms may vary from mild dyspnoea or cough to very severe cardiogenic shock and even sudden death. In our case mild dyspnoea was the presenting symptom. The presence of free-floating thrombi is an emergency that needs early treatment and any delay in treatment can lead to worse outcomes and even could be lethal. Transthoracic echocardiography (TTE) is widely available, non-invasive, simple and painless investigation that is usually sufficient for detecting right heart thrombi and assess its morphology. Transesophageal echocardiography (TEE) can also detect right heart thrombus and can provide information about the presence of right-to-left shunt through a patent foramen ovale (PFO). Treatment options for free-floating right heart thrombus includes medical treatment with heparin, thrombolysis, interventional percutaneous thrombus retrieval

techniques or surgical intervention in appropriate patients. An optimal therapy is remain controversial because randomized controlled trails are lacking. A report by Chartier et al. showed that there was no important difference between these therapeutic approaches regarding in-hospital mortality. They report a series of 38 patients with free-floating thrombi in the right heart treated during a 12 year period. Mortality rate was high regardless of which treatment option was chosen. The mortality rates were (50%) in interventional percutaneous technique, (47.1%) for surgery, (62.5%) for heparin alone and (22.2%) for thrombolytic agents [4]. On contrary, Rose et al. report a retrospective analysis (5) of 177 patients with right heart thromboembolism, and found that 98% of patients had pulmonary embolism. In this analysis (9%) did not receive treatment, (35.6%) had surgical embolectomy, (35%) received anticoagulation alone, and (19.8%) had treated with thrombolysis. The mortality rate associated with anticoagulation treatment was (28.6%), with surgical embolectomy (23.8%), and with thrombotic therapy (11.3%). Subgroup-analysis in 123 patients showed that surgery was associated with an increase risk of mortality. In multivariate analysis that takes survival as the primary outcome, treating patients with thrombolytic therapy was associated with an improved survival rate ($P<0.05$), when compared to either surgical treatment or anticoagulation therapy. A prospective study done in 9 patients with mobile right heart thrombus and massive pulmonary embolism showed a good outcome and rapid improvement of echocardiographic and scintigraphic parameters after using of rt-PA thrombolytic agent. Surgical thromboembolectomy is considered as classical treatment for right heart thrombus. But it has its own potential complications including general anesthesia, cardiopulmonary bypass, and inability to remove coexisting pulmonary thromboemboli beyond the central pulmonary arteries. Therefore thrombolysis remains a fast and simple treatment option with several advantages including a rapid pulmonary reperfusion, improvement of right ventricular function, reduction in pulmonary hypertension, possibility of dissolving the intracardiac thrombus, pulmonary embolism, and venous thromboembolism at the same time.

Conclusion

Mortality in patients with right heart thrombus remains high regardless the cause and the type of treatment approach that chosen. Echocardiography is an important investigation that can be perform at the bedside and help for early diagnosis and thus rapid intervention. Treating right heart thrombus with low dose thrombolysis is relatively safe, fast, simple and effective.

References

1. Goldhaber SZ, Visani L, De Rosa M (1999) Acute pulmonary embolism: Clinical outcomes in the International Cooperative Pulmonary Embolism Registry (ICOPER). *Lancet* 353: 1386-1389.
2. Torbicki A, Galié N, Covezzoli A, Rossi E, De Rosa M, et al. (2003) Right heart thrombi in pulmonary embolism: Results from the International Cooperative Pulmonary Embolism Registry. *J Am Coll Cardiol* 41: 2245-2251.
3. Chartier L, Béra J, Delomez M, Asselman P, Beregi JP, et al. (1999) Free-floating thrombi in the right heart: Diagnosis, management, and prognostic indexes in 38 consecutive patients. *Circulation* 99: 2779-2783.
4. Rose PS, Punjabi NM, Pearse DB (2002) Treatment of right heart thromboemboli. *Chest* 121: 806-814.
5. Pierre-Justin G, Pierard LA (2005) Management of mobile right heart thrombi: A prospective series. *International Journal of Cardiology* 99:381-388.

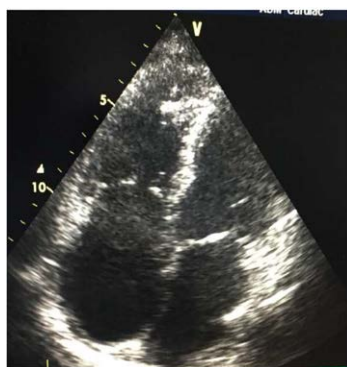


Figure 4: 2 dimensional TTE done and the thrombus was completely resolved. The patient felt better and here vital signs improved.

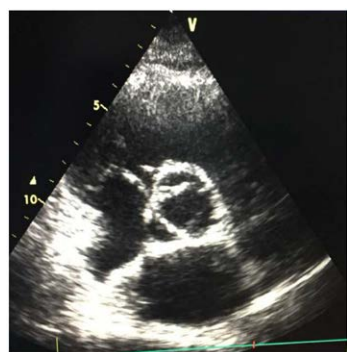

Figure 5: 2 dimensional TTE done and the thrombus was completely resolved. The patient felt better and here vital signs improved.

Citation: Bayraktar A (2017) Low Dose Fibrinolytic Therapy for Treating Right Heart Thrombus. Med Rep Case Stud 2: 131. doi: 10.4172/2572-5130.1000131