

Management of Acne Scarring

Chang D*

Academy of Aesthetic Medicine, Korean Medical Aesthetics Clinic, Singapore

*Corresponding author: Daniel Chang, Medical Director, Academy of Aesthetic Medicine, Korean Medical Aesthetics Clinic, Singapore, Tel: + 65-98341433; E-mail: drdanielchang1107@gmail.com

Received date: July 12, 2017; Accepted date: September 29, 2017; Published date: October 15, 2017

Copyright: © 2017 Chang D. This is an open-access article distributed under the terms of the Creative Commons Attribution License, which permits unrestricted use, distribution, and reproduction in any medium, provided the original author and source are credited.

Keywords: Pulse Dye Laser; Dyschromia; Hyperpigmentation; Neocollagenesis; Microbotox

predominant in nodulocystic acne [1]. Options for treatment depends on acne scarring severity, scar type (Table 1), scar site and patient skin type, choice of treatment modality and side effects risk profile. This paper attempts to share with you the management of acne scarring [2].

Short Communication

Acne scarring is a fibrous process involving new collagen production to heal a wound. It affects those with acne vulgaris and is

Different types of scars	Symptoms
Flat scars	These can be red, brown or pale flat marks
Mild hypertrophic and atrophic scars	Sunken or raised scars, not visible at distances of 50 cm or more
Moderate hypertrophic and atrophic scars	Visible at distances of ≥ 50 cm, camouflaged and can be even out by stretching the skin
Severe hypertrophic and atrophic scars	Visible at distances ≥ 50 cm, difficult to be camouflaged and cannot be even out by stretching of the skin

Table 1: Grading of scar severity can be assessed objectively using pre and post-treatment comparisons.

Hence it is important to understand the severity of the scars, as treatment is directly dependent on it. There is mainly 4 forms of atrophic acne scars (Table 2) (Figures 1-4).

Types of scars	Characteristics
Ice-pick scars	Visibly narrow, pitted and deep scars
Rolling scars	Broad sloping edges
Boxcar scars	Broad sunken-ness with sharply defined edges
Hypertrophic and keloidal	Lumpy and thick scars

Table 2: Different forms of acne scar.

Unfortunately, hypertrophic or keloid scars tend to reappear even after a good result is obtained post treatment. Traditionally, scar revision surgery is employed. Ablative lasers, carbon dioxide and erbium YAG laser are successful for surgery. To improve the color of scars, Pulse Dye Laser (PDL) has been effectively utilized. The PDL can reduce erythema and textures of the scar. Multiple treatments are needed.

A microneedle radiofrequency laser, an example of which is the INTRAcel from Korea, has produced significant results. It uses an insulated microneedle that delivers radiofrequency energy to the dermis, reducing damage to the epidermis, hence speeding up recovery. In my practice, I use a schedule of 4 sessions of INTRAcel, and can achieve results of 60% upwards for acne scars. More recently, the plasma laser have been used, achieving good results with minimal downtime and epidermal damage.

Ultimately the challenge is true acne scars never completely fade, although they visibly improve as time passes. The good thing is, they can be concealed. Patient skin type is also an important factor. Skin type can be classified from Fitzpatrick 1 to 6. Darker skin types have a higher risk of post inflammatory hyperpigmentation. Hence they benefit more from fractional laser compared to traditional full ablative lasers. Scars can occur anywhere on the body, although the upper chest and shoulders are especially prone to them. This is due to poorer regeneration capability, from the lower density of adnexa structures (sebaceous glands, hair follicles).

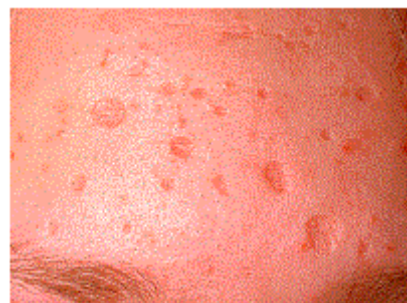

Figure 1: Boxscars (broad sunken-ness with sharply defined edges).

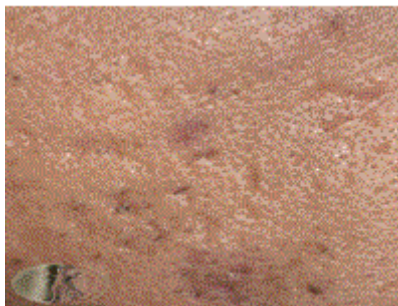

Figure 2: Rolling scars (broad sloping edges).

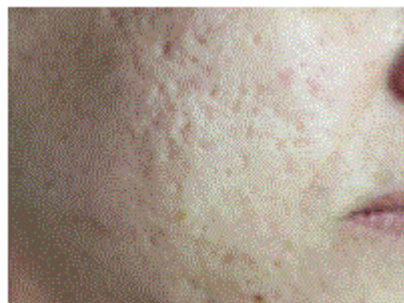


Figure 3: Ice-pick, atrophic scars (visibly narrow, pitted and deep scars).

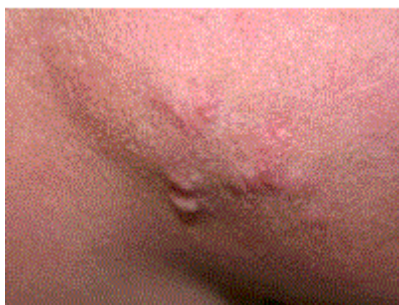

Figure 4: Hypertrophic and keloidal scars (lumpy and thick scars).

- Grade 2 mild scars: Fractional, vascular and pigment lasers as well as microneedling.
- Grade 3 scars: Full ablative and fractional lasers, and may require scar revision occasionally.
- Grade 4 scars: Require a multimodality approach [4].

Technology

Ablative laser

Ablative laser resurfacing utilizes electromagnetic waves to erode the entire epidermis and upper layer of dermis. Fractional laser treatment addresses both the epidermis and dermis. It delivers hundreds of laser beamlets. The principle is controlled dermal damage in MTZ (Micro Thermal Treatment Zones) in order to stimulate fibroblast to aid collagen remodeling and neocollagenesis. MTZ are selected areas with dermal injury, while sparing adjacent areas. They areas with injury would in turn kick start the process of neocollagenesis, while the adjacent areas maintain cell renewal and healing. In this way, the electromagnetic energy is effective yet safe, meanwhile keeping surrounding tissue healthy, aiding wound healing. This leads to faster recovery and less downtime. Today, the main laser resurfacing treatments can be divided into the non-ablative and the fractional. Techniques using other modalities may include microneedling, high intensity focused ultrasound systems and platelet rich plasma amongst others [5].

Non ablative laser

Non ablative lasers deliver electromagnetic energy into the dermis, inducing selective injury, leaving the epidermis untouched. The safety profile and speedy recovery have more than compensated for its slower results. And in today's day and age, the public want treatments that have minimal downtime. There are 3 main types of non-ablative modalities, mid-infrared ones, the Pulse dye lasers (PDL) and broadband light systems. These lasers work well for dyschromia but the textural improvement in scars is minimal [6].

Treatment Summary

- Laser as standalone treatment is a thing of the past.
- Combination is the key approach moving forward.

CO₂ ablative laser was the primary modality for the treatment of acne scars. However, it has extensive downtime of 2 or more weeks. Erbium YAG laser has slower clinical efficacy, shorter downtime and minimal recovery time. Now, the focus is on multi-modality treatments to achieve good results, safe and effective with low downtime. Hence the popularity of fractional lasers [7-9].

Side Effects

Side effects include redness and swelling, skin dyschromia, scarring, skin infections, eczema etc. After ablative fractional lasers, these following are common side effects, especially over the neck.

- Excessive skin peeling, scaling and crusting.
- Swelling for up to 7 days post treatment, which can be reduced with regular icing.
- Post inflammatory hyperpigmentation-High frequency in darker skin patients and those with previous episodes.
- Acneiform eruptions, herpes, bacterial, fungal infections and contact dermatitis [10-12].

Technology and Treatment Factors

The major complication of acne is scarring, which results in severe comorbidity for patients. On the bright side, there exists several options to treat acne scarring. Studies support combination treatment to achieve the best results. The safety and efficacy has good evidence, but there is a dearth of split-face trials [3].

Scar types and treatment

- Grade 1 scars: Topical treatment with silicone based gels combined with careful use of pigment, vascular and fractional lasers.

Conclusion

- Fractional laser resurfacing
- Role of microneedling, RF (thermage) and microbotox as the trend for future. The science is stimulation of collagen production. Results are visible after 3 months [13,14].
- Dermal Fillers can be used to fill atrophic scars and lift the sunken, depressed skin [15].
- Plasma laser for the future

To bring it to another level, RF microneedling is a new technique invented in Korea. It works to reduce scars, both atrophic and hypertrophic scars. The science is dermal matrix remodeling. The downtime is minimal; must less than fractional lasers, the side effects of post inflammatory increased pigmentation on darker skin types is much reduced, and the results are comparable [16].

Dermal fillers

A soft filler like restylane vital can be used to fill up the depression in atrophic scars, and subcision can be employed to breakdown the fibers that are anchoring the skin down. In my practice, I commonly combine this with RF Microneedling or fractional laser, over 4 sessions, and the results are significant. Studies have noted the use of PRP can speed up recovery [17].

Plasma laser

This relies on the 4th state of matter to ionize particles. It removes oxygen from cells, hence reducing the risk of charring the skin. The heat reaches a good temperature to stimulate neocollagenesis to improve scar texture and tone. The safety profile is high, with low risk of hypopigmentation and hyperpigmentation.

References

1. Gollnick HP, Dreno B (2015) Pathophysiology and management of acne. *J Eur Acad Dermatol Venereol* 29: 1-2.
2. Goodman GJ, Baron JA (2006) Post acne scarring: A qualitative global scarring grading system. *Dermatol Surg* 32: 1458-1466.
3. Hession MT, Graber EM (2015) Atrophic acne scarring: A review of treatment options. *J Clin Aesthet Dermatol* 8: 50-58.
4. Goodman GJ (2011) Treatment of acne scarring. *Int J Dermatol* 50: 1179-1194.
5. Tanzi EL, Lupton JR, Alster TS (2003) Lasers in dermatology: Four decades of progress. *J Am Acad Dermatol* 49: 1-34.
6. Alexiades MR, Dover JS, Arndt KA (2008) The spectrum of laser skin resurfacing: Nonablative, fractional, and ablative laser resurfacing. *J Am Acad Dermatol* 58: 719-737.
7. Cohen BE, Brauer JA, Geronemus RG (2015) Acne scarring: A review of available therapeutic lasers. *Lasers Surg Med* 48: 95-115.
8. Rao J (2011) Treatment of acne scarring. *Facial Plast Surg Clin North Am* 19: 275-291.
9. Rose AE (2014) Therapeutic update on acne scarring. *J Drugs Dermatol* 13: 651-654.
10. Rahman Z, Alam M, Dover JS (2006) Fractional laser treatment for pigmentation and texture improvement. *Skin Therapy Lett* 11: 7-11.
11. Rokhsar CK (2005) Fraxel[®] laser treatment reliant technologies: Product review.
12. Carniol PJ, Hamilton MM, Carniol ET (2015) Current status of fractional laser resurfacing. *JAMA Facial Plast Surg* 17: 360-361.
13. Fabbrocini G, Fardella N, Monfrecola A, Proietti I, Innocenzi D (2009) Acne scarring treatment using skin needling. *Clin Exp Dermatol* 34: 874-879.
14. Goodman GJ, Van Den AB (2016) The modified tower vertical filler technique for the treatment of post-acne scarring: The modified tower filler technique. *Australas J Dermatol* 57: 19-23.
15. Cho SI, Chung BY, Choi MG, Baek JH, Cho HJ, et al. (2012) Evaluation of the clinical efficacy of fractional radiofrequency microneedle treatment in acne scars and large facial pores. *Dermatol Surg* 38: 1017-1024.
16. Lee JW, Kim BJ, Kim MN, Mun SK (2011) The efficacy of autologous platelet rich plasma combined with ablative carbon dioxide fractional resurfacing for acne scars: A simultaneous split-face trial. *Dermatol Surg* 37: 931-938.
17. Bentkover SH (2012) Plasma skin resurfacing: Personal experience and long-term results. *Facial Plast Surg Clin North Am* 20: 145-162.