

Massive Overdose of Calcium Channel Antagonist and Successful Management: A Case Report and Review of Management

Chirag Rana^{1*}, Mukund Das¹, Dave Traficante² and John Kashani²

¹Department of Internal Medicine, St. Joseph's Regional Medical Center, New York Medical College, Paterson, NJ, USA

²Department of Emergency Medicine, St. Joseph's Regional Medical Center, New York Medical College, Paterson, NJ, USA

*Corresponding Author: Chirag Rana, Department of Internal Medicine, St. Joseph's Regional Medical Center, 703 Main Street, Paterson, NJ 07503, USA, Tel: 973-807-8945; Fax: 973-754-3376; E-mail: chirana87@gmail.com

Received date: August 09, 2016; Accepted date: September 21, 2016; Published date: September 26, 2016

Copyright: © 2016 Rana C, et al. This is an open-access article distributed under the terms of the Creative Commons Attribution License, which permits unrestricted use, distribution, and reproduction in any medium, provided the original author and source are credited.

Abstract

Calcium channel blockers (CCBs) toxicity is one of the most lethal drug overdoses encountered in the emergency department (ED). Nondihydropyridines (Verapamil and Diltiazem) are more lethal in overdose compared to dihydropyridines. The toxicity of these drugs is an extension of their therapeutic effect resulting from blockade of L-type calcium channels in smooth muscle cells, myocardial cells, and beta cells of the pancreas. Significant overdoses can present with bradycardia, hypotension, cardiac arrest, hyperglycemia, metabolic acidosis and shock that can result in death. There have been many reported cases of Diltiazem toxicity treated with what would be considered standard approaches to treatment. However, very little has been reported on massive overdoses with Diltiazem and successful management of such cases. Here, we report on a young patient who self reportedly overdosed on two bottles of Diltiazem (approximately 60 pills). Initially, she was asymptomatic but shortly after her presentation, she became hemodynamically unstable. In this case report we discuss how we successfully managed the patient and give recommendations for management of such massive lethal overdoses.

Keywords: Diltiazem; Amlodipine; Drug overdose; Calcium channel blockers

Introduction

Drug poisoning is the leading cause of injury-related deaths in the United States. According to Centers of Disease Control and Prevention, during 2008 to 2011, over one million emergency department (ED) visits was made each year owing to drug poisoning. National Institute on Drug Abuse estimates that about 27% of drug toxicity involves nonmedical use of pharmaceuticals. The American Association of Poison Control Centers reported 4921 cases of CCBs toxicity in 2013; therefore, understanding the emergent management of such toxicity is essential [1]. The majority of overdose occurs in adolescents during suicide attempts.

CCBs are widely prescribed for the management of hypertension, arrhythmias, angina pectoris and prevention of cerebral vasospasm. They are divided into two major categories: dihydropyridines (Amlodipine, Nifedipine, Nicardipine, Nimodipine, etc) which preferentially block the L-type calcium channel in vascular smooth muscle and the nondihydropyridine (Verapamil and Diltiazem) which are selective for the L-type calcium channel in the myocardium. These calcium channels play an important role in contractility of myocardium and vascular smooth muscle, conduction pathway, and regulation of pacemaker cells. The dihydropyridines are potent vasodilators but have minimal effect on myocardium contractility and conduction pathway. On the other hand, nondihydropyridines have a greater effect on myocardium contractility and conduction pathway but minimal effect on vasodilatation. It should be noted that at higher doses, the selectivity is usually lost and patients with overdose of both classes of CCBs can present with hypotension, bradycardia, bradydysrhythmia, hyperglycemia, pulmonary edema and cardiac

arrest. The presentation is also affected by whether the CCBs are immediate-release or extended-release. In general, immediate-release preparations presumably have a quicker onset than extended-release preparation. Overdose of immediate-release CCBs cause rapid hypotension, bradydysrhythmia, and cardiac arrest; on the other hand, extend-release CCBs overdose may present with delayed onset of bradydysrhythmia, shock, sudden cardiac collapse, and bowel ischemia [2]. Therefore, even for the patients who present completely asymptomatic require careful observation and monitoring in the ED. In this case report, we report on a young female who presented to our ED with a massive overdose of Diltiazem. She was initially asymptomatic but developed hypotension and bradydysrhythmia preceding profound circulatory shock. In the discussions, we give our recommendations for successfully managing such cases.

Case Report

A 25-year-old female with no prior significant medical history presented to the ED after intentionally overdosing on an unknown amount of Ibuprofen, Diltiazem, Amlodipine, Levothyroxine, and Guaifenesin approximately 1.5 to 2 hours prior to initial set of vital signs in the ED (at 14:55). According to her family, she had ingested two bottles of Diltiazem 240 mg (30 capsules in each bottle) in a suicide attempt. In the ED, she had no apparent signs or symptoms of drug toxicity and was fully conscious. She denied any cardiac, respiratory, gastrointestinal, or neurological symptoms. Her initial set of vital signs (at 14:55) were blood pressure of 114/78 mmHg, heart rate of 86 beats per minute, respiratory rate of 14 breaths per minute, temperature of 98.4° Fahrenheit and arterial oxygen saturation of 98% on room air. Although she appeared to be in mild distress, she was completely awake, alert, oriented and the rest of her physical examination was unremarkable. Several diagnostic tests including urine drug toxicology, acetaminophen level, blood alcohol level,

salicylate level, serum electrolytes, and liver function tests were performed and were found to be within normal range. Her initial serum electrolytes panel showed a potassium of 4.1, bicarbonate of 22, creatinine of 0.81, and glucose of 89. Her electrocardiogram (at 14:58) showed normal sinus rhythm with a rate of 86 beats per minute.

While in the ED, the patient's blood pressure started to deteriorate with a systolic blood pressure dropping to low 80s with heart rate was in mid-90s (Table 1 and Figure 1). Therefore, she was started on intravenous fluid and was administered a 10 ml 10% Calcium Gluconate intravenous push (at 17:03) followed by an intravenous administration of 10 ml Calcium Chloride (at 17:45) over 15 minutes. A finger stick blood glucose measurement revealed hyperglycaemia (blood glucose level of 277). Therefore, an insulin drip was started with 10% dextrose in water and the patient's blood glucose was monitored closely every 15 minutes. A central line was placed and she was transferred to the intensive care unit (ICU).

In the ICU, the patient was continued on intravenous calcium, insulin, and dextrose and her blood pressure gradually improved to 112/57 (at 18:19). However, four hours later, her blood pressure again dropped to 98/33 (at 22:30). She became bradycardic with a heart rate of 60 and her systolic blood pressure continued to drop to 80s despite fluid administration. Therefore, she was started on norepinephrine drip. She then started complaining of abdominal pain and severe nausea. A repeat serum electrolyte panel showed a potassium of 3.2, creatinine of 0.8, phosphate of 2.4, and bicarbonate of 18 with an anion gap of 13, indicating anion-gap metabolic acidosis. Her blood glucose level dropped to 121 and therefore the 10% dextrose in water was changed to 50% dextrose in water at a rate of 50 ml per hour. Her arterial blood gases on room air were pH of 7.17, pCO₂ of 25 mmHg, pO₂ of 118 mmHg, and HCO₃ of 18 mEq/L. A repeat electrocardiogram (at 19:48) showed a junctional rhythm which progressed to an accelerated junctional rhythm with retrograde conduction within the next 2 hours. An intravenous bolus of 80 ml 20% lipid emulsion solution was administered, followed by a 500 ml infusion of the same solution maintained for 40 minutes. Her blood pressure remained consistently low and was therefore started on dopamine. The patient had also developed a low urine output, and thus 3 liters bolus of normal saline and 1 liter bolus of crystalloid solution were administered.

The next morning (at 3:00), the repeat arterial blood gas showed a pH of 7.09, PCO₂ of 22 mmHg, PO₂ of 117 mmHg, and HCO₃ of 6 mEq/L, indicative of worsening metabolic acidosis. Another repeat serum electrolyte panel showed potassium of 4.3, creatinine of 1.53, bicarbonate of 6 with anion gap of 18, and glucose level of 473. Therefore, the 50% dextrose was decreased to a rate of 10 ml per hour. The patient had no changes in mental status, but complained of increased abdominal pain, nausea, and bloating. Despite the maximum dose of Norepinephrine and Dopamine, her blood pressure still remained low. Subsequently Vasopressin and Epinephrine were added. She was given 2 amps of Sodium Bicarbonate and 100 mg intravenous Hydrocortisone. Her morning labs including serum electrolyte panel and complete blood cells count showed potassium of 2.8, creatinine of 1.68, bicarbonate of 7 with anion gap of 19, phosphorus of 1.2, glucose of 603, and white blood cells count of 30 x 10³ microliter with 79% segs and 15% bands. Therefore, she was administered 2 doses of 40 mEq potassium chloride and 1 dose of 30 mmol of potassium phosphate. She was also administered Methylene Blue and Polyethylene Glycol at a rate of 2 Liters per hour via a nasogastric tube. Additionally, she was switched to 5% dextrose in water, started on Sodium Bicarbonate at a

rate of 100 ml/hour, and started on a calcium drip. Later during the day, the patient started complaining of dyspnea and her arterial blood gas showed a pH of 7.02, PCO₂ of 21 mmHg, PO₂ of 77 mmHg, HCO₃ of 5.4 mEq/L, and oxygen saturation of 86.1%; therefore, she was subsequently intubated. Throughout the day, her glucose slowly trended down to 200's and her anion-gap slowly closed. Her kidney function also improved with an increased urine output. Her Epinephrine drip was discontinued (at 22:00) since her blood pressure gradually improved. She remained on Norepinephrine, Dopamine, and Vasopressin.

Time	Blood Pressure (mmHg)	Heart Rate (beats per minute)
14:55	114/78	86
16:00	124/83	121
16:10	105/62	100
16:20	97/51	98
16:30	103/58	88
16:45	82/48	95
16:46	80/37	90
17:03	101/57	85
18:19	112/57	85
22:30	98/33	60

Table 1: The table illustrates consecutive blood pressure and heart rate readings of the patient from the initial presentation in the ED (14:55) to 22:30. Note the rapid deterioration in both systolic and diastolic blood pressure at 16:10.

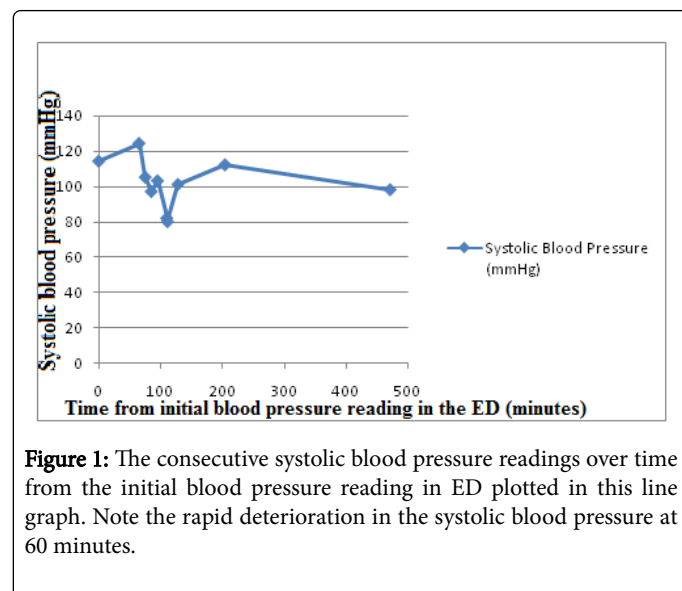


Figure 1: The consecutive systolic blood pressure readings over time from the initial blood pressure reading in ED plotted in this line graph. Note the rapid deterioration in the systolic blood pressure at 60 minutes.

On day 2, her metabolic acidosis resolved completely, creatinine level returned to her baseline, and her blood glucose level was in 100s. On day 3, she developed hyponatremia (sodium of 129) and her chest x-ray showed evidence of bilateral pleural effusion; and therefore, she was managed with Sodium Phosphate and Furosemide, respectively. Her Norepinephrine was titrated down since her blood pressure made

significant improvement. On the 4th day, her remaining Vasopressin and Dopamine were discontinued. The next day she remained stable and was transferred to the psychiatry unit.

Discussion

Intentional ingestion of CCBs can lead to significant morbidity and mortality. Therefore, the early development of signs and symptoms must be recognized and treated rapidly. Patients may present initially asymptomatic but can rapidly deteriorate. Therefore, a careful history and periodic physical examination to check for hypotension, bradycardia, pulmonary crackles, signs of heart failure and neurological symptoms should be part of the routine management. The following diagnostic tests must be obtained promptly: electrocardiogram to look for PR interval prolongation and bradydysrhythmias, finger-stick glucose monitoring to look for evidence of hyperglycemia, serum toxicology to look for co-ingestion of acetaminophen, serum electrolytes to monitor potassium, calcium and bicarbonate levels, arterial blood gas to monitor acid-base status, and chest radiograph to look for signs of pulmonary edema [3,4].

Once airway and breathing have been established and secured, intravenous (IV) fluid should be administered for hypotension and atropine should be added if the patient is bradycardic. Atropine should be administered at a dose of 0.5 to 1 mg every two to three minutes with a maximum dose of 3 mg. If the patient shows signs of altered mental status, intubation and mechanical ventilation may be required. In general, treatment approach should be guided by signs and symptoms.

It is recommended that asymptomatic patients be monitored for about 6 to 36 hours depending on the type of preparation that was ingested. Those who ingested immediate-release CCB should be monitored for 6 hours; while, those who ingested standard-release and extended-release CCBs should be monitored for 6-12 and 24-36 hours, respectively [5]. Those with mild hypotension should be initially given IV fluid and then evaluated for 15 minutes for the response. If additional therapy is needed to increase the blood pressure, following should be sequentially added until an adequate response is maintained: IV calcium salts (30 to 60 mL of 10% calcium gluconate solution or 10 to 20 mL of 10% calcium chloride solution), IV glucagon (5-10 mg), IV high-dose insulin (bolus of 1 unit/kg of regular insulin followed by an infusion of 0.5-2.0 units/kg/hr) and glucose, IV vasopressor (2 mcg/min of norepinephrine), IV lipid emulsion therapy (1-1.5 ml/kg of 20% solution) [6-8]. Severely symptomatic patients should be administered all of the following: IV fluid boluses, IV calcium salts, IV glucagon, IV high-dose insulin and glucose, IV vasopressor, IV lipid emulsion therapy [6-8]. In addition to these, gastrointestinal decontamination with orogastric lavage or activated charcoal may be administered within 1-2 hours of ingestion. In cases of massive overdose or if there is a strong suspicion of ingestion of the extended-release preparation, whole bowel irrigation with administration of polyethylene glycol/electrolyte lavage solution may be indicated [9].

High-dose insulin may be used to manage hyperglycemia that occurs due to inhibition of insulin release by the calcium channel blockade. A retrospective study involving 40 patients with nondihydropyridine overdose found that the degree of hyperglycemia correlates directly with severity of toxicity [4]. A close monitoring of glucose and potassium is recommended for patients receiving high-dose insulin therapy. Several studies have linked the high-dose insulin therapy to improved hemodynamic parameters and lower mortality

due to its positive inotropic effect in patients with CCB toxicity [6,10,11]. Studies have associated the use of lipid emulsion therapy with improved hemodynamic parameters and survival in animal models of verapamil poisoning. One of the studies measured the serum verapamil concentration before and after intralipid therapy during the management of an overdose and found a decrease in verapamil concentration once the lipid had been removed from the sample, providing evidence for the benefits of this therapy [12].

In summary we will highlight the appropriate steps in an easy to read fashion with the following:

Airway, Breathing, Circulation

Administer activated charcoal and gastric lavage

Methylene blue and whole bowel irrigation with administration of polyethylene glycol

High dose insulin therapy

Intralipid therapy

In our case we used a similar approach as mentioned above. Although Diltiazem levels were not obtained in our patient, the patient had signs and symptoms of toxicity that was consistent with a significant toxicity and the levels would not have impacted her management. In addition the aforementioned co-ingestants did not appear to contribute to her presentation and did not require any particular management, although her levothyroxine may have contributed to her delayed onset of action due to its potent sympathomimetic activity, which needed to be overcome by the CCBs. We managed our patient with IV fluids, IV calcium salts, IV high-dose insulin therapy, IV vasopressors, IV lipid emulsion therapy, and whole bowel irrigation with administration of polyethylene glycol. We used 4 different vasopressors to manage the blood pressure in our patient since despite the maximum dose of Norepinephrine and Dopamine; the blood pressure was still low. Therefore, we added Vasopressin and Epinephrine. In addition to the above-mentioned therapies, we also administered Methylene Blue in our patient. The use of Methylene Blue has been shown to be successful for refractory shock due to its ability to scavenge nitric oxide and inhibit nitric oxide synthase [13]. The earlier considerations in the management of our patients could have included activated charcoal and gastric lavage. The impact this would have had on her clinical outcome is not clear [14,15]. Although there have been many reported cases of Diltiazem toxicity, we believe that our case is unique in that our patient presented asymptomatic, rapidly deteriorated and was successfully managed despite profound circulatory shock. There is no general consensus on the optimal treatment of patients with significant CCB toxicity. Therefore, our successful management strategy should serve as a good learning experience as well as a recommendation for managing such patients.

References

1. Mowry JB, Spyker DA, Cantilena LR, McMillan N, Ford M (2014) 2013 Annual Report of the American Association of Poison Control Centers' National Poison Data System (NPDS): 31st Annual Report. *Clin Toxicol (Phila)* 52: 1032-1283.
2. Derlet RW, Horowitz BZ (1995) Cardiotoxic drugs. *Emerg Med Clin North Am* 13: 771-791.
3. Sporer KA, Khayam-Bashi H (1996) Acetaminophen and salicylate serum levels in patients with suicidal ingestion or altered mental status. *Am J Emerg Med* 14: 443.

4. Levine M, Boyer EW, Pozner CN, Geib AJ, Thomsen T, et al. (2007) Assessment of hyperglycemia after calcium channel blocker overdoses involving diltiazem or verapamil. *Crit Care Med* 35:2071.
5. Spiller HA, Meyers A, Ziemba T, Riley M (1991) Delayed onset of cardiac arrhythmias from sustained-release verapamil. *Ann Emerg Med* 20: 201-203.
6. St-Onge M, Dubé PA, Gosselin S, Guimont C, Godwin J, et al. (2014) Treatment for calcium channel blocker poisoning: a systemic review. *Clin Toxicol (Phila)* 52: 926-944.
7. Hofer CA, Smith JK, Tenholder MF (1993) Verapamil intoxication: a literature review of overdoses and discussion of therapeutic options. *Am J Med* 95: 431-438.
8. Ashraf M, Chaudhary K, Nelson J, Thompson W (1995) Massive overdose of sustained-release verapamil: a case report and review of literature. *Am J Med Sci* 310: 258-263.
9. Thanacoody R, Caravati EM, Troutman B, Höjer J, Benson B, et al. (2015) Position paper update: whole bowel irrigation for gastrointestinal decontamination of overdose patients. *Clin Toxicol (Phila)* 53: 5-12.
10. Yuan TH, Kerns WP, Tomaszewski CA, Ford MD, Kline JA (1999) Insulin glucose as adjunctive therapy for severe calcium channel antagonist poisoning. *J Tox Clin Tox* 37: 463-474.
11. Boyer EW, Shannon M (2001) Treatment of calcium-channel-blocker intoxication with insulin infusion. *N Engl J Med* 344: 1721-1722.
12. French D, Smollin C, Ruan W, Wong A, Drasner K, et al. (2011) Partition constant and volume of distribution as predictors of clinical efficacy of lipid rescue for toxicological emergencies. *Clin Toxicol (Phila)* 49: 801-809.
13. Jang DH, Nelson LS, Hoffman RS (2011) Methylene blue in the treatment of refractory shock from an amlodipine overdose. *Ann Emerg Med* 58: 565-567.
14. Chyka PA, Seger D, Krenzelok EP, Vale JA, American Academy of Clinical Toxicology and European Association of Poisons Centres and Clinical Toxicologists (2005) Position paper: Single-Dose Activated Charcoal. *Clin Toxi* 43: 61-87.
15. Benson BE, Hoppu K, Troutman WG, Bedry R, Erdman A, et al. (2013) Position paper update: gastric lavage for gastrointestinal decontamination. *Clin Toxi* 51: 140-146.