

Massive Scrotal Calcinosis: Case Report

Georges Joshué AD¹, Michaël MA¹, Malick D¹, Inès Dodji YM¹, Gilles N^{1*}, Jean S¹, Detondji FH¹, Fouad S¹, Prince Pascal H¹ and Marie-Thérèse AKPO²

¹Associate Professor of Urology, University Clinic of Urology-Andrology, CNHU-HKM Cotonou/ Republic of Benin, West Africa

²Anatomy-Pathology Professor, Department of Anatomy Pathology FSS Cotonou, Republic of Benin, West Africa

*Corresponding author: Gilles N, Urological Surgeon, University Clinic of Urology-Andrology, CNHU-HKM Cotonou/ Republic of Benin, West Africa; Tel: 229 96 16 99 19; E-mail: anagilas2000@yahoo.fr

Received date: April 21, 2017; Accepted date: May 18, 2017; Published date: May 25, 2017

Copyright: © 2017 Gilles N, et al. This is an open-access article distributed under the terms of the creative commons attribution license, which permits unrestricted use, distribution, and reproduction in any medium, provided the original author and source are credited.

Abstract

Scrotal calcinosis is a rare benign condition defined as the presence of several calcified nodules within the scrotal skin. Its pathogenesis remains largely unknown. We hereby report a case of massive scrotal calcinosis which progressively developed for 12 years with a 57-year old patient with no evidence of calcium and phosphorus metabolic disorder. It was a fortuitous finding during a consultation for complete urine retention. We shall discuss the pathological anatomy and therapeutic aspects.

Keywords Scrotal calcinosis; Scrotal plasty; Urinary drainage; Epidermoid cysts

Introduction

Scrotal calcinosis is a rare and benign pathology fall under the large group of idiopathic skin calcinosis [1]. It was first described in 1983 by Lewinsky [2]. It is characterized by the presence of multiple calcified nodules on the scrotal skin. It most commonly occurs with patients presenting no calcium and phosphorus metabolic disorders. The treatment requires surgical removal of scrotal nodules. We hereby report a case of massive scrotal calcinosis with a 57-years old patient.

Clinical Observation

Mr. D. C. aged 57 years old was admitted to intense care unit for complete urine retention. The oral questioning revealed an initial flare of small multiple pruritic scrotal swellings which gradually increased in sizes. When pressurized, they spurt out a whitish fluid crystallizing in few seconds. Physical examination carried out after urinary drainage revealed the presence of multiple whitish scrotal nodules of about 1 cm in diameter, hard, painless and movable in relation with muscle fascia (Figure 1).

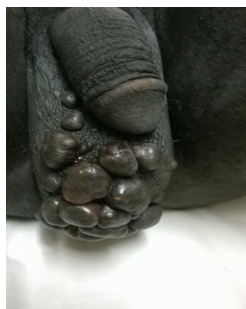

Figure 1: Scrotal nodules.

Serum Calcium and phosphorus levels were normal: serum calcium=99 mg/L, serum phosphorus=36 mg/L and alkaline phosphatase=101 IU/L. Scrotal conventional x-ray showed the presence of numerous calcium opacities at the scrotal region (Figure 2).

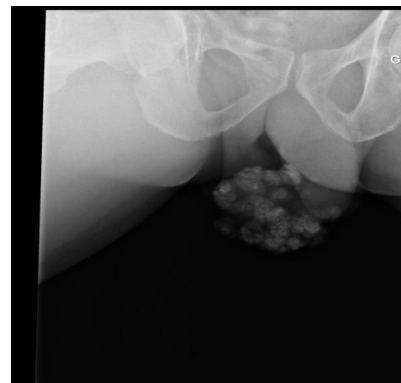


Figure 2: Opacity of the scrotal region from pelvis conventional x-ray.

Scrotal ultrasound scan revealed regular testicles and no intra vaginal effusion. Following transurethral resection of the prostate, the patient later underwent, surgical excision of the nodules with scrotal plasty. Under spinal anesthesia, an elliptical incision in the scrotum was performed. It was centered on the median raphe while wiping out all nodular lesions. A dissection of the scrotal skin which is the seat of nodules was performed using diathermy knife (Figure 3).

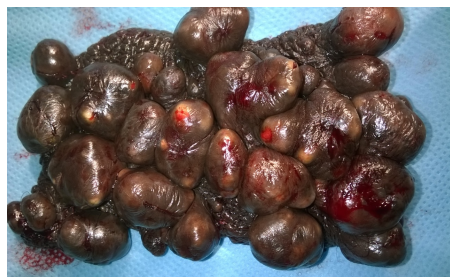

Figure 3: Resected specimen.

The closure of the scrotum is carried out using an overedge stitches of 2/0 vicryl with no scrotal drainage. Histopathological examination of the surgical specimen revealed under scrotal acanthosis the presence of intradermal calcium dystrophic lesions of varying sizes lined with epithelial and connective tissues (Figure 4).

Post-op was ordinary with healing within seven days, the patient was aesthetically satisfied and there was no relapse a year later.

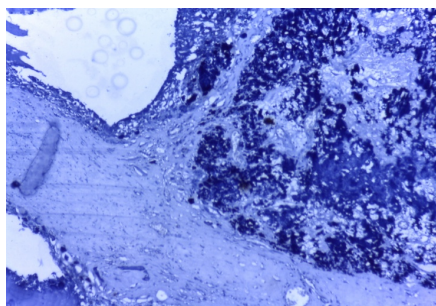


Figure 4: Intradermal calcification.

Discussion

Scrotal calcinosis is relatively young adults pathology with an age of onset between 30 and 50 years in journals [3,4]. This is a rare disease and uncommon in Africa [4] and little known by medical practitioners. Most often, it is discovered during a consultation for aesthetic discomfort, fear of scrotal cancer, or other reasons [5]. In our case, the complete urine retention was conducted upon consultation. The timeline for consultation or discovery is often long because of the benign nature of the disease [4,5]. Symptoms are often poor as reported by Paquet [6]. Scrotal calcinosis etiopathology is unknown. More often, there is no calcium and phosphorus metabolic disorder as in our case. Several theories have been developed about the origin of scrotal calcinosis, but the most likely is described by Swine heart [7]

who highlights calcification of epidermoid cysts. This theory was confirmed by others authors [8,9]. In our case, the blast of nodules spurting out a dull whitish fluid which crystallizes and the presence of epithelial tissue surrounding the calcifications confirmed this theory. In the case of our patient, we performed an excision of scrotal nodules wiping out all damaged skin without exceeding the dartos muscle. This technique allowed saving time and rapid healing with no relapse. Several techniques were described in the different studies including resection of all lesions in bloc with an elliptical excision centered on the median raphe inspired from scrotal lifting techniques described by Noel [10]. However, some authors recommend removing the nodules one after the other. This requires more time, exposes the patient to high risk of relapse [11] and unpleasant scars in case of multiple nodules. Most authors who carried out in bloc excision experienced no relapse [10,12].

Conclusions

Scrotal calcinosis is a rare and benign condition, whose most probable etiology is calcification of scrotal epidermoid cysts. Its treatment only meant for aesthetic purpose must be exclusively carried out by surgical excision limited to the skin, in bloc nodules.

References

1. Ciftci S, Simsek E, Yavuz U, Ustuner M, Ozkan I (2014) Idiopathic scrotal calcinosis in a case who presented 20 years after the initiation of symptoms: A review of the literature. *Clin Ter* 165: 239-241.
2. Lewinski HM (1883) Lymphangiome der haut mit verkalkeminhalt. *Arch Pathol Anat* 91: 371-374.
3. Salvarci A, Altinay S (2013) Relapsing idiopathic scrotal calcinosis. *J Pak Med Assoc* 63: 1433-1434.
4. Ze Ondo C, Sow Y, Diao B, Sarr A, Fall B, et al. (2014) [Scrotal calcinosis: clinical and therapeutic aspects in 5 cases]. *Prog Urol* 24: 346-348.
5. el Fassi MJ, el Ammari JE, Khallouk A, Achour Y, Tazi MF, et al. (2003) [Scrotal calcinosis]. *Prog Urol* 13: 332-333.
6. Paquet P, Devillers C, Szepetiuk G, Quatresooz P, Piérard GE (2010) [Image of the month. Idiopathic calcinosis of the scrotum]. *Rev Med Liege* 65: 113-114.
7. Swinehart JM, Golitz LE (1982) Scrotal calcinosis. Dystrophic calcification of epidermoid cysts. *Arch Dermatol* 118: 985-988.
8. Saad AGI, Zaatari GS (2001) Scrotal calcinosis: is it idiopathic? *Urology* 57: 365.
9. Doh K, Dial C, Leloua A, Gaye AM, Woto Gaye G (2015) Apport de l'histopathologie dans le diagnostic d'une calcinose scrotale: A propos d'un cas. *Afr J Urol* 21: 80-83.
10. Noel W, Hersant B, Meningaud JP (2016) [One-staged surgical technique for scrotal calcinosis]. *Prog Urol* 26: 176-180.
11. Ruiz-Genao DP, Ríos-Buceta L, Herrero L, Fraga J, Aragüés M, et al. (2002) Massive scrotal calcinosis. *Dermatol Surg* 28: 745-747.
12. Tela UM, Ibrahim MB (2012) Scrotal calcinosis: a case report and review of pathogenesis and surgical management. *Case Rep Urol* 2012: 475246.