

Metastatic Lung Cancer to the Common Bile Duct Presenting as Obstructive Jaundice

Cochrane J*

University of Washington, Spokane, Washington, USA

*Corresponding author: Justin Cochrane, University of Washington, Spokane, Washington, USA, E-mail: justincg5@yahoo.com

Received date: February 27, 2016; Accepted date: March 15, 2016; Published date: March 22, 2016

Copyright: © 2016 Cochrane J. This is an open-access article distributed under the terms of the Creative Commons Attribution License, which permits unrestricted use, distribution, and reproduction in any medium, provided the original author and source are credited.

Abstract

Context: Lung cancer is the second most common cancer amongst men and women. Metastatic spread of lung cancer usually involves adrenal glands, bone, brain, liver, and other portions of the lung. The biliary system is rarely affected by metastatic lung cancer via hematogenous spread.

Case: We present a case of 61-year old female who presented with obstructive jaundice secondary to a mass in the common bile duct near the takeoff of the cystic duct. EUS/FNA via rapid cytology identified the mass as an adenocarcinoma initially thought to be cholangiocarcinoma. However, with Immunohistochemical staining was identified as metastatic lung adenocarcinoma.

Conclusion: This case is one of three reported in the literature with direct metastasis of lung cancer to the common bile duct. Patients with obstructive jaundice secondary to CBD mass and known distant primary cancer should be considered for EUS with FNA and immunohistochemical staining to determine the underlying source of CBD mass.

Keywords: Metastatic lung cancer; Common bile duct mass

Introduction

Lung cancer is the second most common cancer among both men and women accounting for 27% of all cancer deaths [1]. Adrenal gland, bone, brain, liver, and other portions of the lung are common sites of metastatic lung cancer. Biliary involvement of lung cancer has a less than 1% incidence [2]. Involvement of the intrahepatic and extra hepatic ducts is demonstrated via several mechanisms. First is involvement of direct extension of metastatic lung cancer from the liver into the bile duct. Second is the compression or erosion of metastatic lymph nodes in the retroperitoneum or porta hepatis into the bile duct. Finally metastatic lesion in the head of the pancreas causes direct compression or extension into the distal common bile duct (CBD). A rare etiology is hematogenous metastasis to the interior lumen of the CBD. Only two cases reported in the literature of hematogenous metastatic involve the CBD lumen [2,3]. We present the third case of metastatic lung cancer to the common bile duct presenting as abdominal distention and jaundice.

Case

A 61-year-old Caucasian female presented with dry cough for 2 months, worsening shortness of breath, abdominal pain, distention, and jaundice. Prior to admission a chest computer tomography (CT) demonstrated a right upper lobe nodule measuring 2.6 cm × 2 cm, right pleural effusion, and lymphadenopathy in the right paratracheal, superior mediastinum, subcarinal and hilar areas (Figure 1). Cytology from the thoracentesis of the right pleural effusion demonstrated cells suspicious for adenocarcinoma with confirmation of primary lung

adenocarcinoma through immunohistochemical staining positive for cytokeratin, Napsin A and thyroid transcription factor (TTF-1).

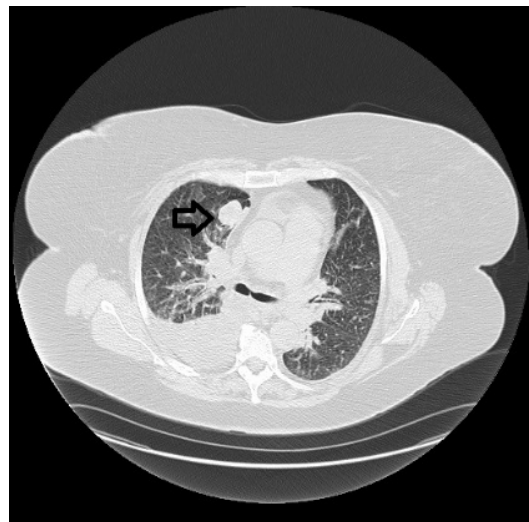


Figure 1: Lung nodule and right pleural effusion on CT chest prior to admission.

On admission she described her abdominal pain as fullness with a constant pressure throughout her abdomen. She stated that this made her breathing worse over the past couple of weeks. Physical exam demonstrated scleral icterus bilaterally, coarse breath sounds bilaterally in all lung fields, and abdominal distention with no visible fluid wave. Her liver enzymes were ALP 726 U/L, ALT 165 U/L, AST 135 U/L, and

total bilirubin 11.6 mg/dL. Cancer antigen 19-9 of 5073 U/mL. CBC and BMP were normal. Magnetic Resonance Cholangiopancreatography (MRCP) demonstrated a dilated CBD measuring 0.9 cm with narrowing of the CBD at the pancreatic head (Figure 2).

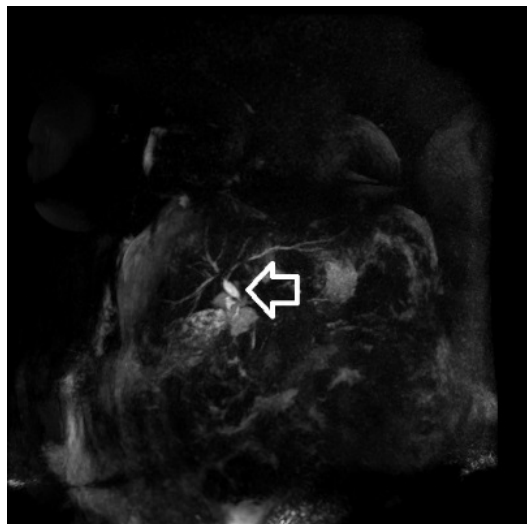


Figure 2: MRCP demonstrating CBD dilation in coronal view.

Due to narrowing of the CBD, an endoscopic ultra sound (EUS) was undertaken for evaluation of the obstruction of the CBD. EUS identified a thickened CBD measuring 7.1 mm with a lumen diameter of 1.6 mm and a hypochoic mass of 15.8 mm × 11.3 mm near the takeoff of the cystic duct (Figure 3). EUS also demonstrated multiple areas of lymphadenopathy: peripancreatic 10.8 mm × 6.5 mm and 10.6 mm × 3.8 mm, perigastric 6.3 mm × 3.3 mm and 6.5 mm × 4.7 mm, celiac axis 11.6 mm × 7.4 mm.

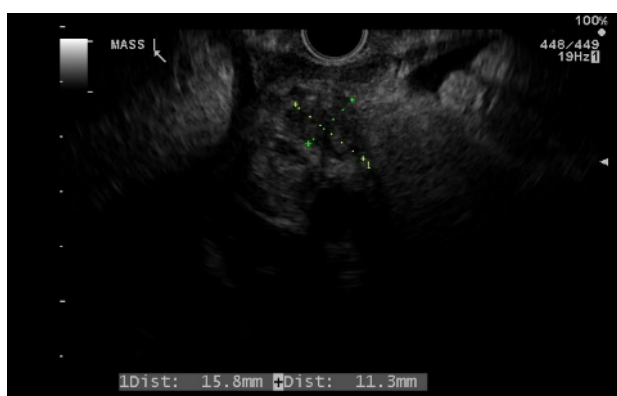


Figure 3: EUS demonstrating mass in the CBD adjacent to cyst duct take off measuring 15.8 mm × 11.3 mm.

No lymph nodes were in direct contact with the biliary system. Fine needle aspiration was undertaken for cytology and cellblock of the CBD mass. Rapid cytology demonstrated adenocarcinoma. Endoscopic Retrograde Cholangiopancreatography (ERCP) demonstrated a long stricture of the entire CBD and 10 mm × 60 mm

uncovered self-expanding metal stent was placed across the obstruction with good biliary drainage noted after placement (Figure 4). Final pathology and immunohistochemical staining revealed cytokeratin and TTF-1 confirming a metastatic lung adenocarcinoma into the CBD.

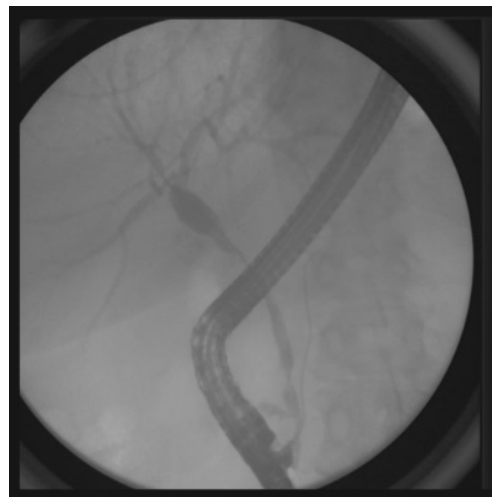


Figure 4: ERCP demonstrating stricture in the CBD.

Discussion

Malignant masses associated with CBD are most commonly cholangiocarcinoma which accounts for 2% of all cancers [4]. Primary cancer rarely metastasizes to the CBD but when this occurs, hepatocellular carcinoma, colon cancer, and breast are the most common primary sites. Metastatic lung cancer to the CBD has a less than 1% incidence with the majority of cases reported being small cell lung cancer [5-9]. Only two cases of primary lung adenocarcinoma with hematogenous metastasis to the CBD are described in the literature [2,3]. To our knowledge this is only the third reported case of lung adenocarcinoma metastasizing to the bile duct with subsequent development of obstructive jaundice.

Our diagnosis was made via FNA of the CBD mass via a 19-gauge core needle with EUS. Histopathology revealed adenocarcinoma and in association elevated CA 19-9 greater than 129 U/ml, carried 98% specificity for cholangiocarcinoma [4]. Therefore the initial diagnosis was believed to be a double primary cancer; lung adenocarcinoma and cholangiocarcinoma. However, given that our patient had a known lung adenocarcinoma with metastatic involvement of the pleural space, immunohistochemical staining was undertaken to determine the true etiology of the CBD mass before definitive treatment was decided upon.

The difficulty in making a diagnosis from hematoxylin-eosin staining alone arises from the fact that cholangiocarcinoma derives from epithelial lining in the biliary tract and 95% are adenocarcinoma in origin [1,4]. Immunohistochemical staining allows for further clarification between primary and metastatic adenocarcinoma by identifying specific features of primary lung adenocarcinoma. Several immunohistochemical stains are available to determine primary adenocarcinoma of lung origin such as; cytokerin, Napsin A, and TTF-1. TTF-1 is a nuclear protein that plays a role in transcriptional

activation during embryogenesis in the respiratory epithelium [3]. Roh et al. [10] demonstrated that TTF-1 has a specificity of 95% for metastatic lung cancer. By utilizing specific immunochemical stains, such as TTF-1, we were able to determine that in fact this CBD mass was not a primary cholangiocarcinoma but a metastatic lesion from primary lung adenocarcinoma. By establishing this diagnosis we were able to tailor a palliative chemotherapy treatment program in association with palliative stenting of the CBD with an uncovered self-expanding metal stent; thus giving the patient the best quality of life with minimal intervention.

Patients with a known primary adenocarcinoma who present with obstructive jaundice from a CBD mass need EUS with FNA and immunohistochemical staining to determine the underlying etiology. Differentiating between double primary cancer and lung adenocarcinoma metastasis to the CBD is imperative to provide patients with the least invasive therapy possible.

References

1. <http://www.cancer.org/cancer/lungcancer-non-smallcell/detailedguide/non-small-cell-lung-cancer-key-statistics>.
2. Ochi N, Goto D, Yamane H, Yamagishi T, Honda Y, et al. (2014) Obstructive jaundice caused by intraductal metastasis of lung adenocarcinoma. *Onco Targets Ther* 7: 1847-1850.
3. Cha IH, Kim JN, Kim YS, Ryu SH, Moon JS, et al. (2013) Metastatic common bile duct cancer from pulmonary adenocarcinoma presenting as obstructive jaundice. *Korean J Gastroenterol* 61: 50-53.
4. Hennedige TP, Neo WT, Venkatesh SK (2014) Imaging of malignancies of the biliary tract- an update. *Cancer Imaging* 14: 14.
5. Jeon WJ, Chae HB, Park SM, Youn SJ, Choi JW, et al. (2006) A case of primary small cell carcinoma arising from the common bile duct. *Korean J Gastroenterol* 48: 438-442.
6. Liratzopoulos N, Efremidou EI, Papageorgiou MS, Romanidis K, Minopoulos GJ, et al. (2006) Extrahepatic biliary obstruction due to a solitary pancreatic metastasis of squamous cell lung carcinoma. *J Gastrointest Liver Dis* 15: 73-75.
7. Kim JH, Lee SH, Park J, Kim HY, Lee SI, et al. (2004) Extrapulmonary small-cell carcinoma: a single-institution experience. *Jpn J Clin Oncol* 34: 250-254.
8. Kuraoka K, Taniyama K, Fujitaka T, Nakatsuka H, Nakayama H, et al. (2003) Small cell carcinoma of the extrahepatic bile duct: case report and immunohistochemical analysis. *Pathol Int* 53: 887-891.
9. Sonoda Y, Yamaguchi K, Nagai E, Nakamura M, Ito T, et al. (2003) Small cell carcinoma of the cystic duct: a case report. *J Gastrointest Surg* 7: 631-634.
10. Roh MS, Hong SH (2002) Utility of thyroid transcription factor-1 and cytokeratin 20 in identifying the origin of metastatic carcinomas of cervical lymph nodes. *J Korean Med Sci* 17: 512-517.