

## *Monascus ruber*: A Rare Cause of Onychomycosis

Dabet Rynga<sup>1,2</sup>, Malini R Capoor<sup>\*1</sup>, Swati Varshney<sup>1</sup> and Ramesh V<sup>1</sup>

<sup>1</sup>Department of Microbiology, Vardhman Mahavir Medical College and Safdarjung Hospital, New Delhi, India

<sup>2</sup>Department of Microbiology, North Eastern Institute of Ayurveda and Homoeopathy, Shillong, Meghalaya, India

\*Corresponding author: Malini R Capoor, Professor, Department of Microbiology, Vardhman Mahavir Medical College & Safdarjung Hospital, New Delhi -110029, India, Tel: +919891459717; E-mail: [rajeevmalini@rediffmail.com](mailto:rajeevmalini@rediffmail.com)

Received date: October 28, 2016, Accepted date: November 21, 2016, Published date: November 30, 2016

Copyright: © 2016 Rynga D, et al. This is an open-access article distributed under the terms of the Creative Commons Attribution License, which permits unrestricted use, distribution, and reproduction in any medium, provided the original author and source are credited.

### Abstract

We report a case of onychomycosis from a 71-year old man which was caused by *Monascus ruber*. The diagnosis was based on culture morphological characteristics on Sabouraud's Dextrose agar and Malt Extract agar. The patient was successfully treated with oral terbinafine.

**Keywords:** *Monascus ruber*; Onychomycosis; Terbinafine

### Introduction

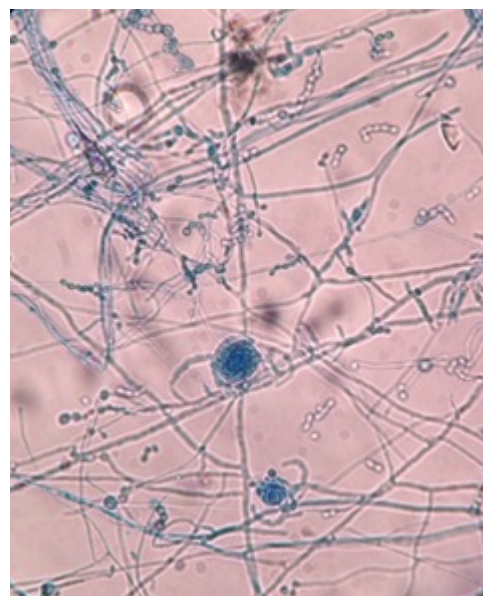
Onychomycosis, traditionally referred to as non-dermatophytic infection of the nail, is now used as a general term to denote any fungal infection of the nail. The causative pathogens of onychomycosis include dermatophytes, *Candida* and non-dermatophytic molds. Of these, dermatophytes are more common in the temperate western countries while *Candida* and non-dermatophytic molds in the hot and humid tropical and subtropical regions [1].

This difficult-to-treat infection not only serves as a constant reminder to the patient of his or her morbid condition, but also poses the possibility to transfer the fungal infection to other persons. Although dermatophytic infections are rarely life-threatening, their high incidence, prevalence and associated morbidity make them a huge public health problem. Furthermore among immunocompromised patients, onychomycosis can become a serious health problem [2].

A wide variety of non-dermatophyte fungi (molds and yeast-like) cause nail infections, especially after tissue damage due to trauma or any disease causing nail dystrophy. Among the non-dermatophyte molds the common causative organisms are *Fusarium*, *Paecilomyces*, *Penicillium*, *Scapularopsis*, *Aspergillus* etc. *Monascus ruber* is a filamentous fungi (family Monascaceae, order Eurotiales) and it is a rare cause of non-dermatophytic onychomycosis [2-5]. Here we report one case of onychomycosis due to *M. ruber*.

### Case report

A 71-year-old male, resident of Gurugram in Haryana, India, presented at the Dermatology Out-Patient Department (OPD) of a tertiary hospital with discolouration of his nails. On examination, all his nails were greyish purple in colour. He had no history of nail trauma, diabetes, long term use of steroids, or any other underlying disease.



**Figure 1:** LCB mount of *Monascus ruber* showing numerous round, thin walled ascocarps and chains of conidia.

After cleaning the nails with 70% alcohol, multiple specimens were collected from the left middle finger nail and the left toe nail. The samples were then transported to the laboratory in sterile black paper. Direct examination of the nail samples in 40% potassium hydroxide (KOH) showed chains of truncated conidia, but no ascocarps. As per Walsh and English criteria, [5] the nail clippings were inoculated into two sets of Sabouraud's Dextrose Agar (SDA) (Hi-Media Laboratories, Mumbai, India), one with antibacterial (chloramphenicol 50 µg/L and gentamicin 50 µg/L) and the other with cycloheximide (500 µg/L) respectively. They were then incubated at room temperature (25°C) and at 37°C. After four days of incubation, the SDA with the antibacterial showed flat, spreading mold, with thinly floccose texture, reddish grey to purple colour at both the temperatures. A slide culture was also made on malt extract agar (MEA) (Hi-Media Laboratories, Mumbai, India) and the lacto phenol cotton blue (LCB) mount showed

numerous round, thin walled ascocarps and chains of conidia. Round and thin-walled ascocarps were seen to be produced on short stalk-like hyphae along with occasional mature ascocarps packed with the loose ascocarps (Figure 1).

Based on the culture morphological characteristics on MEA, the isolate was identified as *M. ruber*. Repeated examination of the nail samples after a week revealed thin hyphae and duplicate sets of SDA yielded *M. ruber*. The isolate was also reconfirmed at National Culture Collection of Medically Important Fungi at Post graduate Institute of Medical Education and Research, Chandigarh, India.

The patient was put on oral terbinafine 250 mg once a day and after four months of treatment, complete improvement was observed and there was no adverse effect from the drug.

## Discussion

Most of the non-dermatophyte molds including *M. ruber*, are present in the environment and therefore care must be taken in interpreting culture of infected material [3-5]. In Asia, this fungus is used as a food colorant, a flavouring agent and an additive for preserving fish and meat. It was also traditionally used to produce *Monascus* fermented rice. Industrially, *Monascus* species is an important source of bioactive compounds like monacolin K, which is a very effective hypocholesterolemic agent. However, a toxic drug interaction has been reported between cyclosporine and monacolin K of the red yeast rice (*Monascus purpureus*) that led to rhabdomyolysis in a renal transplant recipient [6-10]. Some *Monascus* compounds such as citrinin have been reported to be nephron-hepatotoxic [8].

*M. ruber* is a rare cause of human infection. It is known to cause gastric infection that is associated with the consumption of contaminated dried and salted fish as *M. ruber* is sodium chloride tolerant [6,7]. It has also been reported to cause allergy and anaphylaxis in response to red yeast rice which is due to an immediate sensitivity to *Monascus purpureus* [9]. Another study described a direct renal infection due to *M. ruber* after surgery in a 70-year-old patient with multiple kidney stones [4].

However, our report is the first worldwide description of *M. ruber* causing onychomycosis. This non-dermatophyte mold was confirmed

to be the cause of the nail infection by its repeated isolation and by the correlation between direct microscopy and culture, as observed in this case.

In conclusion, *M. ruber* is an emerging cause of onychomycosis in elderly patients. The report of its isolation from another elderly male with renal infection also reveals its predisposition to the geriatric population [4]. This study has shown that the prevalence of onychomycosis increases with age, which may be due to factors like immunodeficiency, long exposure to the pathogenic fungi, inability to cut the toenails/fingernails or to maintain good foot care. The patient reported in this study was an elderly male in whom either one or all of these factors may have contributed to the pathogenic role of *M. ruber*.

## References

1. Westerberg DP, Voyack MJ (2013) Onychomycosis: Current Trends in Diagnosis and Management. Am Fam Physician 88: 762-770.
2. Winn WC (1996) Mycotic diseases: Clinical diagnosis and management, WB Saunders Company, Philadelphia.
3. Young EM (1930) Physiological studies in relation to the taxonomy of *Monascus* spp.: Transactions of the Wisconsin Academy of sciences, Arts and Letters, Wisconsin Academy of Sciences, Madison.
4. Sigler L, Kibsey PC, Sutton DA, Abbott SP, Zilkie E, et al. (1999) *Monascus ruber*, causing renal infection: Abstracts of 99th Gen. Meet. American Society for Microbiology.
5. Gupta AK, Ryder JE, Baran R, Summerbell RC (2003) Non-dermatophyte onychomycosis. Dermatol Clin 21: 257-268.
6. Lin YL, Wang TH, Lee MH, Su NW (2008) Biologically active components and neutraceuticals in the *Monascus*-fermented rice: a review. Appl Microbiol Biotechnol 77: 965-973.
7. Endo A, Monacolin K (1979) A new hypocholesterolemic agent produced by a *Monascus* species. J Antibiot 32: 852-854.
8. Hipler UC, Alberti W, Bauer A, Slsner P (2002) Case report. *Monascus purpureus*- a new fungus of allergologic relevance. Mycoses 45: 58-60.
9. Rebeiro SM, Chagas GM, Campello AP, Kluppel ML (1997) Mechanism of citrinin-induced dysfunction of mitochondria. Effect on the homeostasis of the reactive oxygen species. Cell Biochem Funct 15: 203-209.
10. Prasad GV, Wong T, Meliton G, Bhaloo S (2002) Rhabdomyolysis due to red yeast rice (*Monascus purpureus*) in a renal transplant recipient. Transplantation 74: 1200-1211.