

MRI for Suspected Appendicitis in Pregnancy

Chi Hui Wang¹, Ya Ru Hsieh² and Yu Ting Kuo^{1*}

¹Radiologist, Chi Mei Medical Center, Radiology, Tainan, Taiwan

²Department of Medical Imaging and Radiological Sciences, Department of Medical Research, Kaohsiung Medical University Hospital, Kaohsiung, Taiwan

*Corresponding author: Yu Ting Kuo, PhD, Radiologist, Chi Mei Medical Center, Radiology, 5 LN269 Dong-Men Rd Sec 2, Tainan, 70164, Taiwan, Tel: +88662004470, E-mail: lulu890838@yahoo.com.tw

Received date: Aug 16, 2017; Accepted date: Sep 11, 2017; Published date: Sep 18, 2017

Copyright: © 2017 Wang CH, et al. This is an open-access article distributed under the terms of the Creative Commons Attribution License, which permits unrestricted use, distribution, and reproduction in any medium, provided the original author and source are credited.

Abstract

Aim: Acute appendicitis is the most common disease in pregnant women. Based on the premise of the protection of fetus, diagnosis sometimes would be difficult. The purpose of this study is to evaluate the risk and benefit of magnetic resonance imaging for suspected acute appendicitis in Pregnancy.

Method: From Oct 2015 to Apr 2017, 10 pregnant women came to our emergency department because of suspected acute appendicitis. We bring MRI to participate the diagnosis in case ultrasound is insufficient to make accurate detection.

Result: 5 cases with nonvisualization of appendicitis and 5 cases were confirmed acute appendicitis. Ultrasound of these women couldn't clearly show the abnormal anatomy. But with non-radiation MRI acute appendicitis with presence of appendicoliths were identified.

Conclusion: The use of MRI in pregnant women with suspected acute appendicitis is meaningful, not only in confirmation or exclusion of appendicitis but also alternative non-radiation diagnosis tool for further treatment.

Keywords: Magnetic resonance imaging; Appendicitis; Pregnancy

Introduction

Aim and objective

Acute appendicitis is one of the most common diseases of abdomen pain [1]. It reveals the inflammation of appendix. The real reason causing this phenomenon is still unknown. Clinic diagnosis usually depends on physical examination and medical image such as ultrasound and computer tomography. However, pregnant women with suspected appendicitis are more difficult to diagnose because obstetric symptoms are similar to those of appendicitis, and computer tomography is not an appropriate tool because of the risk of radiation. The literature indicates the rate of non-detected acute appendicitis on ultrasound imaging is 68%-97% [2-4]. For pregnant women it's about 64% [5,6]. Magnetic resonance imaging (MRI) is introduced to the process of clinic evaluation. The characteristic of non-radiation makes it possible to replace the role of computer tomography. Another advantage of MRI is to provide better anatomical information. Because of motion artifacts of uncontrolled fetus and limited breath holding, the choice of pulse sequences to reduce this intervention is important on MRI. We aim to take MRI as one important indicator in diagnosing the condition of pregnant women with unsure ultrasound findings.

Materials and methods

From October 2015 to Apr 2017, there were 10 pregnant women with suspected acute appendicitis. Since Appendix cannot be clearly identified with ultrasound, further survey with MRI was recommended. Their average age is 33.7 year old, distributed at 29 29

40 28 40 28 33 39 33 38. Two patients were in the first trimester, four patients were in the second trimester, and four patients were in the third trimester. All had ultrasound examination before MRI. We use Siemens Aera 1.5Tesla MRI equipment with 18-channel design body coil. The sequences include True FISP coronal and sagittal with/without fat-saturated, Haste T2-weighted with/without fat-saturated axial and coronal images and Axial T2 images (Table 1). To avoid uncomfortable reaction of patients, scan time was controlled in less than 10 minutes.

Parameters	Coronal truefisp	Coronal truefisp fat sat	Sagittal truefisp fs	Coronal T2 haste fat sat	Axial T2 haste fat sat	Axial T2
TR (msec)	4.66	4.66	4.66	1500	1500	2430
TE (msec)	1.83	1.83	1.83	96	96	80
Bandwidth (Hz/Px)	303	303	303	355	355	501
FOV (mm)	380	380	380	380	360	350
Thickness (mm)	5	5	5	5	5	5
Gap (mm)	0	0	0	0	0	0
Matrix	269 × 384	269 × 384	269 × 384	224 × 320	224 × 320	269 × 384
Flip angle (kHz) ^b	80	80	80	150	150	120

Table 1: Parameters of MRI sequences.

Results

Ten pregnant women underwent MRI examination because of RLQ flank pain. Five were diagnosed with acute appendicitis, one was diagnosed with intraperitoneal hemorrhage. Patients' data are summarized in Table 2. Among five patients with positive MRI findings of acute appendicitis, four were accepted appendectomy and the other one was recommended following in out-patient department. One patient who was diagnosed with intraperitoneal hemorrhage accepted salpingectomy.

Age/ Trimester	Ultrasound Indication	MR finding	Treatment
29/1	R/O appendicitis	none	No treatment
29/2	R/O appendicitis	appendicitis, appendicoliths	s/p appendectomy
40/1	R/O appendicitis	Intraperitoneal hemorrhage	s/p salpingectomy
28/2	R/O appendicitis	none	No treatment
40/3	R/O appendicitis	appendicitis	s/p appendectomy
28/2	R/O appendicitis	none	No treatment
33/2	R/O appendicitis	none	No treatment
39/3	R/O appendicitis	appendicitis	s/p appendectomy
33/3	R/O appendicitis	appendicitis	OPD follow up
38/3	R/O appendicitis	appendicitis	s/p appendectomy

Table 2: MRI findings and clinical treatment of ten patients.

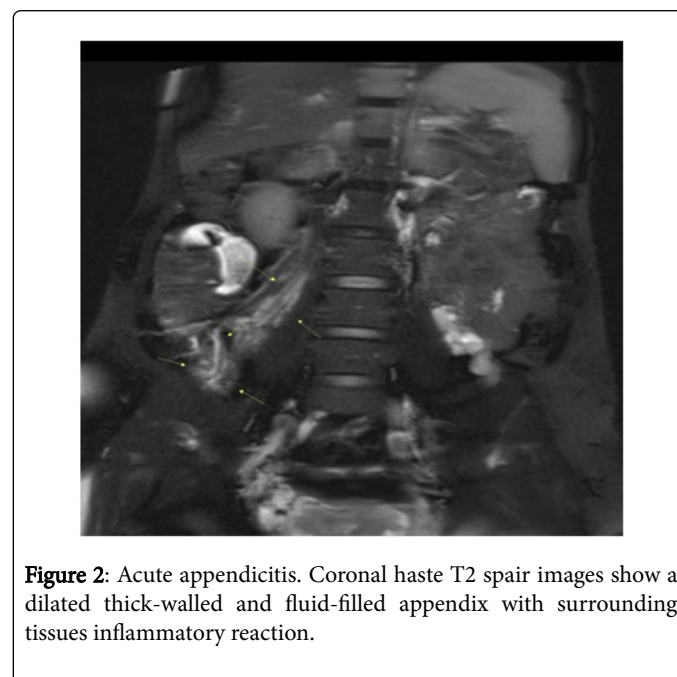
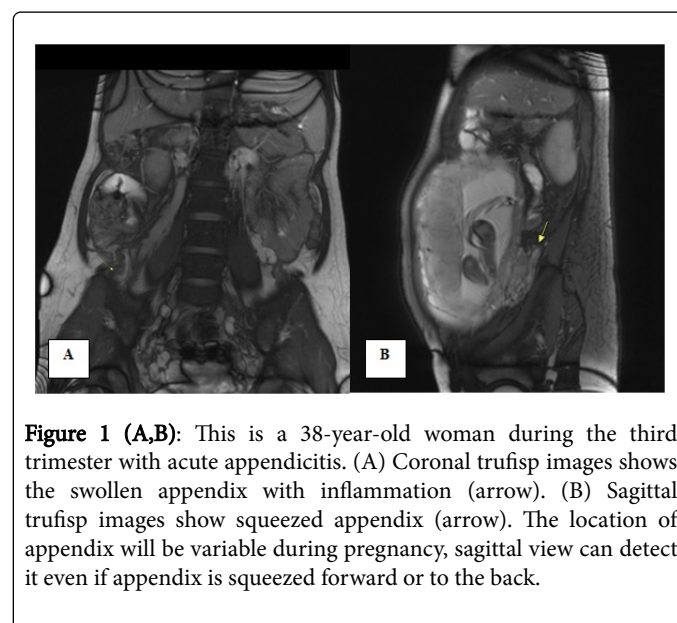
The sensitivity for diagnosed acute appendicitis by MRI was 80% (4 of 5 cases, the other one without medical treatment), compared with 40% of ultrasound. These three cases were confirmed at surgery. The specificity was 100% because 4 cases that had negative MRI findings were discharged from hospital and no other sign of appendicitis.

Discussion

In general, acute appendicitis is the most common reason of right flank pain for pregnant women. Since it's of high fatality, early diagnosis and treatment are important. However, accurate diagnosis is challenging because of accompanying obstetric symptoms. As pregnancy progresses, uterus will enlarge and the location of appendix will have some variation. The symptoms like nausea, vomiting are not unusual in gestation period. Medical imaging can provide useful information to confirm patient's condition. Ultrasound is usually the first step of image modalities. However, ultrasound highly depends on operators' experience, and will be interfered by intestinal gas and enlarged uterus [7-9]. Computer tomography will not be taken into consideration because of radiation exposure, although present guidelines ensure fetal safety with exposure dose less than 5 rads [10,11].

On MRI, the appendix is a blind-ending tubular structure and about 9-10 cm in length [12,13]. The diameter of normal appendix should be less than 7 mm with wall thickness less than 2 mm [14]. True FISP

sequence is less sensitive to the motion artifact, and it can rapidly have morphological images. Coronal True FISP detect intraperitoneal inflammation (Figure 1), and sagittal True FISP images helps tracing the direction of the intestines. The inflamed appendix has thickened wall and alter signal characteristic with increased signal intensity on T2-weighted imaging (Figure 2 and 3) [15]. To date, there is no biological evidence showing that MRI is harmful for the fetus [16,17]. But we still need to reduce the time period in the MRI examination because of noise stimulation and potential heat. In our study, the sensitivity and specificity of MRI for acute appendicitis was 80% and 100% respectively.



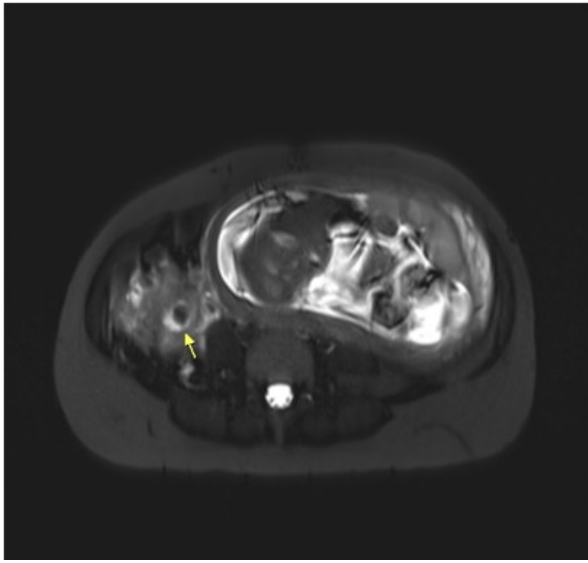


Figure 3: A 29-year-old woman with right lower quadrant pain during 27th week of pregnancy. Axial T2 haste images show acute appendicitis with presence of appendicoliths, pericecal fluid collection (arrow).

We also found that 4 of 5 patients with positive findings are older than 35 years old, so the pregnant age probably could be one risk factor of acute appendicitis. Due to the limited number of cases, more cases are needed to establish credibility.

Conclusion

In our study, MRI becomes the recommended image modality for pregnant women with suspected acute appendicitis, better morphological resolution and no radiation are the main advantages. Variable anatomic location of the appendix can be better detected in MRI with three plane images. We chose rapid and less sensitive motion sequences to execute the examination. The results reveal that MRI provides valuable information in pregnant patients with acute appendicitis.

References

1. Babaknia A, Parsa H, Woodruff JD (1977) Appendicitis during pregnancy. *Obstet Gynecol* 50: 40-44.
2. Israel GM, Malguria N, McCarthy S, Copel J, Weinreb J (2008) MRI vs ultrasound for suspected appendicitis during pregnancy. *J Magn Reson Imaging* 28: 428-438.
3. Lehnert BE, Gross JA, Linnau KF, Moshiri M (2012) Utility of ultrasound for evaluating the appendix during the second and third trimester of pregnancy. *Emerg Radiol* 19: 293-299.
4. Vu L, Ambrose D, Vos P, Tiwari P, Rosengarten M, et al. (2009) Evaluation of MRI for the diagnosis of appendicitis during pregnancy when ultrasound is inconclusive. *J Surg Res* 156: 145-149.
5. Tamir IL, Bongard FS, Klein SR (1990) Acute appendicitis in the pregnant patient. *Am J Surg* 160: 571-575.
6. Mazze RI, Kallen B (1991) Appendectomy during pregnancy: A Swedish registry study of 778 cases. *Obstet Gynecol* 77: 835-840.
7. Cunningham FG, McCubbin JH (1975) Appendicitis during pregnancy. *Obstet Gynecol* 45: 415-420.
8. Anderson B, Nielsen TF (1999) Appendicitis in pregnancy: Diagnosis, management and complications. *Acta Obstet Gynecol Scand* 78: 758-762.
9. Maslovitz S, Gutman G, Lessing JB, Kupdermine MJ, Gamzu R (2003) *Gynecology Obstet Invest* 56: 188-191.
10. (2004) ACOG Committee Opinion. Guidelines for diagnostic imaging during pregnancy. *Obstet Gynecol* 104: 647-651.
11. Hurwitz LM, Yoshizumi T, Reiman RE, Goodman PC, Paulson EK, et al. (2006) Radiation dose to the fetus from body MDCT during early gestation. *AJR Am J Roentgenol* 186: 871-876.
12. Deshmukh S, Verde F, Johnson PT, Fishman EK, Macura KJ (2014) Anatomical variants and pathologies of the vermiform appendix. *Emerg Radiol* 21: 543-552.
13. Birnbaum BA, Wilson SR (2000) Appendicitis at the millennium. *Radiology* 215: 337-348.
14. Dewhurst C, Beddy P, Pedrosa I (2013) MRI evaluation of acute appendicitis in pregnancy. *J Magn Reson Imaging* 37: 566-575.
15. Meesa IR, Mammen L (2016) MR imaging of pregnant women with abdominal pain and suspected appendicitis: Diagnostic accuracy and outcomes. *Int J Radiat Oncol* 2: 4-7.
16. Nagayama M, Watanabe Y, Okumura A, Amoh Y, Nakashita S, et al. (2002) Fast MR imaging in obstetrics. *RadioGraphics* 22: 563-582.
17. Jung SE, Byun JY, Lee JM, Rha SE, Kim H, et al. (2001) MR imaging of maternal diseases in pregnancy. *AJR Am J Roentgenol* 177: 1293-1300.