

## Multifocal Electroretinogram and Fundus Autofluorescence Findings in Acute Zonal Occult Outer Retinopathy during a Three- Year Follow-Up

Juárez Domínguez Brenda Yazmín\*, Vargas Riaño Carlos Rafael, Peñaranda Henao Carlos Felipe, Arriola-Lopez Andrea E and Jimenez- Sierra Juan Manuel

Servicio de Retina, Asociación Para Evitar la Ceguera en México, Institución de Asistencia Privada, Hospital "Dr. Luis Sánchez Bulnes", Vicente García Torres 46, Colonia Barrio San Lucas, Delegación Coyoacán, Ciudad de México, Mexico

\*Corresponding author: Juárez Domínguez Brenda Yazmín, Servicio de Retina, Asociación Para Evitar la Ceguera en México, Institución de Asistencia Privada, Hospital "Dr. Luis Sánchez Bulnes", Vicente García Torres 46, Colonia Barrio San Lucas, Delegación Coyoacán, Ciudad de México, Mexico, Tel: +52 (55) 1084 1400; E-mail: [brenda\\_yjd@hotmail.com](mailto:brenda_yjd@hotmail.com)

Received date: August 31, 2016; Accepted date: December 28, 2016; Published date: December 30, 2016

Copyright: ©2016 Yazmín JDB, et al. This is an open-access article distributed under the terms of the Creative Commons Attribution License, which permits unrestricted use, distribution, and reproduction in any medium, provided the original author and source are credited.

### Abstract

Acute zonal occult outer retinopathy is a disease difficult to diagnose. Within this pathology, many clinical and para-clinical tests appear normal regardless the great advances in technology. However, the findings we discovered with electrophysiology when paired with a thorough clinical anamnesis are the more reliable parameters for giving the right diagnosis.

We present a clinical case of a 26 year old patient with diagnosis of acute zonal occult outer retinopathy whose optical coherence tomography and fluorescein angiography results were normal while the results of the wide field electroretinogram and multifocal electroretinogram showed alterations in the outermost layers of the retina which correlated with inferior arcuate defect in the visual field and peri-macular areas of hyperautofluorescence in the autofluorescence. The evolution of the case is shown during 3 years appreciating the disappearance of the autofluorescence as well as progressive improvement in the visual field.

**Keywords:** Acute zonal occult outer retinopathy; Autofluorescence; Electroretinogram

### Introduction

AZOOR is clinically characterized by a loss of function of one part or a great part of the outermost layer of the retina, initially without any visible changes in funduscopy, electroretinographic changes or varying alterations in the visual field. Progressively, the patient may experience some retinal pigment epithelium (RPE) atrophy or thinning of the retinal blood vessels. If these changes occur, one assumes there are alterations of the photoreceptors and the retinal pigment epithelium.

There are multiple theories regarding its physiopathology, from autoimmune to infectious ones that seek to explain the alterations of the outermost layers of the retina that is most commonly evidenced in young women. These changes can be unilateral or bilateral and patients may experience an abrupt initial loss of vision within the visual field and photopsia that correspond to this area.

In this article, we place importance on the electrophysiological methods that are used to diagnose this pathology, taking into account that in many occasions the OCT and FA results come back normal.

### Case Study

Male, twenty-six year old patient, residing in Mexico City, goes for a check-up due to a sudden inferior arcuate scotoma in his left eye that showed photopsia in the affected area of the scotoma and which was heightened in places with more lighting and was almost indiscernible in places with dim light.

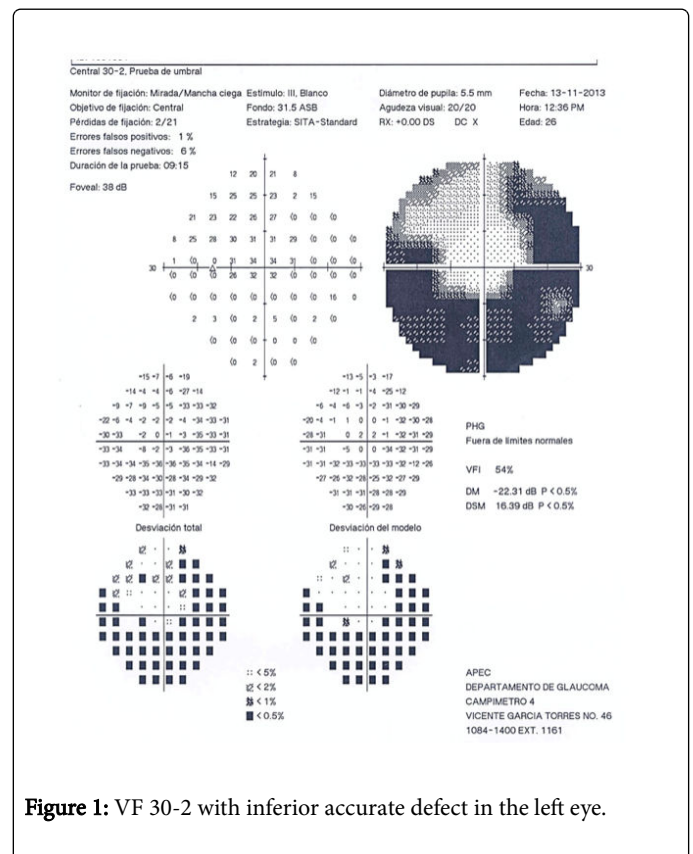
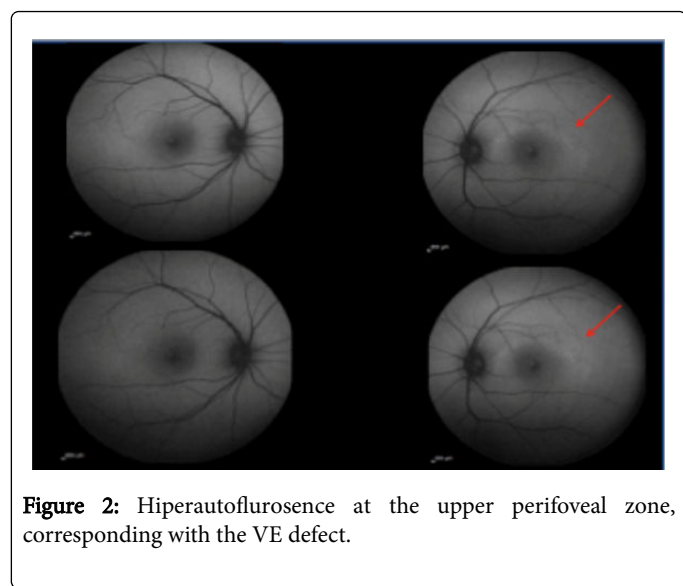


Figure 1: VF 30-2 with inferior arcuate defect in the left eye.

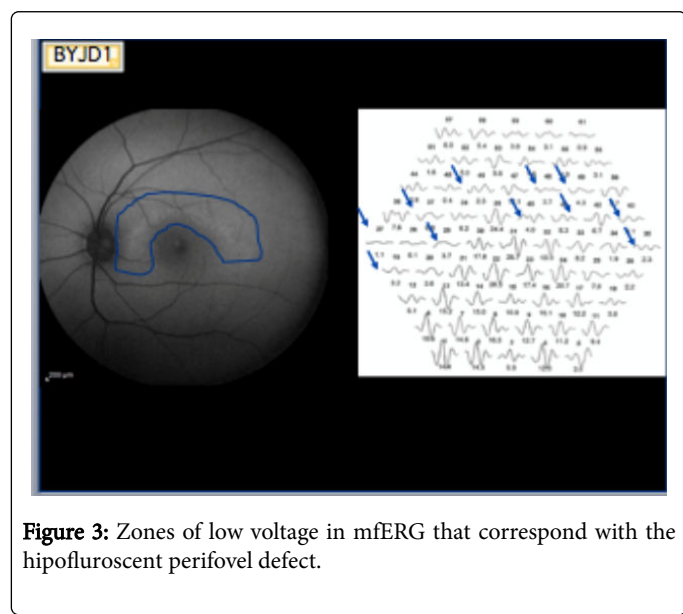
In the ophthalmologic exam the patient showed 20/20 visual acuity in both eyes without any visible alterations in the anterior segment with both the vitreous and the retina appearing normal. The visual field (30-2) corroborated the inferior arcuate defect reported by the patient that did not affect the fixation point (Figure 1). An angiography with Fluorescein as well as with Indocyanine Green was carried out and the results were normal. An fMRI, functional magnetic resonance imaging was also done and showed normal results.

Autofluorescence shows areas of peri-macular hyperautofluorescence that correspond perfectly with the arcuate defect in the visual field (Figure 2).



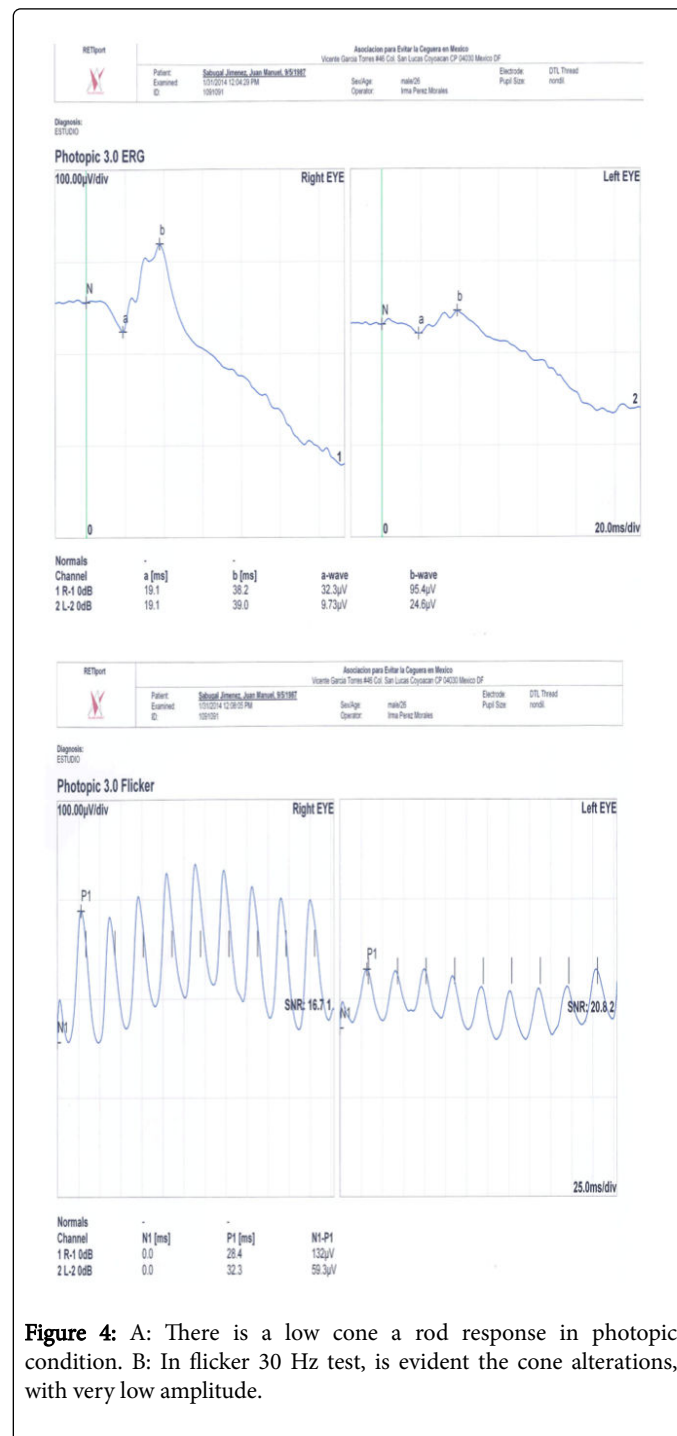
**Figure 2:** Hiperautofluorescence at the upper perifoveal zone, corresponding with the VE defect.

In addition, the standard ERG exam and the 30-Hz flicker stimulus (Figure 3) show diminished scotopic vision and abnormal photopic vision. Interestingly enough, the multifocal ERG results show an area with low voltage responses that correspond to the macular region that showed up in the autofluorescence results described above as an hyperautofluorescence zone (Figures 3 and 4).



**Figure 3:** Zones of low voltage in mfERG that correspond with the hipofluorescent perifoveal defect.

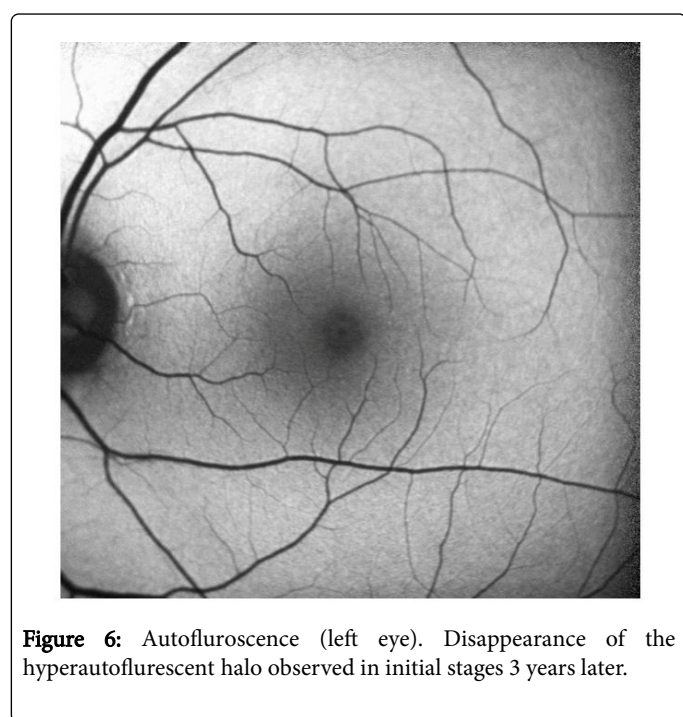
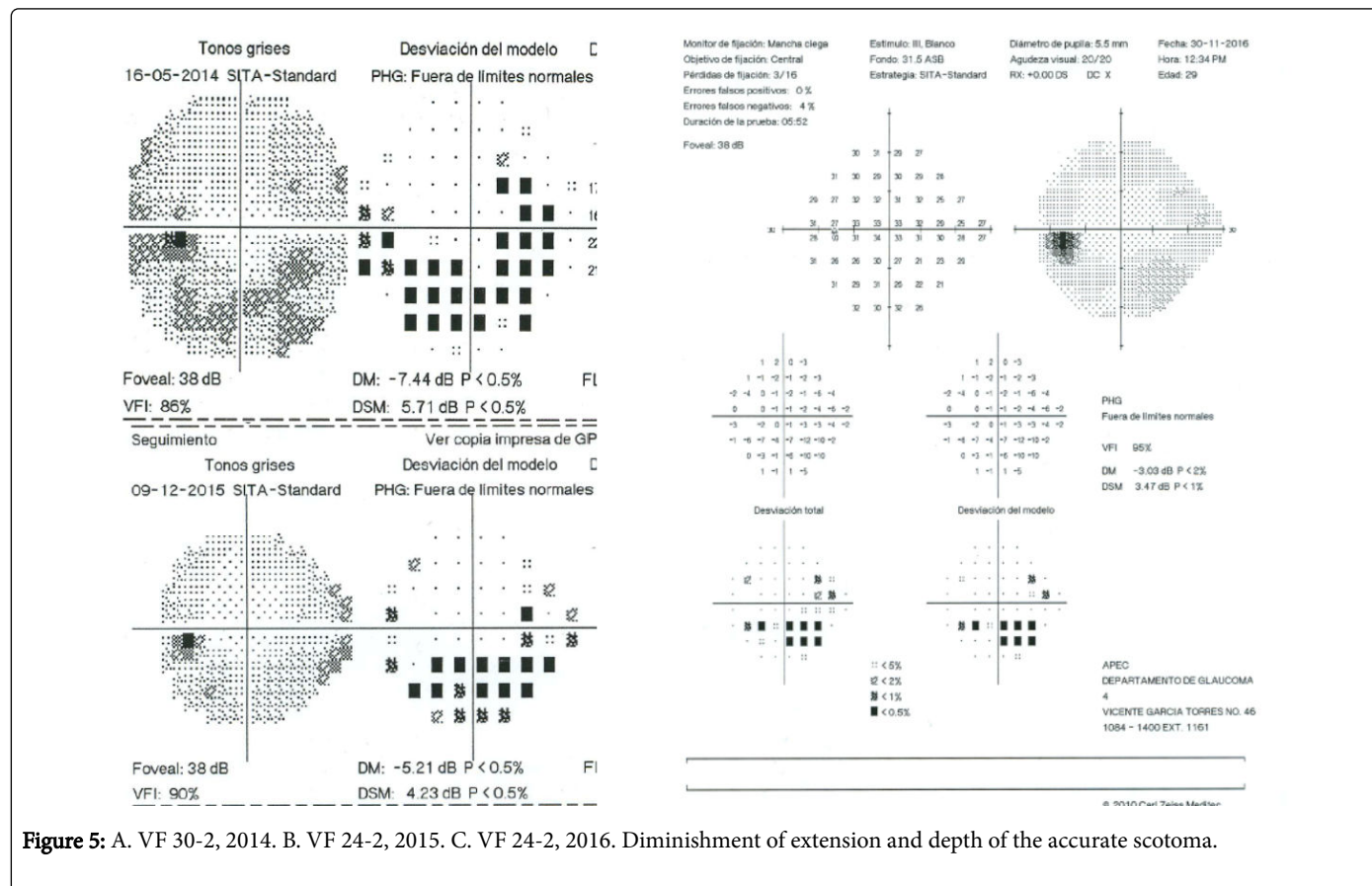
The diagnosis of AZOOR is introduced and a therapeutic test is done with 1 g/24 hours methylprednisolone boluses, three times a month, starting from the month when the first symptoms were experienced. Unfortunately, there is a lack of follow-up during the three months from when the Optical Coherence Tomography (OCT) was realized and showed normal results, even in the areas affected by the scotoma.



**Figure 4:** A: There is a low cone a rod response in photopic condition. B: In flicker 30 Hz test, is evident the cone alterations, with very low amplitude.

Two months later the patient experiences the initial diminishment of extension and depth of the arcuate scotoma (Figure 5). The case was monitored for 3 years and we corroborated a progressive decrease of

the scotoma in visual fields 30-2 as well as a total disappearance of the hyperautofluorescent halo observed in initial stages correlating with the clinical improvement (Figure 6).



## Discussion

In 1993, Gass introduced the term AZOOR to describe a syndrome, predominant in young women, that was previously unknown. In his original series, the 13 patients he describes are cases where a sudden scotoma appeared (in varying areas) along with photopsia, typically with minimal or absent changes in funduscopic examination [1].

In the cases described by Gass there is a correlation with the anomalies that were evidenced in the standard and multifocal ERG exam results, with unilateral or bilateral alterations [2-4].

Taking into accounts these parameters for diagnosis, we will describe points gathered from our patient, comparing them with other data described in other scientific literature. The angiography with fluorescein did not show any changes in the vasculature of the retina at any point throughout the study. Gass et al. showed that from 90 eyes studied with angiography with fluorescein, only 8 (9%) presented angiographic changes [5].

Additionally, the magnetic resonance imaging (MRI) did not show any changes in the optic nerve. Conversely, in standard ERG results, there was an indication of a diminished response of the rods and cones of the eyes (Figure 4) the mfERG showed reduced ranges in the areas that corresponded to the visual field defects.

It is of relevance that Spaide et al. examined 18 eyes in the AZOOR complex (defined as AZOOR, multifocal choroiditis, or multiple

evanescent white dot syndrome) using spectral domain OCT and found that blind spot abnormalities were uniformly associated with abnormal IS/OS boundaries. Patients with AZOOR were found to have areas of markedly attenuated ONL. Takamitsu et al. described 19 eyes with AZOOR in which they found abnormalities of the photoreceptors as evidenced by a significantly decreased photoreceptor layer thickness in the posterior pole away from the central fovea, there was a greater marked decrease in the thickness of the photoreceptor layer. The IS/OS boundary, consistent with previous reports [6-8]. Other findings are attenuation or loss of external nuchal layer, irregularity of RPE or generalized thinning of the retina [10].

However, our patient did not present any changes like those described in the OCT exam, a possible explanation is that it took a while to carry out the OCT due to the loss of interest of the patient in following through with the diagnosis and treatment, as described by Shinji in 2013 in a 39 year-old patient diagnosed with AZOOR in whose OCT was shown alteration in the union line of internal and external segments of photoreceptors whose complete restoration was observed 4 months after the diagnosis [9].

In regards to autofluorescence, we believe that the hyperautofluorescence represents reduced areas of the RPE metabolism resulting from the atrophy of the photoreceptors and/ or the retinal pigment epithelial. Thus, this method of diagnosis is used as marker to study the integrity of the photoreceptors/EPR complex. In our case, the presence of the hyperautofluorescence ring corresponding to the area where Scotoma was identified is a fundamental part of this diagnosis. However, there are reports where the autofluorescence changes can be evidenced with hypo- or hyper autofluorescence, results which have clinical significance.

## Conclusion

We have now new different diagnostic techniques to approach AZOOR including FA and OCT, but clinic anamnesis with visual fields

and electrophysiological test, are the most important and reliable tools to find accurate diagnosis.

## Acknowledgements

Arellanes García, María de Lourdes, Gómez Valdéz, Lilia Margarita. We appreciate and acknowledge the following ophthalmologists who helped in the follow-up examination of these patients.

## References

1. Gass JDM (1993) Acute zonal occult outer retinopathy. *J Clin Neuroophthalmol* 13: 79-97.
2. Chai Y, Yamazaki H, Fujinami K, Tsunoda K, Yamamoto S (2011) Case of acute zonal occult outer retinopathy with abnormal pattern visual evoked potentials. *Clin Ophthalmol* 5: 1235-1241.
3. Arai M, Naoi N, Sawada A, Hayashida T (1998) Multifocal electroretinogram indicates visual field loss in acute zonal occult outer retinopathy. *Am J Ophthalmol* 126: 466-469.
4. Makino S, Tanaka Y, Tampo H (2013) An optical coherence tomography and fundus autofluorescence imaging study of peripapillary acute zonal occult outer retinopathy. *Case Rep Ophthalmol* 4: 11-16.
5. Monson DM, Smith JR (2011) Acute zonal occult outer retinopathy. *Surv Ophthalmol* 56: 23-35.
6. Li D, Kishi S (2007) Loss of photoreceptor outer segment in acute zonal occult outer retinopathy. *Arch Ophthalmol* 125: 1194-1200.
7. Spaide RF, Koizumi H, Freund KB (2008) Photoreceptor outer segment abnormalities as a cause of blind spot enlargement in acute zonal occult outer retinopathy-complex diseases. *Am J Ophthalmol* 146: 111-120.
8. Fujiwara T, Imamura Y, Giovinazzo VJ (2010) Fundus autofluorescence and optical coherence tomographic findings in acute zonal occult outer retinopathy. *Retina* 30: 1206-1216.
9. Makino S, Tampo H (2013) Changes in Optical Coherence Tomography findings in acute zonal occult outer retinopathy. *Case Rep Ophthalmol* 4: 99-104.
10. Monson DM, Smith JR (2011) Acute zonal occult outer retinopathy. *Surv Ophthalmol* 56: 26-35.