

## Multilocular Cystic Nephroma: A Rare Presentation in a Young Female

Charu A<sup>1\*</sup>, Arvind A<sup>2</sup>, Palak A<sup>2</sup>, and Minakshi B<sup>2</sup>

<sup>1</sup>Department of Pathology, ESIC Medical College and Hospital, Faridabad, Haryana, India

<sup>2</sup>Department of Pathology, PGIMER, Dr RML Hospital, New Delhi, India

\*Corresponding author: Charu Agarwal, Department of Pathology, ESIC Medical College and Hospital, Faridabad, Haryana, India, Tel: 8800249608; E-mail: dr.charu.ag@gmail.com

Received date: June 06, 2017; Accepted date: July 18, 2017; Published date: July 24, 2017

Copyright: ©2017 Charu A, et al. This is an open-access article distributed under the terms of the Creative Commons Attribution License, which permits unrestricted use, distribution, and reproduction in any medium, provided the original author and source are credited.

### Abstract

Multilocular cystic nephroma represents a rare benign cystic lesion of the kidney, which usually presents as a unilateral multicystic renal mass without solid elements. It has a bimodal distribution presenting in children between three months to two years, and over 30 years of age in adults. Only 5% of cases occur in young adults. We report case of a 16-year-old female who came with complaints of dull non-radiating pain in left flank since three months and hematuria since 1 week. On palpation, a mass was felt in left subcostal and lumbar region. Ultrasonography and Computed tomography scan showed multiloculated cystic mass in left kidney. Left side nephrectomy was done and specimen was sent for histopathology. Based on histopathological findings, an impression of multilocular cystic nephroma was given. Multilocular cystic nephroma should be considered in the differential diagnosis of malignant cystic renal tumors in both children and adults. Its nonspecific clinical presentations and confusing radiological features create difficult preoperative differentiation. Better diagnostic methods in future may spare the kidney.

**Keywords:** Multilocular cystic nephroma; Malignant cystic renal tumour; Multiloculated; Multicystic renal mass

### Introduction

Cystic diseases of the kidney are diverse [1]. Multilocular cystic nephroma (MCN) is a rare entity constituting about 2.4% of all primary renal lesions [2]. It has many synonyms such as multilocular cystic tumour, renal multilocular cyst, renal cystadenoma and partial polycystic kidney. It is a diagnostic dilemma. It is difficult to distinguish MCN from cystic Wilms tumor and multicystic clear cell carcinoma on the basis of imaging studies alone. Therefore, surgical intervention followed by histopathological examination is the only definitive method to differentiate MCN from a malignant lesion of the kidney [3].

### Case History

A 16-year-old female came to surgery outpatient department with complaints of dull non-radiating pain in left flank since three months and hematuria since 1 week. On examination, an ill-defined mass of 15 × 15 cm was palpable in left subcostal and lumbar region. Laboratory findings were within normal limits. Urine cytology was negative for malignant cells. Ultrasonography (USG) showed a multiloculated cystic mass arising from mid and lower pole of left kidney. The right kidney was normal in size and texture. Contrast enhanced computed tomography (CECT) showed a well-defined enhancing multiseptated cystic mass at the same location extending upto renal pelvis. Radical left nephrectomy was done along with removal of para-aortic lymph nodes because of clinical and radiological suspicion of cystic renal cell carcinoma (RCC).

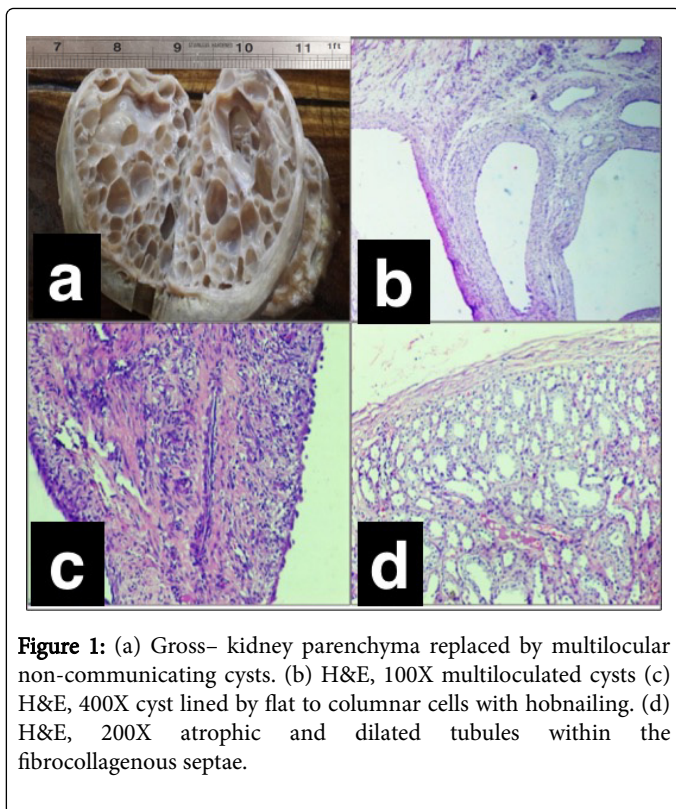
Gross specimen of kidney measured 12 × 8 × 4.5 cm. Outer surface was well encapsulated. On cut section, whole of the kidney was replaced by multilocular non-communicating cysts varying in size from 1 to 4 cm with smooth wall. The cysts contained serous fluid. Part

of normal renal parenchyma was identified compressed at the periphery (Figure 1a). No haemorrhage or necrosis was seen. Microscopic examination showed multilocular cysts lined by single layer of flat to columnar cells with hobnailing of the epithelium (Figures 1b and 1c). The fibrocollagenous septae between the cysts consisted of atrophic and dilated tubules (Figure 1d). No primitive or heterologous element was seen. Normal renal parenchyma was identified compressed at the periphery. There was no evidence of malignancy in the multiple sections examined.

Sections from the para-aortic lymph nodes showed features of reactive lymphoid hyperplasia. Based on these histopathological findings, a diagnosis of MCN was given.

### Discussion

Multilocular cystic nephroma is a rare entity constituting about 2.4% of all primary renal lesions. Boggs and Kimmelstiel in 1956 first proposed the term benign MCN as a synonym for multilocular renal cyst [3,4]. MCN has bimodal age and sex distribution and tends to occur in male children between 3 months and 4 years of age and in adults between 40 and 60 years of age affecting predominantly females [4]. However, our case is unusual presenting at 16 year of age. Only 5% of this rare tumour is seen in the 5-30 years of the age group [5]. Most are unilateral, with the left and right kidneys being equally affected, although the lower poles are more frequently involved than the upper pole. Clinically patient presents with the asymptomatic abdominal mass, occasionally giving rise to abdominal pain or hematuria. The present case also showed similar clinical presentations with unilateral kidney showing lower pole involvement. Its etiology is uncertain and is believed by many authors as a developmental defect [5].



**Figure 1:** (a) Gross– kidney parenchyma replaced by multilocular non-communicating cysts. (b) H&E, 100X multiloculated cysts (c) H&E, 400X cyst lined by flat to columnar cells with hobnailing. (d) H&E, 200X atrophic and dilated tubules within the fibrocollagenous septae.

USG is the first radiologic examination performed for the evaluation and it confirms the cystic nature of the lesion, however CT or magnetic resonance imaging (MRI) are particularly helpful in delineating its circumscribed, multilocular and morphologic features. MRI angiography is an excellent noninvasive method to assess renal vessels before partial nephrectomy [6].

Grossly, the cysts are generally large, multilocular, spherical, sharply demarcated and encapsulated from the adjacent compressed normal renal parenchyma. On cross section, the lesion is bounded by a thick white capsule from which delicate, pale, fibrous trabeculae extend to subdivide them into multiple, spherical, non-communicating, clear fluid filled locules that varies from a few mm to several cm in diameter [7]. Hemorrhage and necrosis are usually not seen. Calcification is also uncommon [4].

Although the histological features of MCN is well described, gross similarities with other cystic tumors of the kidney especially with cystic renal cell carcinoma (RCC) may cause confusion in the diagnosis and conflict in the treatment of this lesion [8].

According to the "WHO classification of the renal neoplasms" it is grouped along with mixed epithelial-stromal tumor of the kidney [9]. Generally, it is believed that MCN is a malformation that enlarges by fluid accumulation and cystic dilatation of individual locules and presents as tumor-like cystic mass [8].

The smooth external surface and lack of normal renal tissue in its septa as in our case clearly distinguishes it from contiguous serous

cysts and from most congenital renal cystic diseases including multicystic renal dysplasia [10]. Extensive sampling was also done to rule out multicystic RCC.

Thus, MCN is a unique and characteristic renal lesion with benign biological behavior. Few authors say that since existing imaging modalities cannot definitely exclude the possibility of multilocular cystic RCC, these patients should undergo surgery. Because of its benign nature this lesion can be best managed by nephron sparing surgery.

Although no evidence of local recurrence or metastatic disease has been reported in the literature, long-term follow-up is encouraged [4].

## Conclusion

Approximately 200 cases have been described in literature till now with the first original report in 1892 by Edmunds. He described a case of MCN in a 18 year old girl [5]. To the best of our knowledge, on extensive data search, ours is a rare case of MCN in a young girl.

There have been no reported cases of malignant behaviour in MCN. However imaging, percutaneous tissue biopsy and cyst aspiration cannot differentiate a multilocular cyst from multicystic RCC, adenocarcinoma, or Wilms' tumour. Thus the management of this lesion, for diagnostic accuracy as well as for treatment, is either by total nephrectomy or partial nephron sparing surgery. A close follow up of these patients is recommended using clinical evaluation and imaging modalities available [4]. Better diagnostic methods, in future, may spare the kidney [2].

## References

1. Kumar A, Fausto A (2010) Robbins and Cotran Pathologic Basis of Disease (8 edition) Saunders Elsevier Publications. Philadelphia.
2. Patel G, Choudhry M, Lakhoo K (2009) The diagnostic dilemma of a multilocular renal cyst: a case report. J Med Case Reports 3: 79.
3. Wilkinson C, Palit V, Bardapure M, Thomas J, Browning AJ, et al. (2013) Adult multilocular cystic nephroma: Report of six cases with clinical, radio-pathologic correlation and review of literature. Urol Ann 5: 13-17.
4. Asl AF (2009) Benign Multilocular Cyst. Iran J Kidney Dis 3: 54-57.
5. Dell'Atti L (2015) An unusual presentation of cystic nephroma in an adult man. Rare tumours 7: 81-83.
6. Ferrer FA, McKenna PH (1994) Partial nephrectomy in a metachronous multilocular cyst of the kidney (cystic nephroma). J Urol 151: 1358-1360.
7. Jennette JC (2007) Heptinstall's Pathology of the Kidney. Lippincott Williams & Wilkins.
8. Stamatiou K, Polizois K, Kollaitis G, Dahanis S, Zafeiropoulos G, et al. (2008) Cystic nephroma: a case report and review of the literature. Cases J 1: 267.
9. Eble JN, Sauter G, Epstein JI, Sesterhenn IA (2004) World Health Organization classification of tumours. Pathology and genetics of tumors of the urinary system and male genital organs. Lyon: IARC Press.
10. Banner MP, Pollack HM, Chatten J, Witzleben C (1981) Multilocular renal cysts: radiologic- pathologic correlation. Am J Roentgenol 136: 239-247.