

## Mycotic Aneurysm of the Abdominal Aorta Caused by *Salmonella* Non-Typhi Treated Surgically

Ben Jmaa Hela<sup>1\*</sup>, Masmoudi Sayda<sup>1</sup>, Jmal Hassen<sup>1</sup>, Ben Jmaa Tarak<sup>2</sup>, Koubaa Makram<sup>2</sup>, Elleuch Sahar<sup>3</sup>, Souissi Iheb<sup>3</sup>, Ben Jmaa Mounir<sup>2</sup>, Karoui Abdelhamid<sup>3</sup> and Frikha Imed<sup>1</sup>

<sup>1</sup>Department of Cardio-Vascular and Thoracic Surgery, Habib Bourguiba Hospital Sfax, Tunisia

<sup>2</sup>Department of infectious diseases, Hedi Chaker Hospital Sfax, Tunisia

<sup>3</sup>Department of anesthesiology, Habib Bourguiba Hospital Sfax, Tunisia

\*Corresponding author: Ben Jmaa Hela, Department of Cardio-Vascular and Thoracic Surgery, Habib Bourguiba Hospital, 3029 Sfax, Tunisia, Tel: 0021696704740; E-mail: helabenjmaa2015@gmail.com

Received date: February 01, 2016; Accepted date: February 08, 2016; Published date: February 18, 2016

Copyright: © 2016 Hela BJ, et al. This is an open-access article distributed under the terms of the Creative Commons Attribution License, which permits unrestricted use, distribution, and reproduction in any medium, provided the original author and source are credited.

### Abstract

Mycotic aneurysms are irreversible dilatation, localized in the artery due to the destruction of the wall by an infectious agent. We present the case of a 65 year old man treated for saccular aortic aneurysm, infra-renal secondary to infection with *Salmonella Paratyphi B*. After appropriate antibiotic therapy, the patient underwent resection with aneurysmal debridement followed by anatomical reconstruction with a prosthetic graft.

He recovered well and quickly returned to normal functional status.

The mycotic aortic disease is rare, but severe. However, improved diagnostic tools, appropriate antibiotic treatment, recent surgical techniques have reduced the high mortality associated with this pathology.

**Keywords:** Mycotic aneurysm; Abdominal aorta; Surgery

### Introduction

The mycotic aortic aneurysm is a rare disease with an incidence of about 0.65% to 2% of all aortic aneurysms [1].

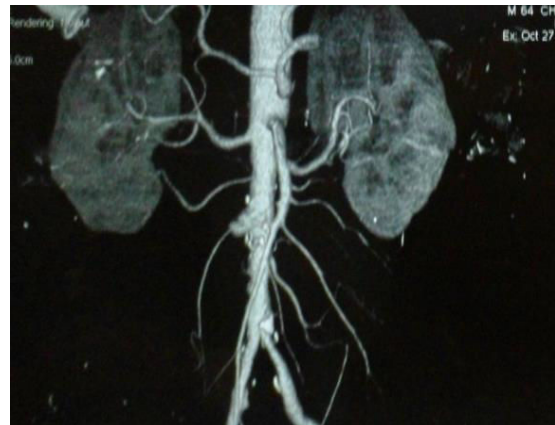
Pathogens include infectious organisms, the most common of which are *Staphylococcus aureus*, *Salmonella* and *Streptococcus* [2].

We report the case of a patient with a saccular aneurysm of the infra-renal aorta, due to a systemic infection with *Salmonella Paratyphi B* treated successfully with antibiotics and surgical resection.

### Case Report

We report the case of a 65 year old man (a farmer), diabetic, admitted to the emergency department for fever and severe abdominal pain which started since 10 days. Biological tests have revealed leukocytosis 22,000/mm<sup>3</sup>, and blood cultures were positive for *Salmonella paratyphi B*.

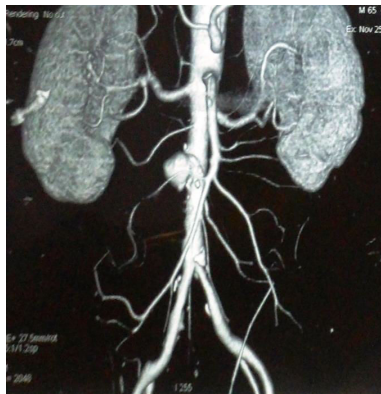
The transthoracic echocardiography excluded endocarditis. Abdominal CT scan revealed a small aneurysm of the antero-lateral wall of the aorta measuring 15 mm in diameter (Figure 1).



**Figure 1:** Initial computed tomography scan showing a saccular aneurysm of the abdominal aorta (arrow).

Antibiotic therapy was started with ceftriaxone (1.0 g every 12 h), and ofloxacin (400 mg every 12 h) for 6 weeks. The evolution was marked by the resolution of fever, abdominal pain, and bacteremia.

An abdominal CT scan performed after antibiotic therapy has revealed the progression and expansion of the aneurysm to 20 mm (Figure 2).



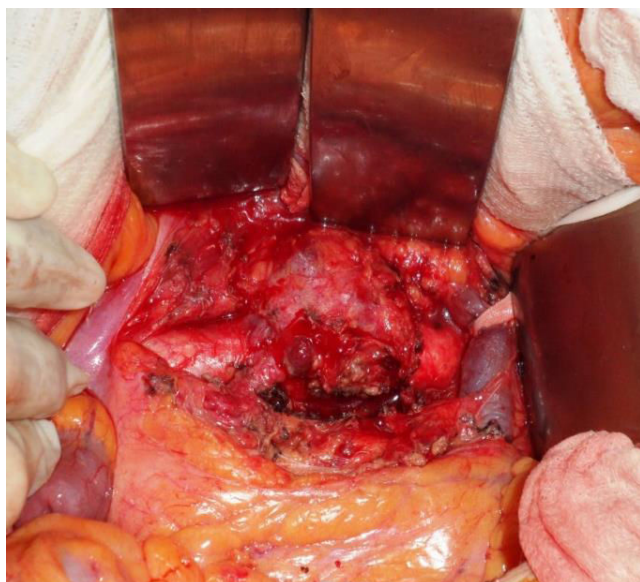
**Figure 2:** Second CT scan showing enlargement of the aneurysmal dilation (arrow).

Because of the high risk of aneurysmal rupture, the patient underwent open surgery through a median laparotomy.

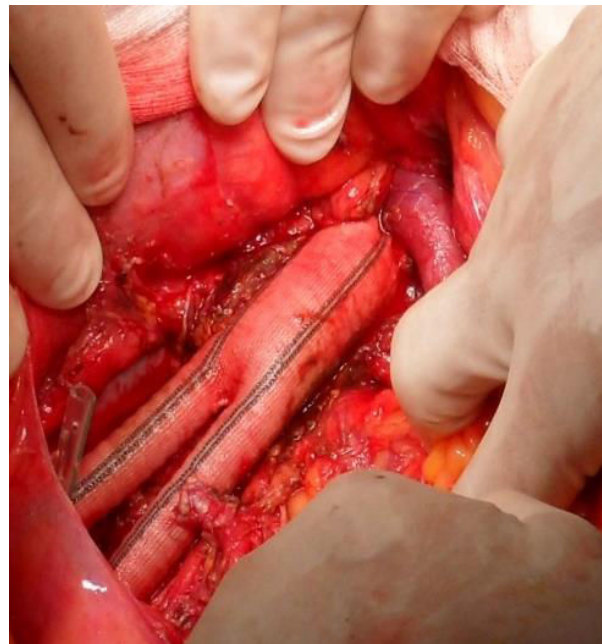
The intraoperative exploration revealed an inflammation and a saccular dilatation of the infra-renal aorta (Figure 3).

The aorta and the common iliac arteries were clamped and the aorta was opened. The aortic wall was atherosclerotic.

After resection of the aneurysm with debridement of the surrounding tissue, an anatomical reconstruction, with replacement of the damaged portion of the aorta with a synthetic graft, with implantation of the lower mesenteric artery into the prosthesis was performed (Figure 4).



**Figure 3:** Intraoperative view showing the saccular dilatation of the infra-renal aorta (arrow).



**Figure 4:** Intraoperative view showing completed anatomical repair.

Histopathological exam and cultures of a sample of the aortic wall were negative.

The postoperative course was uneventful. The patient had no abdominal pain, and the pulses of the two lower limbs were present.

The patient was discharged after 7 days.

He was seen at 1 month after the operation and he is fine.

## Discussion

Mycotic aortic aneurysms can occur following a bacterial infection of a previously normal artery wall or secondary infection of a preexisting aneurysm [3].

*Staphylococcus aureus* and *Salmonella typhi* are the main microorganisms involved in the occurrence of mycotic aneurysms, especially in elderly diabetic patients, as was the case of our patient [4,5].

As a result of bacteremia, atheromatous lesions within the aneurysm can become infected, leading to necrosis and rupture of the aortic wall [6].

Most patients have non-specific symptoms like fever, back pain, and abdominal pain.

The biological manifestations are bacteremia, hyper leukocytosis, and elevated erythrocyte sedimentation rate [5]. A positive blood culture with radiological abnormalities of the aorta strongly suggests a bacterial disease [7].

The intensive antibiotic therapy is crucial and should be started as early as possible before surgery. The time required varies from 6 to 8 weeks [8].

Surgical treatment of mycotic aneurysms includes a resection of the aneurysmal sac with debridement of the infected tissue. The reconstruction can be extra-anatomic to avoid the use of grafts in a contaminated area [5,9]. However, the patency rate for axillo-femoral bypass is poor [10].

The anatomic aortic reconstruction using cryopreserved homograft or grafts showed excellent short and long-term results [11,12]. The advantage of homograft is to prevent recurrence of the infection, but they raise the problem of availability.

In our case, inflammation of surrounding tissue was important, but without local signs of infection, and for the unavailability of homograft, we used an anatomical reconstruction with a prosthetic Dacron graft impregnated with rifampicin. An implantation of the lower mesenteric artery in the prosthesis was performed.

The postoperative mortality rate of this type of aneurysm remains high, between 21% and 36% [13].

Experience with endovascular treatment of mycotic aneurysms is limited [14]. Therefore, it is still uncertain whether endovascular treatment or surgical prosthetic repair provides the best short and long-term results.

The main disadvantage of the endovascular treatment is that the infected tissue is not resected, which can facilitate the recurrence of the infection, and the infection of the stent graft [15].

## Conclusion

Mycotic aneurysms of the aorta remain a severe life-threatening disease. The management is based on the resection of infected tissues, and vascular reconstruction using allografts; if they are unavailable by prosthetic graft, associated with an antibiotic therapy for a long period.

## References

1. Reddy DJ, Shepard AD, Evans JR, Wright DJ, Smith RF, et al. (1991) Management of infected aorto-iliac aneurysms. *Arch Surg* 126: 873-879.
2. Gross C, Harringer W, Mair R, Wimmer-Greinecker G, Klima U, et al. (1994) Mycotic aneurysms of the thoracic aorta. *Eur J Cardiothorac Surg* 8: 135-138.
3. Aziz S, McWilliams R, Rashid A, Gosney JR, Harris PL, et al. (2006) Late aortic rupture due to stent margin pseudoaneurysm formation complicating endovascular stent graft repair of a thoracic aortic mycotic aneurysm. *EJVES Extra* 1: 30-34.
4. Schindler N, Calligaro KD, Dougherty MJ, Diehl J, Modi KH, et al. (2002) Melioidosis presenting as an infected intrathoracic subclavian artery pseudoaneurysm treated with femoral vein interposition graft. *J Vasc Surg* 35: 569-572.
5. Hari RK, Mark KE (2015) The benefit of early repair for a mycotic aortic aneurysm due to *Yersinia enterocolitica* infection. *J Vasc Surg Cases* 1: 61-64.
6. Fichelle JM, Tabet G, Cormier P, Farkas JC, Laurian C, et al. (1993) Infected infrarenal aortic aneurysms: when is in situ reconstruction safe? *J Vasc Surg* 17: 635-645.
7. Azizi ZA, Yahya M, Lee SK (2005) Melioidosis and the vascular surgeon: Hospital Kuala Lumpur experience. *Asian J Surg* 28: 309-311.
8. Hollier LH, Money SR, Creely B, Bower TC, Kazmier FJ (1993) Direct replacement of mycotic thoracoabdominal aneurysms. *J Vasc Surg* 18: 477-484.
9. Bennett DE, Cherry MJ (1967) Bacterial infection of aortic aneurysms. *Am J Surg* 113: 321-326.
10. Pasic M, Carrel T, Vogt M, von Segesser L, Turina M (1992) Treatment of mycotic aneurysm of the aorta and its branches: the location determines the operative technique. *Eur J Vasc Surg* 6: 419-423.
11. Harlander-Locke MP, Harmon LK, Lawrence PF, Oderich GS, McCready RA, et al (2014) The use of cryopreserved aortoiliac allograft for aortic reconstruction in the United States. *J Vasc Surg* 59: 669-674.
12. Strachan CJ, Newsom SW, Ashton TR (1991) The clinical use of an antibiotic-bonded graft. *Eur J Vasc Surg* 5: 627-632.
13. Müller BT, Wegener OR, Grabitz K, Pillny M, Thomas L, et al. (2001) Mycotic aneurysms of the thoracic and abdominal aorta and iliac arteries: experience with anatomic and extra-anatomic repair in 33 cases. *J Vasc Surg* 33: 106-113.
14. Berchtold C, Eibl C, Seelig MH, Jakob P, Schönleben K (2002) Endovascular treatment and complete regression of an infected abdominal aortic aneurysm. *J Endovasc Ther* 9: 543-548.
15. Sörelius K, Mani K, Björck M, Nyman R, Wanhainen A (2009) Endovascular repair of mycotic aortic aneurysms. *J Vasc Surg* 50: 269-274.