

## Nailfold Capillaroscopy in Diabetes Mellitus: Potential Technique for the Microvasculature Evaluation

Maldonado G<sup>1\*</sup> and Rios C<sup>2</sup>

<sup>1</sup>Universidad Espíritu Santo, Ecuador

<sup>2</sup>Center of Rheumatology and Rehabilitation, Ecuador

\*Correspondence author: Génessis Maldonado, Universidad Espíritu Santo, Ecuador, Tel: (593-4) 2835630; E-mail: [genesismaldonadovelez92@gmail.com](mailto:genesismaldonadovelez92@gmail.com)

Received date: June 1, 2017; Accepted date: June 5, 2017; Published date: June 9, 2017

Copyright: © 2017 Maldonado G. This is an open-access article distributed under the terms of the Creative Commons Attribution License, which permits unrestricted use, distribution, and reproduction in any medium, provided the original author and source are credited.

### Editorial

Capillaroscopy is a non-invasive method for the observation of capillary microvasculature. In recent years, it has gained recognition in the field of diseases that affect microcirculation, especially in rheumatic diseases. However, studies published in the last decade have demonstrated the importance of this innovative technique in non-rheumatic diseases such as diabetes mellitus.

Because of the importance of vascular involvement in diabetes mellitus, direct observation tools such as ophthalmoscopes, magnifying lenses, and among them capillaroscopy [1-4], have been used to evaluate microvasculature.

Research methods of the capillaries have varied through the years, from the use of stereomicroscopes with magnification of 10-100X for the visualization of the entire nailfold area [5] to new semiautomatic methods for the visualization of the capillaries with an innovative television system [6].

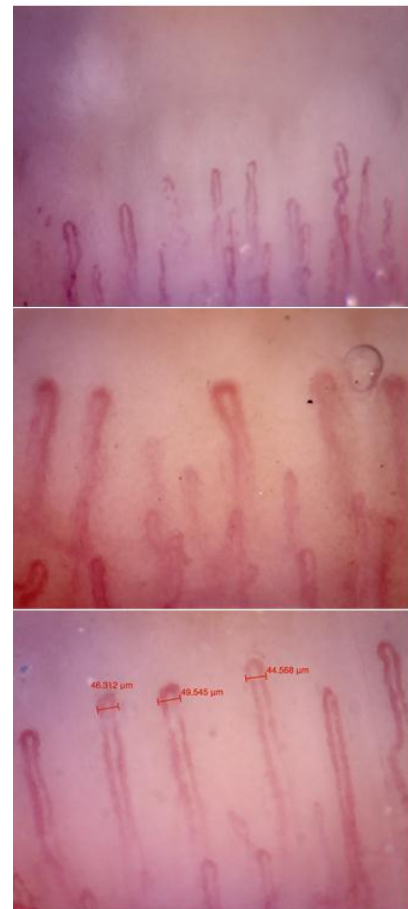
Other optical methods such as ophthalmoscopes and dermatoscopes were also used. Currently, for the observation of capillaries it is used the videocapillaroscopy that consists of a combination of a microscope and a digital recorder that provides a magnification of 50-100X.

The indications for capillaroscopy are: Evaluation of patients with Raynaud's Phenomenon, differential diagnosis of collagenopathies, primary diagnosis of scleroderma, diseases that compromise the capillary microarchitecture, like diabetes mellitus [7,8].

The dermal papillae are located perpendicularly to the cutaneous surface. The capillary arrangement at the nailfold level is located in a parallel or oblique way in relation to the cutaneous plane, in two or three layers.

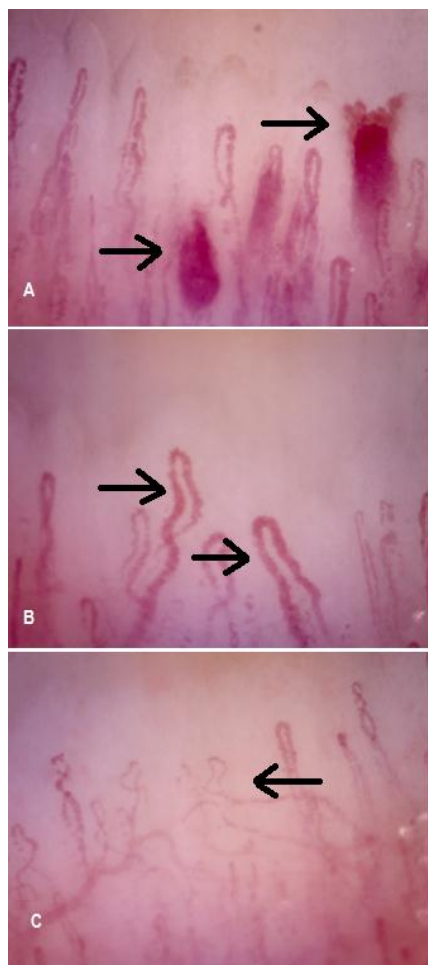
The capillary loop consists of an arterial or afferent branch and a venous or efferent branch. The main parameters to be evaluated are: length, diameter, density, venous plexus and morphological abnormalities. These elements should be evaluated in the distal row or near the nailfold. The normal number of capillaries per millimeter is from seven to twelve arranged in an inverted U-shape (Figure 1).

Recent studies conclude that capillaroscopy provides key data for the determination of vascular damage in diabetic patients and thus, allows the evaluation of the progression of the disease [9], making this technique a potential future utility in the microvascular disease evaluation.



**Figure 1:** Normal capillaroscopy pattern, inverted U-shaped capillaries.

Maldonado et al. demonstrated that the use of capillaroscopy in patients with diabetes allows the identification of capillaroscopic abnormalities, possibly including a characteristic pattern in this group of patients consisting of tortuous, cross-linked capillaries, avascular zones and ectasias, also the study showed an association between microangiopathies seen at the ophthalmoscopy and the presence of ramified capillaries and avascular zones seen at the nailfold level [1] (Figure 2).



**Figure 2:** Capillaroscopy in a diabetic patient. A: Hemorrhages (arrows) due to capillary wall rupture, B: Decreased capillary density with tortuous and dilated capillaries (arrows). C. Altered capillary structure, cross-linked and tortuous capillaries (arrows).

Barchetta studied the possible relationship of microangiopathic lesions detected in retinal vessels and capillary changes in patients with type I and type II diabetes [10]. It was observed that these patients had a greater capillary diameter, ectasias and nailfold edema, in contrast with healthy subjects [10].

Uyar et al. studied a population of patients diagnosed with diabetes mellitus and evidenced large capillaroscopic changes such as: tortuous capillaries, ramified, increased capillary diameter, compared to the control group. In addition, in patients with diabetic retinopathy, these alterations were increased [11].

Maldonado et al. found an association between microangiopathies at the funduscopy and capillaroscopic alterations such as ramified capillaries and avascular zones [1]. Chang et al. also found a correlation between diabetic retinopathy and the presence of tortuous, ramified capillaries and capillary dilatation, in addition to confirming that these alterations are increased with the severity of diabetic retinopathy [3].

These patterns demonstrate that a microvascular component exists in the pathophysiology of diabetic retinopathy and capillaroscopy is a tool that can accurately detect capillaroscopic changes and relate them to systemic vascular complications.

Focusing in the metabolic control, chronic hyperglycemia affect the capillary endothelia, generating microvascular architecture changes [12], that can be evidenced by the use of capillaroscopy [13,14]. Also the disease evolution has shown that can contribute to capillaroscopy changes, Kuryliszyn et al. found an escalating appearance of ramified capillaries in diabetic patients with a prolonged evolution time (of more than 10 years) [9]. Bollinger et al. showed similar data, in which they described more capillaroscopic alterations in diabetic patients with a disease evolution of over 10 years [5].

However, the main limitation remains in the small number of articles focusing on the qualitative findings and relationship with markers of disease progression yet to be established. Since the capillaroscopy is a potential future utility in the evaluation of microvascular, there is a need of more research in this field.

## References

1. Maldonado G, Guerrero R, Paredes C, Ríos C (2017) Nailfold capillaroscopy in diabetes mellitus. *Microvasc Res* 6: 41-46.
2. Rajaei A, Dehghan P, Farahani Z (2015) Nailfold capillaroscopy findings in diabetic patients. *Open J Pathol* 5: 65-72.
3. Chang CH, Tsai RK, Wu WC, Kuo SL, Yu HS (1997) Use of dynamic capillaroscopy for studying cutaneous microcirculation in patients with diabetes mellitus. *Microvasc Res* 53: 121-127.
4. Chhablani J, Kaja S, Shah V (2012) Smartphones in ophthalmology. *Indian J Ophthalmol* 60: 127-131.
5. Bollinger A, Fagrell B (1990) *Clinical capillaroscopy - a guide to its use in clinical research and practice*. Toronto: Hogrefe & Huber Publishers 1-123.
6. Hu Q, Mahler F (1999) New system for image analysis in nailfold capillaroscopy. *Microcirculation* 6: 227-235.
7. Souza E, Kayser C (2015) Nailfold capillaroscopy: Relevance to the practice of rheumatology. *Rev Bras Reum* 55: 264-271.
8. Pazos-Moura C, Moura E, Bouskela E, Torres-Filho I, Breitenbach M (1987) Nailfold capillaroscopy in diabetes mellitus morphological abnormalities and relationship with microangiopathy. *Braz J Med Biol Res* 20: 777-780.
9. Kuryliszyn-Moskal A, Dubicki A, Zaezycki W, Zonnenberg A, Gorska M (2006) A study on microvascular abnormalities in capillaroscopy in patients with type 1 diabetes mellitus. *Diabetol Dosw i Klin* 6: 98-103.
10. Barchetta I, Ricciari V, Vasile M, Stefanantoni K, Comberiat P, et al. (2011) High prevalence of capillary abnormalities in patients with diabetes and association with retinopathy. *Diabet Med* 28: 1039-1044.
11. Uyar S, Balkar JA, Kazum Erol M, Yesil B, Tokuç A, et al. (2016) Assessment of the relationship between diabetic retinopathy and nailfold capillaries in type 2 diabetics with a noninvasive method: Nailfold videocapillaroscopy. *J Diabetes Res* 7.
12. American Diabetes Association (2015) Standards of medical care in diabetes. *Diabetes Care* 38.
13. Kuryliszyn-Moskal A, Dubicki A, Zarzycki W, Zonnenberg A, Gorska M (2011) Microvascular abnormalities se-selectine levels in patients with type I diabetes complicated by microangiopathy. *Folia Histochem Citobiol* 49: 104-110.
14. Romano C, Costa M, Messina M, Bertini M (2015) Videocapillaroscopy in diabetes. *Diabetes Res Open J* 2: 3-6.