

## Neurofibromatosis Type 1 and Recurrent Metastatic Low-Grade Fibromyxoid Sarcoma: Case Report about a Rare Association

Hafsae Bounniyt<sup>1\*</sup>, Majda Askour<sup>1</sup>, Ilham Mekkassi<sup>1</sup>, Fatima-Zahra Lamchahab<sup>1</sup>, Asmae Benzekri<sup>2</sup>, Karima Senouci<sup>1</sup> and Badredine Hassam<sup>1</sup>

<sup>1</sup>Department of Dermatology-Venereology, Ibn Sina University Hospital, Mohammed V University, Rabat, Morocco

<sup>2</sup>Department of Anatomical Pathology, United Nations, Agdal, Rabat, Morocco

\*Corresponding author: Hafsae Bounniyt, Department of Dermatology-Venereology, Ibn Sina University Hospital, Mohammed V University, Rabat, Morocco, Tel: + 00 212 6 62395350; E-mail: b.hafsae@hotmail.fr

Received date: April 04, 2017; Accepted date: May 27, 2017; Published date: June 01, 2017

Copyright: © 2017 Bounniyt H, et al. This is an open-access article distributed under the terms of the Creative Commons Attribution License, which permits unrestricted use, distribution, and reproduction in any medium, provided the original author and source are credited.

### Abstract

Neurofibromatosis type 1 is the most frequent phacomatosis. Patients with neurofibromatosis type 1 (NF1) have a high risk to develop benign or malignant tumors of neurogenic or non-neurogenic origin. The association of (NF1) to low-grade fibromyxoid sarcoma (LGFMS) is very rare. These tumors rarely develop at the skull and have a high incidence of local recurrence and distant metastasis. We report a case of occipital LGFMS in a patient diagnosed with NF1 that developed a local and metastatic recurrence.

**Keywords:** Neurofibromatosis type 1; Low-grade fibromyxoid sarcoma; Recurrence; Lung metastasis; Occipital tumor

**Abbreviations:** NF1: Neurofibromatosis Type 1; LGFMS: Low-Grade Fibromyxoid Sarcoma.

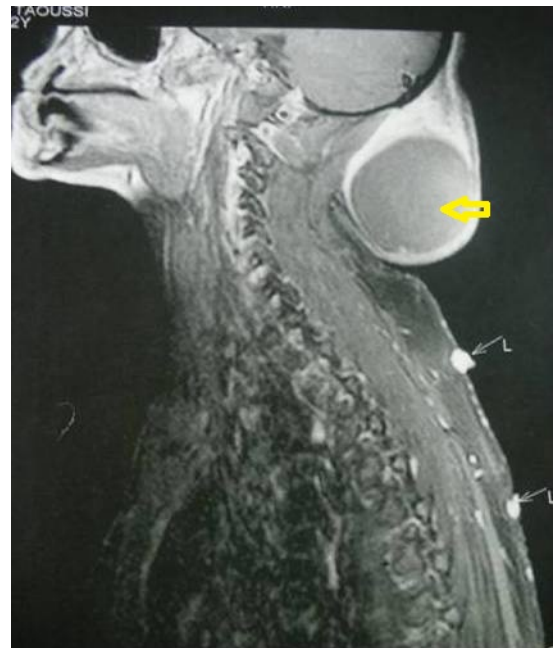
### Introduction

Neurofibromatosis type 1 is the most frequent phacomatosis; it is a genetic disease that is transmitted in the autosomal dominant mode. Patients with NF1 are likely to develop benign or malignant tumors. The incidence of skin tumors increases with age. We report an original case rarely reported in the literature associating NF1 with a low-grade fibromyxoid sarcoma in a young patient of 42 years, whose evolution was unfavorable.

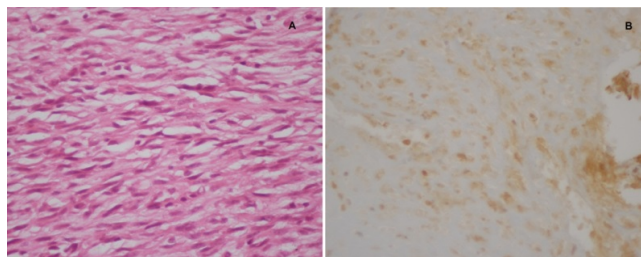
### Clinical Case

A 42-year-old patient, followed irregularly (due to lack of compliance) for neurofibromatosis type 1, which complained from a progressively increasing occipital swelling. The patient consulted a neurologist six years later, when a cervical and medullary MRI was performed, showing the presence of a large subcutaneous tissue mass, at the level of the cervico-occipital hinge, measuring 100 × 70 × 90 mm, hypointense on T1 sequence and hyperintense on T2 sequence, heterogeneously enhancing after injection of Gadolinium (Figure 1).

The patient was referred to us after resection of her tumor. The histopathological examination revealed a fusiform proliferative process in a background of myxoid rearrangement with broad necrosis ranges and 5 mitoses/10 champs (Figure 2A). The cells expressed smooth muscle actin at immunohistochemical staining, (Figure 2B). These findings were in favor of LGFMS.

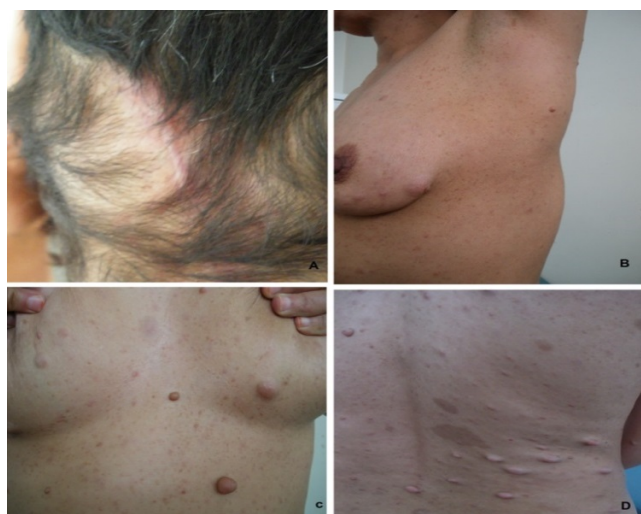

**Figure 1:** MRI image showing a craniocervical swelling hyperintense on T2.



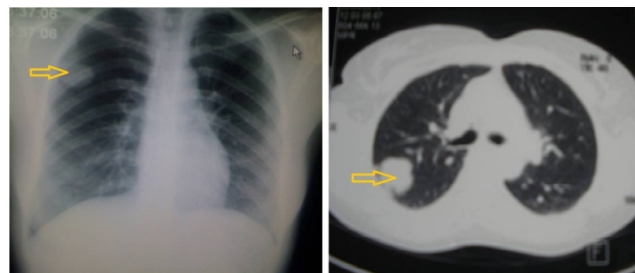
**Figure 2:** (A) HES  $\times 20$  Morphology evocative of low-grade fibromyxoid sarcoma: a proliferation of fusiform cells without any notable atypia arranged in fascicles in a collagen matrix. (B) Immunohistochemistry  $\times 20$  diffuse expression of the antibody with anti-smooth muscle actin.

Physical examination at admission found a patient in good general condition, presenting a large and supple scar at the occipital level, measuring 13 cm (Figure 3A) and signs of type 1 neurofibromatosis, including multiple coffee-to-milk spots, axillary and inguinal lentiginos, cutaneous neurofibromas (Figures 3B-3D) as well as multiple lish nodules on ophthalmological examination.

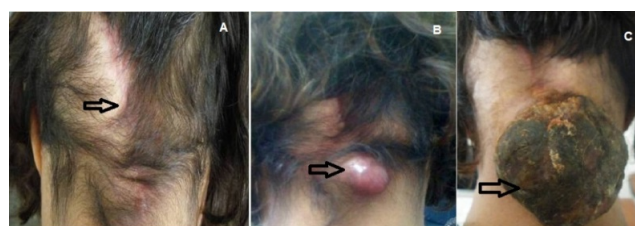

**Figure 3:** (A) Occipital scar of tumor excision, measuring 13 cm long axis. Clinical features of neurofibromatosis type 1. (B) Axillary lentiginos. (C) Under breast lentiginos. (D) Cutaneous neurofibromas and coffee-to-milk spots.

Screening imaging including chest radiograph completed by a chest, abdomen and pelvic computed tomography (CT) showed lung metastases of the LGFMS (Figure 4A and 4B) confirmed on CT-guided biopsy. The patient underwent a resection of these nodules, and then a Doxorubicin-Ifosfamide-Mesna based chemotherapy was indicated. Before starting the first course, the patient presented a swelling at the occipital tumor bed which rapidly increased in volume in less than a month (Figure 5A-C). The patient refused any therapeutic management and was unfortunately lost to sight.



**Figure 4:** Right upper lung lobe metastatic nodules. (A) At the lung radiography. (B) chest CT scan.



**Figure 5:** (A) Initial Scar at the admission of the patient after removal of the primary tumor. (B) Local recurrence in a picture taken by the patient just after the assessment of extension. (C) Rapid increase of the lesion as a firm tumor, painless, with extensive necrosis ranges.

## Comments

Formerly known as Von Recklinghausen disease, neurofibromatosis type 1 (NF1) is the most common form of phacomatosis and neurofibromatosis [1]. Its incidence is estimated at 1/2500 births. It is transmitted in an autosomal dominant mode, and results in the presence of mainly cutaneous, cerebral, peripheral nerves, bone and vascular dysplasias [2].

NF1 is a relatively benign condition in 80% of patients, but the risk of developing benign or malignant tumors of neurogenic or non-neurogenic origin is high. Compared to the general population, life expectancy is decreased by about ten years in patients with NF1 [3]. The association with fibromyxoid sarcomas is rare. We report an original case, rarely reported in the literature of this association.

LGFMS was described for the first time in 1987 by Evans [4] when he reported two cases of scapular LGFMS with pulmonary metastases in two patients. According to the WHO 2013 classification of soft tissue tumors, LGFMS is currently considered a malignant tumor belonging to the fibroblastic/myofibroblastic tumor group [5]. It locates preferentially in the soft tissues of the proximal regions of the limbs and trunk; Occipital localization is exceptional as is the case in our patient [6]. The LGFMS occurs mainly in young adults and middle-aged population (median 34 years) without sex predominance; pediatric cases have also been reported [7,8].

Positive diagnosis is difficult; at the histological examination; macroscopic appearance finds a very limited, fibrous lesion, often focally mucoid. The size varies from 1 cm to more than 20 cm.

microscopically, it shows an alternation of densely collagenous zones and clearer myxoid ones, and a proliferation of non-atypical fusiform cells, forming short coiled beams associated with a curvilinear vascularization [9]. On the genetic study, A chimeric fusion gene was recently discovered in LGFMS: FUS/CREB3L2 (also known as BBF2H7), the expression of this gene appears to be specific, confirming the distinct character of this tumor [9,10]. There was no genetic study done in our patient.

The LGFMS can be confused with several benign and malignant entities. The main differential diagnoses are: intramuscular myxoma, myxoid liposarcoma, myxoid variety of prominent dermatofibrosarcoma and low grade myxofibrosarcoma [11]. Low recurrence (10%) and metastasis (5%) rates are noted in the first five years after resection.

However, in the longer term, the risk of recurrences, metastasis and mortality increases: 64%, 45% and 42% of patients respectively [5]. The metastases occur essentially at the lungs as in our patient; hence, we highlight the interest of a multidisciplinary and regular follow-up of any patient suffering from neurofibromatosis type 1, as the long-term evolution can sometimes be fatal.

In our case, delayed medical consult and management (six years after the onset of the first occipital swelling) and then large tumor size have favored local recurrence and metastatic spread, which are factors of very poor prognosis in this young patient.

The benefit of adjuvant therapies such as chemotherapy or radiotherapy in non-metastatic patients is not well defined.

Patients with LGFMS should remain under close follow up for a long time due to late relapses.

## Conclusion

Low-Grade Fibromyxoid Sarcoma is known for its bland histological features and paradoxically an aggressive clinical behavior. Keeping in

mind the aggressive evolutionary aspects, despite an indolent appearance on histopathology, LGFMS should be treated aggressively with wide excision. The role of adjuvant chemotherapy and radiotherapy remains unspecified.

## References

1. Ferner RE (2007) Neurofibromatosis 1. *Eur J Hum Genet* 15:131-138.
2. Ferner RE (2010) The neurofibromatoses. *Pract Neurol* 10: 82-93.
3. Wilding A, Ingham SL, Lalloo F, Clancy T, Huson SM, et al. (2012) Life expectancy in hereditary cancer predisposing diseases: an observational study. *J Med Genet* 49: 264-269.
4. Evans HL (1987) Low-grade fibromyxoid sarcoma. A report of two metastasizing neoplasms having deceptively benign appearance. *Am J Clin Pathol* 88: 615-619.
5. Evans HL (2011) Low-grade fibromyxoid sarcoma: a clinicopathologic study of 33 cases with long-term follow-up. *Am J Surg Pathol* 35:1450-1462.
6. Evans HL (1993) Low-grade fibromyxoid sarcoma: A report of 12 cases. *Am J Surg Pathol* 17: 595-600.
7. Genevay M, Coindre JM, Guillou L (2003) Entités récentes en pathologie tumorale des tissus mous. *Ann Pathol* 23: 135-148.
8. Billings SD, Giblen G, Fanburg-Smith JC (2005) Superficial low-grade fibromyxoid sarcoma (Evans tumor): a clinicopathologic analysis of 19 cases with a unique observation in the pediatric population. *Am J Surg Pathol* 29: 204-210.
9. Reid R, de Silva MV, Paterson L, Ryan E, Fisher C (2003) Low-grade fibromyxoid sarcoma and hyalizing spindle cell tumor with giant rosettes share a common t(7;16)(q34;p11) translocation. *Am J Surg Pathol* 27: 1229-1236.
10. Panagopoulos I, Storlazzi CT, Fletcher CD, Fletcher JA, Nascimento A, et al. (2004) The chimeric FUS/CREB312 gene is specific for low-grade fibromyxoid sarcoma. *Genes Chromosomes Cancer* 40 : 218-228.
11. Nielsen GP, O'Connell JX, Rosenberg AE (1998) Intramuscular myxoma: a clinicopathologic study of 51 cases with emphasis on hypercellular and hypervascular variants. *Am J Surg Pathol* 22: 1222-1227.