

Image Article

Open Access

## Non Absorbable Suture Should be Avoided When Operating on the Biliary Tree

Kirby G, Macano C, Sitaramachandra Murthy N\* and Perry A

General Surgery, Heart of England NHS Foundation Trust, UK

### Image Article

Non-absorbable and braided sutures should be avoided whilst operating on the bile duct, for example when closing a choledochotomy or ligating the cystic duct. Suture material may migrate into the lumen of the duct over time. Foreign objects may act as a nidus for stone formation [1]. This complication is demonstrated by the Figure 1 below:

an intra-operative cholangiogram demonstrating choledocholithiasis, and the stone extracted at laparoscopic bile duct exploration measuring 24 mm, which had formed around a braided suture used during open cholecystectomy 37 years previously in Poland.

### References

1. Beardsley C, Lim J, Gananadha S (2012) Nonabsorbable suture material in the biliary tract. *J Gastrointest Surg* 16: 2182-2183.

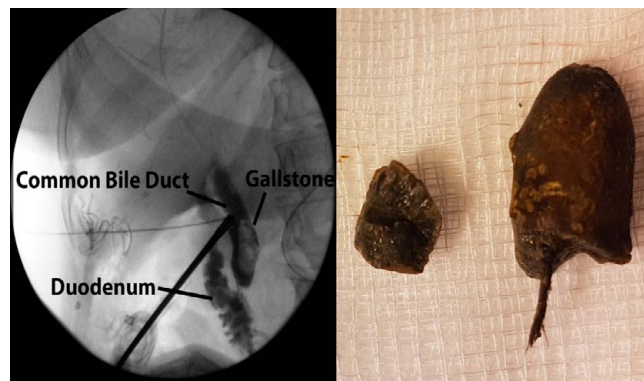


Figure 1: Represents an intra-operative cholangiogram.

**\*Corresponding author:** Sitaramachandra Murthy N, Senior Clinical Fellow, General Surgery, Heart of England NHS Foundation Trust, General Surgery, United Kingdom, Tel: 00441162434120; E-mail: [murthy.nyasavajjala@nhs.net](mailto:murthy.nyasavajjala@nhs.net)

**Received** January 07, 2017; **Accepted** January 17, 2017; **Published** January 27, 2017

**Citation:** Kirby G, Macano C, Sitaramachandra Murthy N, Perry A (2017) Non Absorbable Suture Should be Avoided When Operating on the Biliary Tree. *Med Rep Case Stud* 2: i102. doi: [10.4172/2572-5130.1000i102](https://doi.org/10.4172/2572-5130.1000i102)

**Copyright:** © 2017 Kirby G, et al. This is an open-access article distributed under the terms of the Creative Commons Attribution License, which permits unrestricted use, distribution, and reproduction in any medium, provided the original author and source are credited.