

Fever in Thromboembolic Disease: Risk Factors, Central Venous Catheter Thrombosis and Recurrence

Beatriz Losada Vila¹, Juan Antonio Guerra Martínez, David Gutiérrez Abad and María Victoria De Torres Olombrada

Hospital University of Fuenlabrada, Madrid, Spain

^{*}Corresponding author: Losada Vila B, Hospital University of Fuenlabrada, Calle Camino del Molino, 2, 28942 Fuenlabrada, Madrid, Spain, Tel: 677098761; E-mail: beatriz.losada@salud.madrid.org

Received date: February 22, 2017; Accepted date: March 20, 2017; Published date: March 28, 2017

Copyright: © 2017 Vila BL, et al. This is an open-access article distributed under the terms of the Creative Commons Attribution License, which permits unrestricted use, distribution, and reproduction in any medium, provided the original author and source are credited.

Abstract

Thromboembolic disease (VTE) is a very important cause of morbidity and mortality in cancer patients, with a recurrence rate of 10-17% in patients treated with anti-vitamin K and 6-9% in low molecular weight heparin (LMWH). This case reflects the recurrence of VTE, differential diagnosis in the presence of pleural effusion+fever and the management of central venous catheter-associated thrombosis (CVC).

Introduction

Thromboembolic disease (VTE) is a very important cause of morbidity and mortality in cancer patients, with a recurrence rate of 10-17% in patients treated with anti-vitamin K and 6-9% in low molecular weight heparin (LMWH) [1]. The risk of relapse and rebleeding increases by 2.2 times during the first month of treatment, so we have to analyze the factors on which we can influence [1]. This case reflects on the management of recurrence of VTE and prothrombotic factors, differential diagnosis of VTE in the presence of pleural effusion+fever and central venous catheter-associated thrombosis (CVC).

Keywords: Thrombosis; Chemotherapy

Clinical Case

Patient of 63 years with dyslipemia and smoking habit of >20 cigarettes/day. Diagnosis of a left breast infiltrating ductal carcinoma GII pT2N0M0 RRHH+c-erb2- in 1999. A mastectomy was performed with axillary lymphadenectomy and adjuvant chemotherapy according to the CMF scheme, suspended in the 4th cycle due to left lower limb thrombosis. Oral anticoagulation for 8 months.

A 2 cm nodule in right quadrant at right breast was observed in the follow-up mammography at 8 years (2006), concurring a new ductal carcinoma (RRHH+, cerb2-), treated with mastectomy, lymphadenectomy and adjuvant treatment with aromatase inhibitor until February 2011 (5 years).

However, after 5 months without treatment (July 2011), she went to the emergency department for dyspnoea and fever with the appearance of right pleural effusion. Diagnostic thoracentesis was performed showing a pleural fluid with 20000 red cells/mm³, leukocytes 900 cells/mm³ (95% mononuclear cells) Proteins 4.3 g/dL, LDH 160 mg/dl and pH 7.8. Negative cytology and pleural biopsy with signs of chronic inflammation.

Possible etiologies were:

1) Tumor recurrence: (however negative pleural biopsy) 2) Infectious: no fever, nor elevation of acute phase reactants. 3) Pulmonary thromboembolism.

Thoracic CT was performed to rule out tumor involvement where lung nodules and lytic lesions were also seen. Considering the clinical picture congruent with a pleural, pulmonary and bone metastatic recurrence with a Ca 15.3 elevation, she started first line of metastatic breast cancer with weekly Paclitaxel+zoledronic acid.

In the following months (August-September 2011) she went to the emergency room on several occasions due to fever and dyspnoea without associated infectious clinic. It required evacuating thoracentesis with negative pleural biopsies (x4) so it was decided not to perform pleurodesis.

However, she presented worsening on the 7th day of admission with tachycardia, 89% oxygen saturation, and a D-dimer of 3253 ng/mL. Urgent CT-angiography showed congruent findings with acute pulmonary thromboembolism (PT). Echocardiogram showed no signs of overload at right ventricle. Because there was no contraindication for anticoagulation and no massive PT, tinzaparin (LMWH) was initiated at a dose of 14,000 IU/ML.

Again, at 6 months (February 2012) she presents with laterocervical discomfort and fever without increasing usual dyspnea. Eco Doppler Upper limbs (Figure 1): right subclavian and jugular thrombosis in relation to catheter. Analytically: Hb 10.7 and platelets 325000, so it was decided to withdraw Port-a-cath since she was already anticoagulated with tinzaparin at therapeutic doses. The dose of LMWH was increased and antiXA was monitored (always with values in normal range). Study of thrombophilia detected mutation in heterozygous protrombin gen.

In June 2012 new progression at bone and pleural levels, so treatment was changed to a second line of hormone therapy (Fulvestrant). In April 2013, there was a new lung progression and a third line of chemotherapy with Capecitabine was started, achieving a good analgesic control until a new bone progression in January 2014. At that time due to the worsening situation of the patient she was referred to Palliative Care. She died in November 2014 after 16 years of

the initial diagnosis of breast cancer and 40 months after metastatic recurrence despite a thromboembolic disease in several situations.

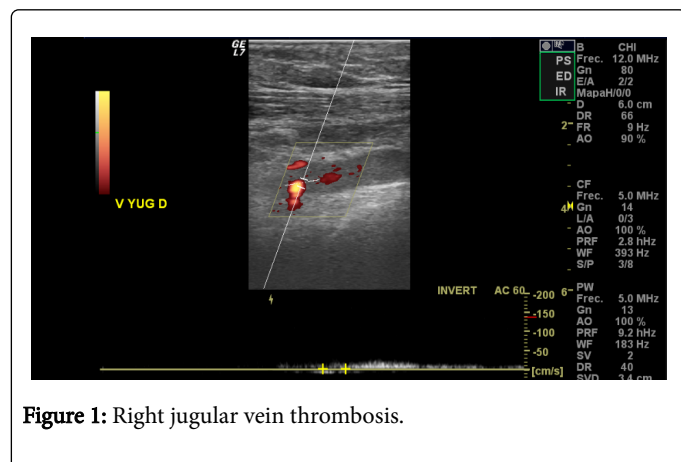


Figure 1: Right jugular vein thrombosis.

Discussion and Conclusion

-VTE incidence is increasing, due to the incorporation of new treatments (antiangiogenic) and improvement of diagnostic techniques. 12% are synchronous with the diagnosis of the tumor, being up to 18% at hospitalized patients [1,2].

- Thinking about risk factors, due to patient (procoagulant factors such as tumor-related tissue factor, also in patients with cancer, the history of thrombosis increases the risk up to 7 times compared to those who have never presented it; obesity, smoking, comorbidities, prothrombin mutation), tumor (more frequent in adenocarcinomas, advanced stage and first 3-6 months) and chemotherapy and Hormone therapy: risk of VTE 6.5 times higher [3].

- Recurrence of VTE: Cancer patients have a higher risk of recurrence (x3-4).Ottawa score assesses risk based on age, sex, type of primary tumor and stage. Two groups are established: ≤ 0 points is low risk (4.5% risk of recurrence) and >1 high (19% risk of recurrence) [4]. Our patient, being an advanced stage breast cancer with Previous VTE has a high recurrence risk.

-No evidence to support the change to another LMWH or the IVC filter (it does not reduce mortality and increase DVT).

-Anticoagulation time: There are no data on duration beyond 6 months, however recommended as long as cancer is present in metastatic disease. Essential to re-evaluate the risk/benefit [5].

References

1. Chew HK, Wun T, Harvey D, Zhou H, White R (2006) Incidence of venous thromboembolism and its effect on survival among patients with common cancers. Arch Intern Med 166: 458-464.
2. Khorana AA, Francis CW, Culakova E, Kuderer NM, Lyman GH (2007) Frequency, risk factors, and trends for venous thromboembolism among hospitalized cancer patients. Cancer 110: 2339-2346.
3. Farge D, Debourdeau P, Beckers M, Baglin C, Bauersachs RM, et al. (2013) International clinical practice guidelines for the treatment and prophylaxis of venous thromboembolism in patients with cancer. J Thromb Haemost 11: 56-70.
4. Den Exter PL, Kooiman J, Huisman MV (2013) Validation of the Ottawa prognostic score for the prediction of recurrent venous thromboembolism in patients with cancer-associated thrombosis. J Thromb Haemost 11: 998-1000.
5. Prandoni P, Lensing AW, Piccioli A, Bernardi E, Simioni P, et al. (2002) Recurrent venous thromboembolism and bleeding complications during anticoagulant treatment in patients with cancer and venous thrombosis. Blood 100: 3484-3488.