

Obstructive Sleep Apnea and Lymphocytic Sialadenitis: The Focus isn't Just Sjögren's Syndrome

Ashhad Mahmood¹, Jonathan F Lara^{1#} and Elliot D Rosenstein^{2*}

¹Department of Pathology, St. Barnabas Medical Center, Livingston, NJ, USA

²Institute for Rheumatic and Autoimmune Diseases, Overlook Medical Center, Summit, NJ, USA

#deceased

*Corresponding author: Elliot D Rosenstein, MD, Institute for Rheumatic & Autoimmune Diseases, Overlook Medical Center, 33 Overlook Road, Summit, NJ, USA, Tel: 908-598-7940; Fax: 908-598-5447; E-mail: elliott.rosenstein@atlantichhealth.org

Received date: September 25, 2015; Accepted date: October 28, 2015; Published date: October 30, 2015

Copyright: © 2015 Mahmood A, et al. This is an open-access article distributed under the terms of the Creative Commons Attribution License, which permits unrestricted use, distribution, and reproduction in any medium, provided the original author and source are credited.

Abstract

Objective: We examined the presence of lymphocytic infiltration and measured focus scores in uvular specimens of patients with obstructive sleep apnea (OSA).

Methods: We reviewed the histopathology of 101 uvular specimens obtained from patients with OSA and uvular hypertrophy. A lymphocyte focus score assessment was performed for each case.

Results: Of the 101 cases, 42 (42%) cases had a positive focus score (score ≥ 1). Of those cases with a positive focus score, 22 (52%) had a focus score of 1, 14 (33%) had a focus score of 2, 4 (9%) had a focus score of 3, and 2 (5%) had a focus score of 4. Of the 59 patients (58%) with negative focus scores, 39 (66%) had minor lymphocytic infiltrates; 17 (29%) had features of chronic sialadenitis or extensive fibrosis; 3 (5%) had salivary mucosa without any apparent lymphocytes.

Conclusion: Our findings indicate that patients with OSA may exhibit focal lymphocytic sialadenitis (FLS). It remains to be determined whether mucosal changes occur elsewhere in the oral cavity of patients with OSA. If so, the presence of OSA may complicate the histologic evaluation of Sjögren's syndrome. Further investigations to determine the prevalence of FLS in the uvulae of individuals without history of OSA, the extent of FLS elsewhere within the oral cavity of patients with OSA and the relationship between the local inflammatory reaction and the systemic consequences of OSA are needed.

Keywords: Focal lymphocytic sialadenitis; Salivary gland biopsy; Uvula; Obstructive sleep apnea; Sjögren's syndrome

Introduction

Obstructive sleep apnea (OSA) is a clinical condition characterized by uvular hypertrophy, palatal laxity and instability of the upper airway, particularly during sleep, which results in disturbed airflow and resultant oxygen desaturation. Aside from snoring and disturbed sleep, OSA has also been linked with development of hypertension and vascular thrombotic events [1,2]. Although these complications are commonly attributed to the consequences of prolonged hypoxemia, immunologic abnormalities have been identified in patients with OSA, which might contribute to the predisposition to vascular events aggravated by chronic inflammation [3,4]. Chronic inflammatory infiltrates have been identified in the uvulae and palatal mucosa of patients with OSA [5-7]. Supporting a primary immunologic function of the uvula, immunohistochemical studies of non-pathologic uvulae have demonstrated abundant tissue macrophages, $\alpha\beta$ -T cells, $\gamma\delta$ -T cells and B cells [8]. In patients with OSA, more substantial lymphocytic infiltration has been documented [5-7]. Whether this represents a non-specific response to mechanical irritation or whether there are primary immunologic events occurring within the uvula and

palatal tissue that contribute to the development of OSA remain mysterious and unanswered questions.

In contrast, Sjögren's syndrome (SS) is an autoimmune disorder, characterized by lymphocytic infiltration of exocrine glands, classically involving the lacrimal and salivary glands [9,10]. In addition to clinical presentation, serology, and objective evaluations of ocular and salivary gland function, the histopathologic focus score plays a crucial role in diagnosing SS. Both the American-European Consensus Group (AECG) classification scheme and the newly proposed American College of Rheumatology (ACR) criteria for SS include histopathology evaluation of minor salivary glands (MSG) by quantitative focus score as an objective criterion [9,10]. The focus score has been perceived to be a sensitive and specific indicator for salivary gland involvement in SS [11-14]. However, the specificity of the focus score has been called into question with reports of similar findings in patients with myasthenia gravis, diabetes mellitus, bone marrow transplant recipients, various connective tissue diseases and as a consequence of older age [15-18].

The purpose of the present study was to determine the prevalence of focal lymphocytic sialadenitis in the uvula of patients with OSA.

Materials and Methods

Study design

In order to assess the utility of the focus score, we performed a cross-sectional study of patients who had uvulopalatoplasty performed as treatment of OSA.

Study population and sampling strategy

Between 2000 and 2005, 101 uvulopalatoplasties were performed at St. Barnabas Medical Center. The indication for surgery for all patients was treatment of OSA and/or uvular hypertrophy. In general, the patients who had uvulopalatoplasty performed represent those with severe sleep apnea who had not responded to more conservative measures such as weight loss, use of intra-oral appliances and had not tolerated or benefitted from continuous positive airway pressure or similar devices [19]. Because of the retrospective nature of this study, the medical history on these patients was very limited, primarily gleaned from the cursory narratives provided at the time of hospital admission. Smoking history of the patients was not known and no serologic studies or dental or ophthalmologic evaluations were available. None of the patients were known to have SS or had been identified by their surgeons to have a history or findings of chronic xerostomia.

Measures

Although lymphocytic infiltration of the lamina propria of the soft palate and uvula has been established in patients with OSA, the presence of lymphocytic infiltration of the MSG lining the uvula had not been expressly analyzed [5]. As the uvula is extensively lined with mucinous salivary glands, areas that exhibited no outward signs of injury were reviewed. All specimens were formalin-fixed, paraffin-embedded, cut at 5 μ m, and stained with hematoxylin and eosin, per routine laboratory procedure. We assessed the presence of lymphocytic sialadenitis, having adopted the AECG definition of focus score as the number of lymphocytic foci, adjacent to normal-appearing mucous acini, containing ≥ 50 lymphocytes per 4 mm² of glandular tissue (Figures 1 and 2) [9]. The AECG does not specify the source of the MSG utilized for assessment of FLS, whereas the ACR does specify labial MSG [9,10]. We referred to cases with a focus score of ≥ 1 as being involved with focal lymphocytic sialadenitis (FLS) [12,20,21]. Although several studies have suggested multi-level examination for increased detection of FLS, focus score assessment was performed on one representative section from each case, as is current standard practice [2,22]. Cases with features of chronic sialadenitis, including dispersed lymphocytic infiltrate, diffuse glandular atrophy, and fibrosis, or those with primarily neutrophilic infiltration or neoplastic replacement were to be identified as negative and not be further assessed. Both pathologists (AM, JFL) agreed on the final score [21-23].

Statistical analysis

As there was no control group in this study, no statistical analysis were performed.

Results

All 101 specimens were retrieved from the surgical pathology laboratory and reviewed. Reflecting the male predisposition for OSA,

17 (17%) were from women and 84 (83%) were from men. Patient ages ranged from 22 to 67 years.

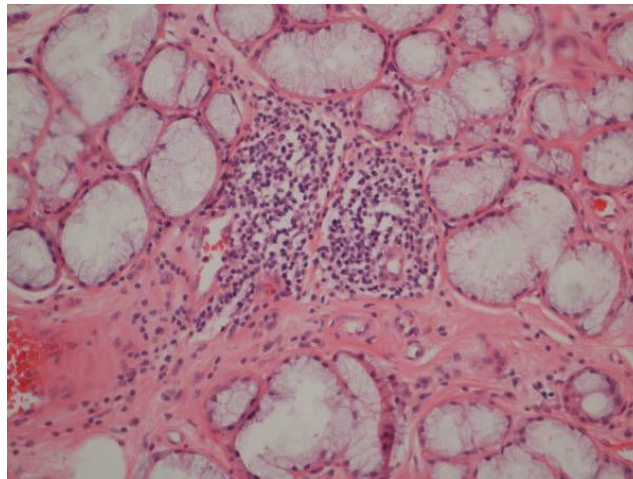


Figure 1: Mucinous glands from a uvula obtained at surgery from a patient with obstructive sleep apnea demonstrating focal lymphocytic sialadenitis (10x magnification, H&E stain).

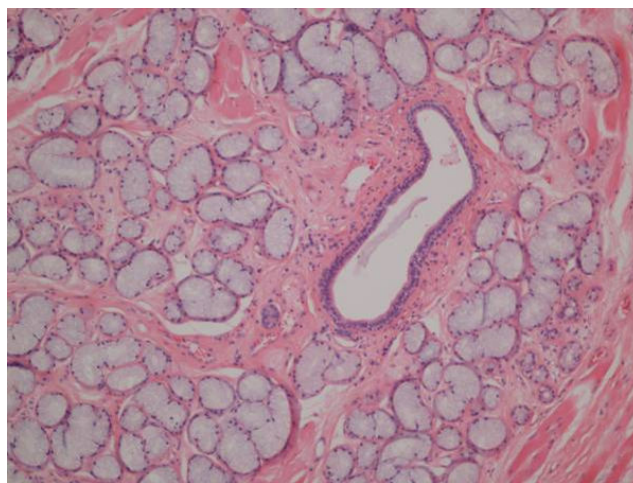


Figure 2: Normal appearing mucinous glands of the uvula obtained from the same patient as in Figure 1 (4x magnification, H&E stain).

Forty-two (42%) cases had a positive focus score. Of those cases with a positive focus score, 22 (52%) had a focus score of 1, 14 (33%) had a focus score of 2, 4 (9%) had a focus score of 3, and 2 (5%) had a focus score of 4, with no patients having a focus score greater than 4. No patient was observed to have had a germinal center present. Among female patients, 41% (7 of 17) had a positive focus score, while 42% (35 of 84) of males had a positive focus score, indicating no meaningful difference between sexes in the presence of FLS.

The degree of involvement in female patients was: 29% (2 of 7) with a focus score of 1, 29% (2 of 7) with a focus score of 2, 29% (2 of 7) with a focus score of 3, and 14% (1 of 7) with a focus score of 4. The degree of involvement in male patients was: 57% (20 of 35) with a focus score of 1, 34% (12 of 35) with a focus score of 2, 6% (2 of 35)

with a focus score of 3, and 3% (1 of 35) with a focus score of 4. When stratified by age, the mean focus score for male and female patients generally increased with age, possibly indicating age-related changes intrinsic to the uvula.

Of the 59 patients (58%) with negative focus scores, 39 (66%) had minor lymphocytic infiltrates (poorly organized or demonstrating <50 lymphocytes per 4 mm² of glandular tissue); 17 (29%) had features of chronic sialadenitis or extensive fibrosis; 3 (5%) had salivary mucosa without any apparent lymphocytes. No patients had primarily neutrophilic infiltration or neoplastic replacement of uvular tissue.

Discussion

OSA has been identified as a risk factor for development of hypertension, congestive heart failure, myocardial infarction and stroke [1,2]. Although often attributed to prolonged hypoxemia, immunologic abnormalities have been identified in patients with OSA, which may contribute to the predisposition to vascular events aggravated by chronic inflammation. Elevated levels of pro-inflammatory cytokines have been noted in the blood and saliva of patients with OSA [3,4], possibly related to lymphocytic infiltration of the uvula and palatal mucosa, previously substantiated in surgical specimens from patients with OSA [5-7]. Our findings indicate that patients with OSA may exhibit lymphocytic infiltration of the minor salivary glands within the uvula to a degree comparable to that seen on MSG biopsy in patients with SS.

Several other studies have questioned the specificity of the histologic criterion for diagnosing SS. Focus scores ≥ 1 have been reported in 18.6% of unselected postmortem cases and 15% of healthy volunteers [16-19]. FLS has also been reported in myasthenia gravis, bone marrow transplant recipients and various connective tissue diseases, but no other studies have reported focus score rates as high as 42% [18].

Although salivary gland biopsies can be performed on any tissue where salivary glands are present, and the palate is an established source, a dramatic difference in the design of our study from other studies examining focus score in non-SS patients is the examination of the uvula as the source of MSG [21]. In part due to past disregard, the function of the uvula in normal physiology remains unclear. Considerations include contributions to salivary secretion, as an accessory organ of speech, or as a site for induction of mucosal tolerance, similar to tonsillar tissues [24]. Supporting an immunologic function of the uvula, immunohistochemical studies have demonstrated abundant tissue macrophages, $\alpha\beta$ -T cells, $\gamma\delta$ -T cells, B cells and production of TGF- β . [8] In local pathologic states, such as in patients with OSA, more substantial lymphocytic infiltration has been documented, although not to the extent demonstrated in the patients presented herein [5-7]. The magnitude and consistency of the focal lymphocytic infiltration of salivary tissue in patients with OSA and the similarity with that seen in other diseases of immunologic pathogenesis may indicate that aberrant immunologic responses may be important in the development of OSA.

There are several deficiencies in this study: the retrospective nature of the analysis; the inability to assess other oral mucosal tissue from these same patients; the lack of appropriate control groups. As stated, medical histories were superficial and incomplete and there was no opportunity to initiate further inquiry regarding risks and comorbidities. Although patients were not specifically questioned regarding the presence of symptoms of SS prior to uvulectomy, the lack

of volunteered history, the absence of pre-operative findings of chronic xerostomia and the abundance of male patients make unrecognized SS less likely. As differences have been noted in the degree of lymphocytic infiltration of different oral mucosal sites [19], without benefit of labial salivary gland tissue from these patients with OSA, we are uncertain whether the changes noted in the uvula can be generalized to salivary glands elsewhere in the mouth. Appropriate control groups were not readily available as the number of uvular specimens in the surgical pathology laboratory archives obtained at the time of other surgical procedures or at the time of necropsy were exceedingly small. As such, our findings may also be characteristic of uvular tissue in normal individuals or in other clinical settings or may simply reflect age-related changes contributing to the presence of FLS as seen in non-SS patients [17,25]. Additional studies designed to examine the extent of FLS elsewhere within the oral cavity of patients with OSA, the prevalence of FLS in the uvulae of individuals without history of OSA and potential intra-oral biopsy sites among different patient populations are still required.

A recent review of the diagnostic value of MSG biopsy to assess SS reports the specificity of FLS ranging from 61.2% to 100% [14]. However, it is apparent from our results that the use of a focus score in uvular specimens from patients with OSA could confound that assessment [10,21].

Whether the elevated focus scores reflect local immunological alterations or possibly effects of chronic low-grade trauma in patients with uvular hypertrophy and OSA remains to be determined. The nature and pathologic consequences of the chronic inflammatory infiltrates seen in the uvula and palatal mucosa of patients with OSA require further investigation to determine the relationship between the local inflammatory reaction and the systemic consequences of the condition.

Contributor Ship

All three listed authors contributed to the conception and design of the study. Dr. Mahmood and Dr. Lara performed the pathological assessments. Dr. Mahmood and Dr. Rosenstein revised and provided final approval of the article, due to Dr. Lara's unfortunate death.

References

1. Bradley TD, Floras JS (2009) Obstructive sleep apnoea and its cardiovascular consequences. *Lancet* 373: 82-93.
2. Selim B, Won C, Yaggi HK (2010) Cardiovascular consequences of sleep apnea. *Clin Chest Med* 31: 203-220.
3. Medeiros CA, de Bruin VM, Andrade GM, Coutinho WM, de Castro-Silva C, et al. (2012) Obstructive sleep apnea and biomarkers of inflammation in ischemic stroke. *Acta Neurol Scand* 126: 17-22.
4. Nizam N, Basoglu OK, Tasbakan MS, Nalbantsoy A, Buduneli N (2014) Salivary cytokines and the association between obstructive sleep apnea syndrome and periodontal disease. *J Periodontol* 85: e251-258.
5. Berger G, Gilbey P, Hammel I, Ophir D (2002) Histopathology of the uvula and the soft palate in patients with mild, moderate, and severe obstructive sleep apnea. *Laryngoscope* 112: 357-363.
6. Cimino A, Speciale R, Gallina S, Cimino M, Cimino G, et al. (1995) [Morphologic and ultrastructural changes of soft palate in patients who underwent palatopharyngoplasty]. *Acta Otorhinolaryngol Ital* 15: 18-23.
7. Sekosan M, Zakkar M, Wenig BL, Olopade CO, Rubinstein I (1996) Inflammation in the uvula mucosa of patients with obstructive sleep apnea. *Laryngoscope* 106: 1018-1020.

8. Olofsson K, Hellström S, Hammarström ML (2000) Human uvula: characterization of resident leukocytes and local cytokine production. *Ann Otol Rhinol Laryngol* 109: 488-496.
9. Vitali C, Bombardieri S, Jonsson R, Moutsopoulos HM, Alexander EL, et al. (2002) Classification criteria for Sjögren's syndrome: a revised version of the European criteria proposed by the American-European Consensus Group. *Ann Rheum Dis* 61: 554-558.
10. Shiboski SC, Shiboski CH, Criswell LA, Baer AN, Challacombe S, et al. (2012) American College of Rheumatology classification criteria for Sjögren's syndrome: a data-driven, expert consensus approach in the Sjögren's International Collaborative Clinical Alliance Cohort. *Arthritis Care Res* 64: 475-487.
11. Greenspan JS, Daniels TE, Talal N, Sylvester RA (1974) The histopathology of Sjögren's syndrome in labial salivary gland biopsies. *Oral Surg Oral Med Oral Pathol* 37: 217-229.
12. Daniels TE (1984) Labial salivary gland biopsy in Sjögren's syndrome. Assessment as a diagnostic criterion in 362 suspected cases. *Arthritis Rheum* 27: 147-156.
13. Daniels TE, Whitcher JP (1994) Association of patterns of labial salivary gland inflammation with keratoconjunctivitis sicca. Analysis of 618 patients with suspected Sjögren's syndrome. *Arthritis Rheum* 6: 869-877.
14. Guellec D, Cornec D, Jousse-Joulin S, Marhadour T, Marcorelles P, et al. (2013) Diagnostic value of labial minor salivary gland biopsy for Sjögren's syndrome: a systematic review. *Autoimmun Rev* 12: 416-420.
15. Radfar L, Kleiner DE, Fox PC, Pillemer SR (2002) Prevalence and clinical significance of lymphocytic foci in minor salivary glands of healthy volunteers. *Arthritis Rheum* 47: 520-524.
16. Segerberg-Kontinen M (1989) A postmortem study of focal adenitis in salivary and lacrimal glands. *J Autoimmun* 2: 553-558.
17. Kikuchi M, Inagaki T, Ogawa K, Banno S, Matsumoto Y, et al. (2004) Histopathological investigation of salivary glands in the asymptomatic elderly. *Arch Gerontol Geriatr* 38: 131-138.
18. Hedfors E, Lindahl G (1989) Studies on the specificity of the immunohistopathological changes of the salivary glands in Sjögren's syndrome. *Clin Exp Rheumatol* 7: 163-165.
19. Walker RP (2011) Surgical treatment for snoring and obstructive sleep apnea. *Dis Mon* 57: 403-413.
20. Chisholm DM, Waterhouse JP, Mason DK (1970) Lymphocytic sialadenitis in the major and minor glands: a correlation in postmortem subjects. *J Clin Pathol* 23: 690-694.
21. Colella G, Cannavale R, Vicidomini A, Itró A (2010) Salivary gland biopsy: a comprehensive review of techniques and related complications. *Rheumatology (Oxford)* 49: 2117-2121.
22. Morbini P, Manzo A, Caporali R, Epis O, Villa C, et al. (2005) Multilevel examination of minor salivary gland biopsy for Sjögren's syndrome significantly improves diagnostic performance of AECG classification criteria. *Arthritis Res Ther* 7: 343-348.
23. Al-Hashimi I, Wright JM, Cooley CA, Nunn ME (2001) Reproducibility of biopsy grade in Sjögren's syndrome. *J Oral Pathol Med* 30: 408-412.
24. Back GW, Nadig S, Uppal S, Coatesworth AP (2004) Why do we have a uvula?: literature review and a new theory. *Clin Otolaryngol Allied Sci* 29: 689-693.
25. De Wilde PC, Baak JP, van Houwelingen JC, Kater L, Slootweg PJ (1986) Morphometric study of histological changes in sublabial salivary glands due to aging process. *J Clin Pathol* 39: 406-417.