

# Operative Technique and Literature Overview of the Lateral Access Surgery for Anterior Interbody Fusion

Luiz Pimenta<sup>1</sup>, Luis Marchi<sup>1</sup>, Fernanda Fortti<sup>1</sup>, Leonardo Oliveira<sup>1\*</sup>, Rodrigo Amaral<sup>2</sup> and Rubens Jensen<sup>1</sup>

<sup>1</sup>Instituto de Patologia da Coluna, São Paulo, Brazil

<sup>2</sup>Equilíbrio Fit&Fisio, São Paulo, Brazil

## Abstract

Based on the concept of minimally invasive spinal surgery, the retroperitoneal lateral transpsoas access was developed to approach the lumbar spine in a less invasive way. This technique allows access to the intervertebral disc laterally through the fibers of the psoas muscle. This approach is reported to offer adequate disc exposure, with the benefit of reduced iatrogenic injury to abdominal great vessels, sympathetic plexus (reducing incidence of retrograde ejaculation), and neural structures.

Here we minutely pass through the lateral interbody fusion technique, illustrate and highlight some hot points in the literature, while presenting clinical and radiological results and complications inherent to the technique.

Similarly to other minimally invasive approaches, learning curve consist a real barrier to accomplish surgery objectives. So, complete knowledge of the steps and tricks are primordial to perform and evolve this procedure. Patient positioning regards to a critical point of the surgery, when truly perpendicular way to the level has to be set. Safe crossing of the psoas muscle is assured with intraoperative use of EMG, avoiding lumbar plexus and direct neural damage. Ipsilateral and contralateral annulus release provides cortical bone support to the interbody cage at apophyseal ring to prevent cage subsidence.

The use of the lateral access has become popular and usual throughout the orthopedic and neurosurgery practice. However, as every incoming technology and technique, the users of it have to be attentive to its benefits and pitfalls.

**Keywords:** Spinal surgery; Intervertebral disc; Spondylolisthesis; Lordosis

## Introduction

Chronic low back pain has been recognized as a complex disorder, and associated with wide-ranging adverse consequences [1-3]. Patients suffering from a painful lumbar motion segment not resolved with conservative management can gain benefit from lumbar arthrodesis [4].

Lumbar spine fusion has become a commonly performed surgery, and its use continues to rise, with the annual number of spinal fusion operations increasing every year [5]. Initially, reconstructive spinal fusion surgery was used for the management of infectious conditions, adolescent scoliosis and trauma. The indications for spinal fusion among these patients have remained largely unchanged. Moreover, based on these experiences the use of spinal arthrodesis has been extended to treat degenerative lumbar disorders, spondylolisthesis and disc-related problems [6].

Anterior lumbar interbody fusion (ALIF) is the technique commonly used to achieve large discectomy and lumbar interbody arthrodesis. ALIF allows restoration of disc space, lumbar lordosis and spinal alignment, without compromising posterior tension bands [6-9]. Besides, resection of the disc eliminates one of the possible causes of discogenic back pain. Disadvantages of ALIF include the necessity of an access surgeon, injury to the great vessels and retrograde ejaculation. In addition, ALIF is associated with increased operating time and blood loss, as well as prolonged recovery time [10,11].

Less invasive surgical techniques have been demonstrated to provide a large number of benefits, which include less tissue trauma, preservation of normal anatomical structures and faster recuperative period [12].

The true lateral retroperitoneal approach may offer same clinical advantages over more traditional techniques for lumbar fusion [13,14]. This less invasive procedure realigns the endplates to a parallel position through bilateral annular release, placement of a

large implant across the disc space spanning the ring apophysis, and the effects of ligamentotaxis. The interbody grafting restores disc and foraminal heights, indirectly decompressing the neural elements and promotes stabilization through an anterior intervertebral fusion [15]. The complications related to this technique are mostly related to psoas traverse, including hip flexion weakness or numbness ipsilateral to the surgical access (psoas weakness), and less frequently sensory changes in the lower limb and abdominal wall, all resolved within 6 months [16,17]. Also, cage subsidence is frequently associated with standalone constructions or endplate injuries during discectomy. The implantation of wider interbody spacers has been proved to maximize the endplate support and allow a standalone construction with a lower incidence of severe cage subsidence, preventing its related complications [18].

## Indications and contra-indications

Indications for the lateral approach are the same as those for any interbody fusion, with the limitation of access only at disc levels above L5. Such patients typically suffer discogenic pain due to segmental instability, disc degeneration, degenerative scoliosis, and/or grade one or two spondylolisthesis [19-24]. It may also be applied to patients that have failed prior surgery and require interbody fusion, or in cases of adjacent level disease [25]. Pseudarthrosis and failed lumbar total disc replacements have also been treated using the lateral approach for retrieval and revision [26-28].

**\*Corresponding author:** Leonardo Oliveira, Instituto de Patologia da Coluna, São Paulo, Brazil, Tel: (55 11) 2936-8838, E-mail: [leonardo@patologiadacoluna.com.br](mailto:leonardo@patologiadacoluna.com.br)

**Received** July 08, 2015; **Accepted** August 06, 2015; **Published** August 08, 2015

**Citation:** Pimenta P, Marchi L, Fortti F, Oliveira L, Amaral R, et al. (2015) Operative Technique and Literature Overview of the Lateral Access Surgery for Anterior Interbody Fusion. J Spine 4: 248. doi:10.4172/2165-7939.1000248

**Copyright:** © 2015 Pimenta L, et al. This is an open-access article distributed under the terms of the Creative Commons Attribution License, which permits unrestricted use, distribution, and reproduction in any medium, provided the original author and source are credited.

The lateral approach has been successfully accomplished for levels above and including L4-5. Approaching the L5-S1 level using this technique is not recommended because the risk of iliac vessels injury as well as the difficulty of accessing the disc space due to the iliac crest. Other current indications for XLIF, with or without pedicle screw supplementation, are discogenic low back pain [29], trauma [30-34] infection [35-37] and sagittal alignment by anterior column realignment [38-42].

Contra-indications of this technique include symptomatic level at L5-S1, lumbar deformities with more than 30° of rotation, high grade degenerative spondylolisthesis (grade 3 or higher), bilateral peritoneal scarring, need for direct posterior decompression through the same approach, for example in congenital lumbar stenosis or if a second micro-decompression is not indicated [24].

## Surgical Technique

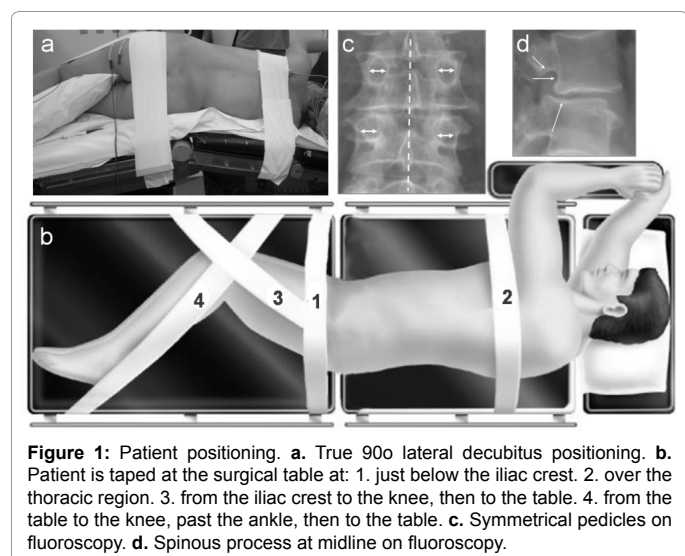
### Patient positioning

The lumbar plexus monitoring is mandatory during psoas traverse, and this is performed using surface electrodes from electromyography system (NeuroVision, NuVasive, CA, USA) that monitors four muscle groups per side: vastus medialis, anterior tibialis, biceps femoris, and medial gastrocnemius. The patient is attached into a radiopaque bendable surgical table in a direct lateral decubitus position (90°), perpendicular to the table, with the trochanter directly positioned over the table break and with legs and knees slightly bent. This configuration increases the space between iliac crest and ribs, especially relevant when accessing thoracolumbar junction or L4-L5 level (Figure 1a and 1b).

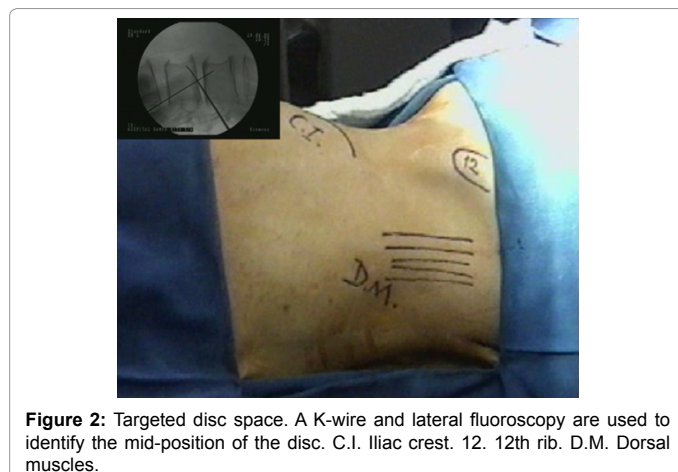
The ideal positioning is confirmed by fluoroscopy, ensuring that when at 0°, the C-arm provides a true anteroposterior (AP) image, and when at 90°, a true lateral image. It is substantial that the lateral fluoroscopic images show both vertebral plateaus and superior pedicles aligned, presented as a single line, and that the AP image reveals the spinous processes in a middle position, and pedicles as circumferences (Figure 1c and 1d).

### Lateral Retroperitoneal Access

Over the skin, the iliac crest, the transition between the last rib and the posterior abdominal wall and the quadratus lumborum muscles must be marked. After skin asepsis, the central position of the targeted disc can be identified using two Kirschner wires and lateral fluoroscopic



**Figure 1:** Patient positioning. a. True 90° lateral decubitus positioning. b. Patient is taped at the surgical table at: 1. just below the iliac crest. 2. over the thoracic region. 3. from the iliac crest to the knee, then to the table. 4. from the table to the knee, past the ankle, then to the table. c. Symmetrical pedicles on fluoroscopy. d. Spinous process at midline on fluoroscopy.



**Figure 2:** Targeted disc space. A K-wire and lateral fluoroscopy are used to identify the mid-position of the disc. C.I. Iliac crest. 12. 12th rib. D.M. Dorsal muscles.

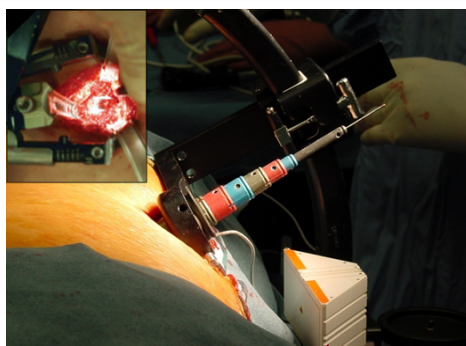
images (Figure 2), making a marking that covers the center of the affected disc space. After, a longitudinal skin incision is made, over the intersection between the posterolateral muscles of the abdominal wall (abdominal internal oblique, abdominal external oblique and transverse abdominus). A first fascia incision is made to permit the surgeon to introduce the index finger into the retroperitoneal space and gently create a pathway and releases all attachments of the peritoneum, providing a safe lateral entry. Once identified the retroperitoneal space, a second fascia incision is made below the first skin mark to introduce the initial dilator. The index finger will safely guide all dilators up to the psoas muscle, protecting abdominal structures.

### Psoas traverse

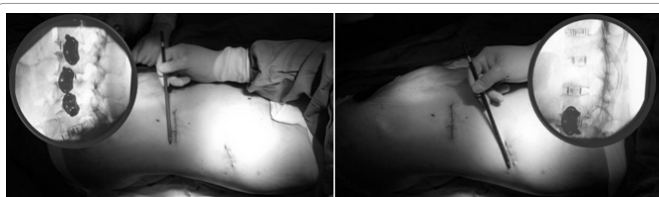The first dilator is placed upon the posterior third of the disc, as confirmed by AP and lateral fluoroscopy. Then, the fibers are gently separated by the initial blunt dilator with concomitant EMG monitoring for assessing the closeness to the lumbar plexus and allowing determining the proximity of neural structures that are adjacent to the surgical field by using a probe. The dilator must be rotated in position to determine proximity and spatial distribution of nerves. The dilators in sequence are placed over the previous, always checking the EMG, until the final placement of the retractor, still closed. The working portal is connected to a suspension arm in order to prevent unwanted movement. After confirming the ideal position by fluoroscopy, a shim goes down on the posterior blade and inserted inside the posterior portion of the disc in order to stable the position of the retractor system. Therefore, the blades can be selectively open and adjusted to the desired diameter. A bifurcated optical fiber cable is attached to the retractor for optimal direct visualization of the exposure (Figure 3). Moreover, the retractor opening must be minimal, with the shorter duration of muscle spreading as possible to prevent lack of blood flow to the nerves of the plexus and then, prevent plexopathies following the access.

### Disc space preparation

The discectomy is performed using standard instruments under direct visualization. The anterior and posterior portions of the disc containing the longitudinal ligaments must be preserved in order to keep intact the anterior and posterior longitudinal ligaments, responsible for ligamentotaxis and indirect decompression of the neural structures [15,43]. Laterolateral disc removal and contralateral ring release with a Cobb are essential to ensure symmetrical distraction, properly bilateral decompression and avoid coronal iatrogenic changes. Furthermore, this maneuver allows the placement of an implant that covers both side edges of the cortical apophyseal ring, maximizing the



**Figure 3:** Working portal with positioned dilators and retractor. Upper left is possible to see the direct visualization of the disc space provided by the opened retractor.



**Figure 4:** Case example of a 62 year-old female that underwent seven level degenerative scoliosis surgery achieved by two small incisions, with minimal blood loss and muscle damage. Patient was discharged 48 hs after surgery, without the need of drains or referral to intensive care unit.

spinal plateau support. The complete removal of cartilage and rasping the cortical bone layer provides blood precursor cells and bone growth factors that facilitate bone ingrowth.

### Device insertion

Implant proofs determine the proper cage height, length and angle that must be utilized to reach the stipulated objectives. The entire process must be guided by fluoroscopic imaging. The ideal placement is the device centered across the disc space from an AP view, and between the anterior third and middle third of the disc space from a lateral view. The ideal implant positioning also restores focal lordosis, especially at L4-L5 24.

The use of synthetic bone grafts instead of autologous bone is recommended, avoiding major postoperative morbidity. The final position of the implant must be checked by AP and lateral fluoroscopy.

### Closure

The surgical site is washed and the retractor is closed. The portal must be slowly removed in order to observe the psoas muscle closure and confirm hemostasis. The incisions are closed in a standard fashion. No drain is required. The construct may be supplemented with the internal fixation system of choice, if indicated (Figure 4).

### Postoperative care

Patients are encouraged to walk the same day accelerating their recovery and muscle function, also avoiding deep venous thrombosis and pulmonary thromboembolism. Postoperative pain tends to be minimal, and patients are usually discharged after only an overnight hospital stay.

### Current Results

Since its first description [13], the published literature into lateral access surgery brought to light greater knowledge regarding

applications and outcomes of the procedure. This includes dozens of peer-reviewed articles, and hundreds of abstracts and posters presented at the most important scientific meetings all over the world. These scientific evidences have allowed the expansion of surgical applications. Currently, the applications of lateral approach include discogenic low back pain [29], degenerative back and leg pain [44], trauma [30,33,45], infection [36], tumor [46,47] coronal and sagittal alignment [41,48-51] revision [26,27], spondylolisthesis [43,52-54], motion preservation [55], adjacent level disease [25], and others that require access to the anterior column of the thoracolumbar spine [38,56-58].

Until now, there is no prospective comparative cohort studies using minimally invasive approach for the specifically treatment of ASD. Rodgers et al. [25] conducted the only specific study regarding lateral access surgery for the treatment of ASD. They prospectively treated a series of 100 patients with adjacent segment degeneration after prior lumbar fusion using the lateral approach. From them, 79 had undergone prior instrumented posterior fusion procedures, 15 had undergone prior uninstrumented posterior fusion procedures, and 6 had undergone anterior lumbar interbody (ALIF) fusion procedures. The authors have found little intraoperative blood loss, and mean length of hospital stay was only 1.13 days. There were gains in disc height and slippage reduction in cases of spondylolisthesis. Lenke score showed good progression of fusion while clinical outcomes improved significantly in all follow up points.

Differently, literature presents several studies regarding XLIF that include patients with degenerative deformities like adult degenerative scoliosis [41,48,49,51,59-64], also including spondylolisthesis in partially or total cohort [43,52-54]. As featured, is possible to mention Rodgers et al. [54] that has operated 63 patients by lateral approach for the treatment of spondylolisthesis grade 2 using posterior supplementation, showing good clinical and radiological results. The hospital stay averaged 1.2 days, with no infections or persistent neurologic deficits. All patients achieved fusion at last follow up, with improvement in self-assessment questionnaires. They have found complications in only 3.4% of total cohort, one patient with ileus and second having a broken pedicle screw in consequence of a car accident 14 months after surgery. Marchi et al. [43] followed 52 patients that underwent XLIF surgery for the treatment of low grade spondylolisthesis, with all undergoing standalone constructions. The authors have achieved a mean surgical duration of  $73.2 \pm 31.4$  minutes (mean  $\pm$  standard deviation), with less than 50ml of blood loss and no intraoperative complications or infection. Symptoms of psoas weakness were found in 10 patients (19.2%), while 5 patients (9.6%) had anterior thigh numbness, both conditions resolved within 6 weeks after surgery without any special care. Clinical results of Visual Analogue Scale (VAS) and Oswestry Disability Index (ODI) were significantly improved. Radiological results have shown statistical significance in olisthesis reduction and improvement in global lordosis. Fusion was seen in 86.6% of total cases at last follow up, with no signals of pseudoarthrosis. Revision surgery to perform direct decompression and to place pedicle screws was necessary in 7 levels (13.5%), 5 cases in consequence of high-grade subsidence with instability/restenosis and 2 cases in which indirect decompression was not achieved. Other 4 cases of severe subsidence did not require surgical intervention.

### Complications and Management

Literature mostly shows low rate of complications in the immediate postoperative period, including hip flexion weakness or numbness ipsilateral to the surgical access (psoas weakness), and less frequently sensory changes in the lower limb, all resolved within 6 months [15,29,65]. Transient plexopathies (motor or sensory) and hip flexor



weakness are the most commonly reported complication associated with lateral access surgery. Sensory deficits are more prevalent than motor abnormalities, and transient psoas weakness is more prevalent than both. 40-90% of these cases can expect resolution of their symptoms within 90 days, very few patients have symptoms lasting more than 12 months [66,67]. Manipulation of the psoas muscle is an obvious cause of hip flexor weakness in the absence of neurological etiologies. Thus, inhibition of the muscular contraction is expected postoperatively even without any intraoperative neural damage. Otherwise, the reports did not find a higher prevalence of thigh symptoms based on the number of levels that underwent transpsoas approach, or with the utilization of multiple procedures and approaches to achieve positive outcomes.

Subsidence is another well described complication related to anterior fusion surgery. It is usually related to standalone constructs, and has been correlated to instability at the index level, possibly due to resectioning of the anterior and posterior longitudinal ligaments. Subsidence decreases distraction of the disc space and the indirect decompression of the neural structures. Also, it can cause a spinal imbalance, not reaching the proper correction of sagittal alignment. The implantation of wider interbody spacers by lateral approach has been proved to maximize the endplate support and allow a standalone construction with a lower incidence of severe cage subsidence, preventing acute pain onset, and preserving surgical gains such as disc space distraction, sagittal alignment, and their effects on neural decompression [18].

Ahmadian et al. [68] showed a literature review of lumbar plexus-related complications in 2310 patients and the most seen were thigh pain and/or numbness [16,44,55,66,69-77], hip flexor weakness [50,55,66,70-73] and quadriceps weakness [16,50,72,73,77,78]. These complications were probably secondary to direct mechanical compression, laceration, stretch, traction, or in ischemia during the procedure.

## Final Considerations

One of the biggest advantages of the lateral approach is the opportunity to insert larger implants into the densest area of the vertebral endplate, reaching both sides of the ring apophysis that enhances primary fusion. Despite its minimally invasive features, the maintenance of the longitudinal ligaments, particularly ALL, associated with the implantation of a large device results in the correction of the rotational deformity in addition to the coronal and sagittal deformities, without the risks, comorbidities and complications related to standard open surgeries. Disc height restoration has been proven to indirectly decompress the neural structures, without the need of posterior laminectomy or pedicle screw supplementation, minimizing muscle splitting, blood loss, hospital stay and operative time, improving patient's recovery and satisfaction with the procedure [79].

The older patients with significant comorbidities who are unable to tolerate large, disruptive surgeries are the biggest beneficiaries of lateral access surgery [80]. The most rewarding indications for these patients are adjacent segment degeneration and degenerative scoliosis. For adjacent level disease, the lateral approach avoids the previously operated approach pathway, either dorsally or ventrally, preventing access to scarred tissues. Moreover, the reconstruction of the anterior column is accomplished by the large interbody cage implanted laterally, that avoids injury to muscle groups accessed during the posterior approach [81], and abdominal organs and vasculature vulnerable in anterior approach [10,11].

## Conclusions

The surgical, clinical and radiological results have shown that the technique is a feasible, safe and effective approach to the lumbar spine. The complication rate has been satisfactory when compared to other surgical methods. Psoas weakness is the most common complication and results usually don't show permanent neural deficits as consequence of an adverse event. For one decade the technique has been successfully performed worldwide to achieve spinal fusion through a lateral minimal invasive approach, decreasing pain, indirectly decompressing neurological structures, restoring disc height and stopping the progression of degenerative scoliosis. However, all the benefits only would be achieved with surgeon's evolution along the procedure learning curve, which must be carefully respect.

## References

- Morlion B (2013) Chronic low back pain: pharmacological, interventional and surgical strategies. *Nat Rev Neurol* 9: 462-473.
- Golob AL, Wipf JE (2014) Low Back Pain. *Med Clin North Am* 98: 405-428.
- Dunn KM, Hestbaek L, Cassidy JD (2013) Low back pain across the life course. *Best Pract Res Clin Rheumatol*. 27: 591-600.
- Benz RJ, Garfin SR (2001) Current techniques of decompression of the lumbar spine. *Clin Orthop* (384): 75-81.
- Hart R, Hermsmeyer JT, Sethi RK, Norvell DC (2015) Quality and Quantity of Published Studies Evaluating Lumbar Fusion during the Past 10 Years: A Systematic Review. *Glob Spine J* 5: 207-218.
- Mobbs RJ, Loganathan A, Yeung V, Rao PJ (2013) Indications for anterior lumbar interbody fusion. *Orthop Surg* 5: 153-163.
- Rao PJ, Maharaj MM, Phan K, Lakshan Abeygunasekara M, Mobbs RJ (2015) Indirect foraminal decompression after anterior lumbar interbody fusion: a prospective radiographic study using a new pedicle-to-pedicle technique. *Spine J* 15: 817-824.
- Tang S, Xu W, Rebholz BJ (2012) Anterior lumbar interbody fusion combined with percutaneous pedicle screw fixation for degenerative lumbar instability: minimum four-year follow-up. *Turk Neurosurg* 22: 156-160.
- Anderson DG, Sayadipour A, Shelby K, Albert TJ, Vaccaro AR, et al. (2011) Anterior interbody arthrodesis with percutaneous posterior pedicle fixation for degenerative conditions of the lumbar spine. *Eur Spine J* 20: 1323-1330.
- Garg J, Woo K, Hirsch J, Bruffey JD, Dilley RB (2010) Vascular complications of exposure for anterior lumbar interbody fusion. *J Vasc Surg* 51: 946-950.
- Rajaraman V, Vingan R, Roth P, Heary RF, Conklin L, et al. (1999) Visceral and vascular complications resulting from anterior lumbar interbody fusion. *J Neurosurg* 91: 60-64.
- Skovrlj B, Gilligan J, Cutler HS, Qureshi SA (2015) Minimally invasive procedures on the lumbar spine. *World J Clin Cases* 3: 1-9.
- Ozgun BM, Aryan HE, Pimenta L, Taylor WR (2006) Extreme Lateral Interbody Fusion (XLIF): a novel surgical technique for anterior lumbar interbody fusion. *Spine J* 6: 435-443.
- Youssef JA, McAfee PC, Patty CA, et al. Minimally Invasive Surgery: Lateral Approach Interbody Fusion. *Spine (Phila Pa 1976)* 35: S302-S311.
- Oliveira L, Marchi L, Coutinho E, Pimenta L (2010) A Radiographic Assessment of the Ability of the Extreme Lateral Interbody Fusion Procedure to Indirectly Decompress the Neural Elements. *Spine (Phila Pa 1976)* 35: S331-S337.
- Rodgers WB, Gerber EJ, Patterson J (2011) Intraoperative and early postoperative complications in extreme lateral interbody fusion: an analysis of 600 cases. *Spine (Phila Pa 1976)* 36: 26-32.
- Uribe JS, Deukmedjian AR (2015) Visceral, vascular, and wound complications following over 13,000 lateral interbody fusions: a survey study and literature review. *Eur Spine J* 24: 386-396.
- Marchi L, Abdala N, Oliveira L, Amaral R, Coutinho E, et al. (2013) Radiographic and clinical evaluation of cage subsidence after stand-alone lateral interbody fusion. *J Neurosurg Spine* 19: 110-118.
- Tay BBK, Berven S (2002) Indications, techniques, and complications of lumbar

- interbody fusion. *Semin Neurol* 22: 221-230.
20. Regan C, Kang JD (2013) The Role of the Minimally Invasive Extreme Lateral Interbody Fusion Procedure for Complex Spinal Reconstruction. *Oper Tech Orthop* 23: 28-32.
  21. Quante M, Halm H (2015) Extreme lateral interbody fusion : Indication, surgical technique, outcomes and specific complications. *Orthopade* 44: 138-145.
  22. Patel VC, Park DK, Herkowitz HN (2012) Lateral Transposas Fusion: Indications and Outcomes. *ScientificWorldJournal* 2012: 893608.
  23. Billingshurst J, Akbarnia BA (2009) Extreme lateral interbody fusion - XLIF. *Curr Orthop Pract* 20: 238-251.
  24. Arnold PM, Anderson KK, McGuire RA Jr (2012) The lateral transposas approach to the lumbar and thoracic spine: A review. *Surg Neurol Int* 3: S198-S215.
  25. Rodgers W, Cox C, Gerber E (2008) Minimally Invasive Treatment (XLIF) of Adjacent Segment Disease after prior Lumbar Fusions. *Internet J Minim Invasive Spinal Technol* 3.
  26. Cheng WK, Jadhav V, Palmer DK (2011) A novel modification for removal of the polyethylene core in artificial disc retrieval using a transposas minimally invasive technique. *J Neurosurg Spine* 14: 466-469.
  27. Pimenta L, Díaz RC, Guerrero LG (2006) Charité lumbar artificial disc retrieval: use of a lateral minimally invasive technique. Technical note. *J Neurosurg Spine* 5: 556-561.
  28. Pimenta L (2007) Removal of a keeled TDR prosthesis via a lateral transposas retroperitoneal approach. Proceedings of the twenty second annual meeting of the North American Spine Society, Texas, USA.
  29. Marchi L, Oliveira L, Amaral R, Castro C, Coutinho T, et al. Lateral Interbody Fusion for Treatment of Discogenic Low Back Pain: Minimally Invasive Surgical Techniques. *Adv Orthop* 2012: 1-7.
  30. Amaral R, Marchi L, Oliveira L, Coutinho T, Pimenta L (2013) Acute lumbar burst fracture treated by minimally invasive lateral corpectomy. *Case Rep Orthop*. 2013: 953897.
  31. Blumenthal SL, Baker J, Dossett A, Selby DK (1988) The role of anterior lumbar fusion for internal disc disruption. *Spine (Phila Pa 1976)* 13: 566-569.
  32. Dua K, Kepler CK, Huang RC, Marchenko A (2010) Vertebral body fracture after anterolateral instrumentation and interbody fusion in two osteoporotic patients. *Spine J* 10: e11-e15.
  33. Koreckij T, Park DK, Fischgrund J (2014) Minimally invasive spine surgery in the treatment of thoracolumbar and lumbar spine trauma. *Neurosurg Focus* 37: E11.
  34. Smith WD, Dakwar E, Le TV, Christian G, Serrano S, et al. (2010) Minimally invasive surgery for traumatic spinal pathologies: a mini-open, lateral approach in the thoracic and lumbar spine. *Spine* 35: S338-S346.
  35. Baaj AA, Dakwar E, Le TV, Smith DA, Ramos E, et al. Complications of the mini-open anterolateral approach to the thoracolumbar spine. *J Clin Neurosci* 19: 1265-1267.
  36. Blizzard DJ, Hills CP, Isaacs RE, Brown CR (2015) Extreme lateral interbody fusion with posterior instrumentation for spondylodiscitis. *J Clin Neurosci Off J Neurosurg Soc Australas* S0967-5868
  37. Karikari IO, Grossi PM, Nimjee SM, Hardin C, Hodges TR, et al. (2011) Minimally invasive lumbar interbody fusion in patients older than 70 years of age: analysis of peri- and postoperative complications. *Neurosurgery* 68: 897-902.
  38. Akbarnia BA, Mundis GM Jr, Moazzaz P, Kabirian N, Bagheri R, et al. (2014) Anterior column realignment (ACR) for focal kyphotic spinal deformity using a lateral transposas approach and ALL release. *J Spinal Disord Tech* 27: 29-39.
  39. Berjano P, Cecchinato R, Sinigaglia A, Damilano M, Ismael MF, et al. Anterior column realignment from a lateral approach for the treatment of severe sagittal imbalance: a retrospective radiographic study. *Eur Spine J* 24: 433-438.
  40. Berjano P, Damilano M, Ismael M, Longo A, Bruno A, et al. (2015) Anterior column realignment (ACR) technique for correction of sagittal imbalance. *Eur Spine J* 24: 451-453.
  41. Pimenta L, Fortti F, Oliveira L, et al. (2015) Anterior column realignment following lateral interbody fusion for sagittal deformity correction. *Eur J Orthop Surg Traumatol* 25: 29-33.
  42. Turner JD, Akbarnia BA, Eastlack RK, Bagheri R, Nguyen S, et al. Radiographic outcomes of anterior column realignment for adult sagittal plane deformity: a multicenter analysis. *Eur Spine J* 24: 427-432.
  43. Marchi L, Abdala, N, Oliveira L, Amaral R, Coutinho E, et al. (2012) Stand-alone lateral interbody fusion for the treatment of low-grade degenerative spondylolisthesis. *Sci World J* 2012: 456346.
  44. Elowitz EH, Yanni DS, Chwajol M, Starke RM, Perin NI (2011) Evaluation of indirect decompression of the lumbar spinal canal following minimally invasive lateral transposas interbody fusion: radiographic and outcome analysis. *Minim Invasive Neurosurg* 54: 201-206.
  45. Berjano P, Damilano M, Lamartina C (2012) Sagittal alignment correction and reconstruction of lumbar post-traumatic kyphosis via MIS lateral approach. *Eur Spine J* 21: 2718-2720.
  46. Dakwar E, Smith WD, Malone KT, Uribe JS (2011) Minimally invasive lateral extracavitary resection of foraminal neurofibromas. *J Clin Neurosci* 18: 1510-1512.
  47. Uribe JS, Dakwar E, Le TV, Christian G, Serrano S, et al. (2010) Minimally invasive surgery treatment for thoracic spine tumor removal: a mini-open, lateral approach. *Spine* 35: S347-S354.
  48. Berjano P, Lamartina C (2013) Far lateral approaches (XLIF) in adult scoliosis. *Eur Spine J*. 22: S242-S253.
  49. Acosta FL, Liu J, Slimack N, Moller D, Fessler R, et al. (2011) Changes in coronal and sagittal plane alignment following minimally invasive direct lateral interbody fusion for the treatment of degenerative lumbar disease in adults: a radiographic study. *J Neurosurg Spine* 15: 92-96.
  50. Isaacs RE, Hyde J, Goodrich JA, Rodgers WB, Phillips FM (2010) A Prospective, Nonrandomized, Multicenter Evaluation of Extreme Lateral Interbody Fusion for the Treatment of Adult Degenerative Scoliosis. *Spine (Phila Pa 1976)* 35: S322-S330.
  51. Dangelmajer S, Zadnik PL, Rodriguez ST, Gokaslan ZL, Sciubba DM (2014) Minimally invasive spine surgery for adult degenerative lumbar scoliosis. *Neurosurg Focus* 36: E7.
  52. Khajavi K, Shen A, Hutchison A (2015) Substantial clinical benefit of minimally invasive lateral interbody fusion for degenerative spondylolisthesis. *Eur Spine J* 24: 314-321.
  53. Ahmadian A, Verma S, Mundis GM, Oskouian RJ, Smith DA, et al. (2013) Minimally invasive lateral retroperitoneal transposas interbody fusion for L4-5 spondylolisthesis: clinical outcomes. *J Neurosurg Spine* 19: 314-320
  54. Rodgers WB, Lehmen JA, Gerber EJ, Rodgers JA (2012) Grade 2 Spondylolisthesis at L4-5 Treated by XLIF: Safety and Midterm Results in the "Worst Case Scenario". *Sci World J*. 2012: 356712.
  55. Pimenta L, Oliveira L, Schaffa T, Coutinho E, Marchi L (2011) Lumbar total disc replacement from an extreme lateral approach: clinical experience with a minimum of 2 years' follow-up. *J Neurosurg Spine* 14: 38-45.
  56. Adkins DE, Sandhu FA, Voyadzis JM (2013) Minimally invasive lateral approach to the thoracolumbar junction for corpectomy. *J Clin Neurosci Off J Neurosurg Soc Australas* 20: 1289-1294.
  57. Rodgers WB, Cox CS, Gerber EJ (2010) Early Complications of Extreme Lateral Interbody Fusion in the Obese. *J Spinal Disord Tech* 23: 393-397.
  58. Uribe J, Smith W, Pimenta L, Härtl R, Dakwar E, et al. (2012) Minimally invasive lateral approach for symptomatic thoracic disc herniation: Initial multi-center clinical experience. *J Neurosurg Spine* 16: 264-279.
  59. Baghdadi YMK, Larson AN, Dekutoski MB, Cui Q, Sebastian AS, et al. (2013) Sagittal Balance and Spinopelvic Parameters Following Lateral Lumbar Interbody Fusion for Degenerative Scoliosis: A Case-Control Study. *Spine* 39: E166-173.
  60. Baghdadi YMK, Larson AN, Dekutoski MB, Cui Q, Sebastian AS, et al. (2014) Sagittal balance and spinopelvic parameters after lateral lumbar interbody fusion for degenerative scoliosis: a case-control study. *Spine* 39: E166-173.
  61. Caputo AM, Michael KW, Chapman TM, Jennings JM, Hubbard EW, et al. (2013) Extreme lateral interbody fusion for the treatment of adult degenerative scoliosis. *J Clin Neurosci* 20: 1558-1563
  62. Castro C, Oliveira L, Amaral R, Marchi L, Pimenta L (2013) Is the Lateral Transposas Approach Feasible for the Treatment of Adult Degenerative Scoliosis? *Clin Orthop Relat Res* 472: 1776-1783.
  63. Isaacs RE, Hyde J, Goodrich JA, Rodgers WB, Phillips FM (2010) A prospective, nonrandomized, multicenter evaluation of extreme lateral interbody fusion for

- the treatment of adult degenerative scoliosis: perioperative outcomes and complications. *Spine Phila Pa* 35: S322-330.
64. Phillips FM, Isaacs RE, Rodgers WB, Khajavi K, Tohmeh AG, et al. (2013) Adult Degenerative Scoliosis Treated with XLIF: Clinical and Radiographic Results of a Prospective Multi-center Study with 24-Month Follow-Up. *Spine* 38: 1853-1861.
  65. Marchi L, Oliveira L, Amaral R, Castro C, Coutinho T, et al. (2012) Anterior elongation as a minimally invasive alternative for sagittal imbalance—a case series. *HSS J* 8: 122-127.
  66. Cummock MD, Vanni S, Levi AD, Yu Y, Wang MY (2011) An analysis of postoperative thigh symptoms after minimally invasive transpoas lumbar interbody fusion. *J Neurosurg Spine* 15: 11-18.
  67. Le TV, Burkett CJ, Deukmedjian AR, Uribe JS (2013) Postoperative Lumbar Plexus Injury Following Lumbar Retroperitoneal Transpoas Minimally Invasive Lateral Interbody Fusion. *Spine* 38: E13-20.
  68. Ahmadian A, Deukmedjian AR, Abel N, Dakwar E, Uribe JS (2013) Analysis of lumbar plexopathies and nerve injury after lateral retroperitoneal transpoas approach: diagnostic standardization. *J Neurosurg Spine* 18: 289-297.
  69. Wang MY and Mummaneni PV (2010) Minimally invasive surgery for thoracolumbar spinal deformity: Initial clinical experience with clinical and radiographic outcomes. *Neurosurg Focus* 28: 1-8.
  70. Moller DJ, Slimack NP, Acosta FL, Koski TR, Fessler RG, Liu JC (2011) Minimally invasive lateral lumbar interbody fusion and transpoas approach-related morbidity. *Neurosurg Focus* 31: E4.
  71. Kepler CK, Sharma AK, Huang RC (2011) Lateral transpoas interbody fusion (LTIF) with plate fixation and unilateral pedicle screws: a preliminary report. *J Spinal Disord Tech* 24: 363-367.
  72. Sharma AK, Kepler CK, Girardi FP, Cammisa FP, Huang RC, et al. (2011) Lateral Lumbar Interbody Fusion: Clinical and Radiographic Outcomes at 1 Year: A Preliminary Report. *J Spinal Disord Tech* 24: 242-250.
  73. Tohmeh AG, Rodgers WB, Peterson MD (2011) Dynamically evoked, discrete-threshold electromyography in the extreme lateral interbody fusion approach. *J Neurosurg Spine* 14: 31-37.
  74. Dakwar E, Cardona RF, Smith DA, Uribe JS (2010) Early outcomes and safety of the minimally invasive, lateral retroperitoneal transpoas approach for adult degenerative scoliosis. *Neurosurg Focus* 28: E8.
  75. Tormenti MJ, Maserati MB, Bonfield CM, Okonkwo DO, Kanter AS (2010) Complications and radiographic correction in adult scoliosis following combined transpoas extreme lateral interbody fusion and posterior pedicle screw instrumentation. *Neurosurg Focus* 28: E7.
  76. Anand N, Rosemann R, Khalsa B, Baron EM (2010) Mid-term to long-term clinical and functional outcomes of minimally invasive correction and fusion for adults with scoliosis. *Neurosurg Focus* 28: E6.
  77. Anand N, Baron EM, Thaiyananthan G, Khalsa K, Goldstein TB (2008) Minimally invasive multilevel percutaneous correction and fusion for adult lumbar degenerative scoliosis: a technique and feasibility study. *J Spinal Disord Tech* 21: 459-467.
  78. Cahill KS, Martinez JL, Wang MY, Vanni S, Levi AD (2012) Motor nerve injuries following the minimally invasive lateral transpoas approach. *J Neurosurg Spine* 17: 227-31.
  79. Rodgers WB, Cox C, Gerber E (2007) Experience and Early Results with a Minimally Invasive Technique for Anterior Column Support Through eXtreme Lateral Interbody Fusion (XLIF®). *US Musculoskelet Rev* 2: 28-32.
  80. Rodgers WB, Gerber EJ, Rodgers JA (2010) Lumbar Fusion in Octogenarians: the promise of minimally invasive surgery. *Spine* 35: S355-360.
  81. Chrastil J, Patel AA (2010) Complications associated with posterior and transforaminal lumbar interbody fusion. *J Am Acad Orthop Surg* 20: 283-291.