

# Opioid Antagonists Enhance Diabetic Wound Closure: A New Therapy

Patricia J McLaughlin\* and Ian SZagon

Pennsylvania State University College of Medicine, Hershey PA, USA

\*Corresponding author: Patricia J McLaughlin, Pennsylvania State University College of Medicine, Hershey PA 17033, USA, Tel: 717-531-6414; E-mail: [pxm9@psu.edu](mailto:pxm9@psu.edu)

Received date: November 7, 2014, Accepted date: November 20, 2014, Published date: November 28, 2014

Copyright: © 2014 McLaughlin JP, et al. This is an open-access article distributed under the terms of the Creative Commons Attribution License, which permits unrestricted use, distribution, and reproduction in any medium, provided the original author and source are credited.

## Abstract

A major complication of type 1 or type 2 diabetes involves proper healing of cutaneous wounds. Diabetic wounds heal slowly and treatments do not mediate the underlying pathophysiology. Enkephalins are reported to be elevated in diabetes and one enkephalin, opioid growth factor (OGF), serves as an inhibitory growth factor that delays cell replication. OGF interacts with its receptor, OGF<sub>r</sub>, to mediate cellular homeostasis, including wound repair. Blockade of the inhibitory function of OGF using the antagonist naltrexone (NTX) accelerates cell proliferation in a receptor-mediated, non-toxic manner. Topical application of NTX to full-thickness cutaneous wounds in type 1 diabetic rats and type 2 diabetic mice accelerated three phases of wound closure that are normally [defective, retarded] in diabetes including initial re-epithelialization, new blood vessel formation, and establishment of granulation tissue and integrity of the skin. These data support observations that a novel biological pathway is impaired under diabetic conditions and can be corrected by topical NTX to accelerate diabetic wound healing.

**Keywords:** Opioid antagonists; Diabetes; Wound healing

## Background

Diabetes affects over 29 million individuals in the United States, with an additional 86 million Americans diagnosed with prediabetes [1]. Type 1 or type 2 diabetes remains the 7th leading cause of death in the United States either as the primary illness or contributing factor to death. In addition to hypertension, heart attack, stroke, and kidney disease, diabetes predisposes individuals to non-traumatic lower-limb amputations [2]. The economic burden of diabetes in the United States approaches \$245 billion, with approximately \$176 billion for direct medical care [1,2]. A major complication of diabetes is failure of small wounds to heal quickly and correctly, and if positioned in the foot can lead to foot ulcers, and possible amputation. Over 73,000 amputations occur in the United States annually involving adults, and an estimated 60% occur in people with diagnosed diabetes [2]. Patients with either type 1 or type 2 diabetes have increased risk of complications associated with wound repair. Additional factors that contribute to wound infection and delayed healing include vascular disease, hyperglycemia, and age [1,2]. Cells of connective tissue origin are also impaired in diabetes and because they play a significant role in repair processes, the lack of these cells exacerbates wound healing [3]. Neovascularization is an important component of wound closure and the cellular processes of angiogenesis are also impaired with hyperglycemia and/or decreased insulin availability [4].

## Cutaneous Wound Healing

Injury to the skin usually involves disturbance of both the epidermis and dermis [4-6]. The epidermis is comprised of stratified squamous epithelium that is mitotically active with an enriched source of stem cells. The dermis is deep to the epidermis and consists of the papillary and reticular layers. The papillary layer is loose connective tissue with limited collagen that supports growth of blood vessels required for healing. The reticular layer lies deep to the papillary layer and is characterized by thick, irregular connective tissue composed of type

I collagen and elastin fibers. This layer provides the tensile strength of skin and is the last region to fully repair.

An intact epithelium provides a protective barrier for underlying tissues from bacterial and viral infections [4-6]. Wound healing occurs in a series of organized events that require proliferation and transport of specialized cells into the wound site. This continuum of phases includes an initial platelet response, followed by proliferative events, angiogenesis, and many months of tissue remodeling [6]. Within 24 hr of injury, the epithelial cells begin to divide and migrate across the open surface in order to close the wound. Within hours, fibroblasts proliferate, secrete components of the extracellular matrix and provide the cellular elements required for granulation tissue to develop [6,7]. Complete re-epithelialization is finalized by proliferation of keratinocytes in order to close off the external environment from the injured region. Formation of granulation tissue to fill in the injury begins within a few days of wounding. Angiogenesis begins as well and new vessels form to transport the required cytokines to stimulate fibroblast proliferation and matrix metalloproteinases to degrade extracellular matrix. Infiltration and proliferation of mast cells, macrophages and immune cells are required for secretion of histamine, TNF $\alpha$ , FGF-2, and VEGF, which in turn stimulate angiogenesis. The next phase involves fibroblastic production of collagen and proteoglycans in order to produce cross-linked bundles of fibers that can begin to resist normal stress. This process continues for 15 – 20 days following injury. The final phase involves tissue remodeling that may continue for months until the area of injury can withstand the normal tensile strength required to regain full strength of uninjured skin.

## Diabetes and Delayed Wound Healing

Prolonged or incomplete healing of wounds results in a lack of restoration of integrity to the skin and a chronic wound [1,2,7]. Chronic wounds arise from extended diabetes (hyperglycemia) and/or aging [1,7]. In addition to the metabolic state of diabetes, infection, repeated trauma, or localized hypoxia may add to the delay of

reparation. Wound healing is often delayed in persons with diabetes because of repressed inflammatory and/or proliferation phases. Lack of adequate neutrophil and/or macrophage production can compound the defects by increasing infection rates. Finally, a repressed proliferation of epithelial cells retards wound closure. Research on treatment of wounds has targeted most phases of the wound healing process with a tremendous focus on agents that prevent inflammation and reduce scarring.

Levels of endogenous opioid expression are altered from normal, baseline levels in individuals with diabetes, as well as in rodent models of diabetes [8-14], suggesting a defect in at least one portion of the OGF-OGFr axis. Studies have shown that patients with T1D do not demonstrate any significant change in  $\beta$ -endorphin plasma levels, but present with very high plasma [Met<sup>5</sup>]-enkephalin levels. Elevated levels of [Met<sup>5</sup>]-enkephalin also have been reported in genetically obese diabetic (*db/db*) mice [14]. The diabetic condition has been reported to be accompanied by diminished nociception, and an exaggerated antinociceptive effect from exogenously administered opioids, further suggesting a role for altered opioid homeostasis in diabetes. Diabetes also is accompanied by decreased enkephalins, possibly altering their function as neurotransmitters/neuromodulators, particularly in the amacrine cells and processes within the retinal inner plexiform layer [8,9]. Current treatments for diabetic wound closure are limited [7,15,16]. Although most treatments do not target the pathophysiology of the disease, recent discoveries for bone marrow derived progenitor cells and blood vessel formation hold promise for diabetic wound repair [15,16]. The progenitor cells are mobilized by injury, travel to wound sites, and support new vessel formation [17]. Diabetic animals and humans appear to have deficiencies in the number of progenitor cells [15,17]. Treatment with AMD3100, along with PDGF-BB, an enhancer of cell growth, improved wound closure.

## Opioids, Opioid Receptors, Opioid Antagonists and Skin

Several endogenous opioids (enkephalins, endorphins, dynorphins, endomorphins) and classical ( $\mu$ /MOR/Oprm1,  $\delta$ /DOR/Oprd1,  $\kappa$ /KOR/Oprk1) opioid receptors, as well as the nuclear-associated, non-classical OGFr are present and functioning in skin [19-38]. Enkephalins such as [Met<sup>5</sup>] and [Leu<sup>5</sup>]-enkephalin and the synthetic d-Ala-d-Leu-enkephalin have been reported to inhibit cell differentiation dose-dependently in human keratinocytes in vitro, while  $\beta$ -endorphin had no effect [38]. Deletion of the classical opioid receptors in mice resulted in a phenotype of thinner epidermis and higher expression of differentiation markers, whereas a burn wound healed significantly slower in these KO mice relative to wildtype mice [31,32].

Naloxone and naltrexone (NTX) are general opioid antagonists that are devoid of intrinsic biological actions [39] and block the interaction of three opioid peptide families (prodynorphin, proopiomelanocortin, proenkephalin) and classical ( $\mu$ ,  $\delta$ ,  $\kappa$ ) as well as non-classical (OGFr) opioid receptors. NTX is longer lasting and more potent than naloxone, and has been used in numerous studies to disrupt interactions of the OGF-OGFr pathway.

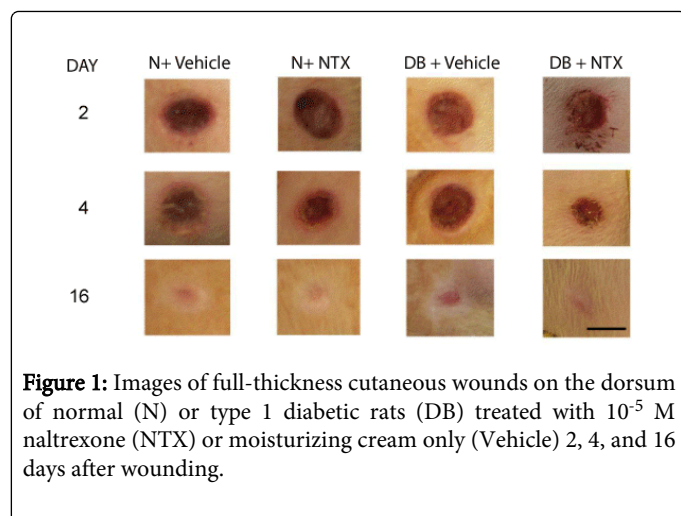
## OGF-OGFr Axis and Wound Healing in Diabetic Animals

Several of the processes in wound healing involve cell proliferation [4,6]. A regulatory pathway that mediates homeostasis of cellular proliferation is the opioid growth factor (OGF) – OGF receptor (OGFr) pathway. OGF is an endogenous pentapeptide that is chemically [Met<sup>5</sup>]-enkephalin. OGFr is a nuclear associated receptor that pharmacologically shares characteristics with classical opioid receptors, but does not have genetic or protein homology. Two of the shared characteristics are reversibility of agonist effect, and inhibition of activity by opioid antagonists. Opioid antagonists such as naloxone and NTX block interactions at classical opioid receptors as well as OGFr. OGF and OGFr are present and functioning in normal and diabetic epithelium [20, 24,26, 29].

In the last two decades, research has demonstrated that endogenous opioids serve to mediate fundamental cellular processes associated with proliferation, tissue organization, cell migration, adhesion, and cell survival [19-29]. In particular, the OGF-OGFr axis has been shown to be present and functioning as a modulator of proliferation of epithelial tissues, with OGF repressing DNA synthesis in corneal epithelium [26], palm skin [29], and cancers of ectodermal origin [40].

## Enhanced Cutaneous Wound Closure in Diabetic Animals

Several projects have been designed and completed that demonstrate delayed epithelial repair processes in diabetic animals. Moreover, topical NTX accelerates full thickness wound repair in diabetic animals [20,21,31,33]. Rats with streptozotocin-induced type 1 diabetes received topical applications of NTX ( $10^{-4}$ – $10^{-6}$  M) or vehicle in a variety of carriers. In order to determine the optimum delivery system, DNA synthesis in skin was evaluated 12 hr later [20]. To assess wound closure, diabetic and normal rats received full-thickness cutaneous wounds and were treated 3 times daily with either  $10^{-5}$  M NTX or vehicle in topical carriers. Wound sizes were analyzed, and the mechanism of action was assessed by BrdU labeling in the skin [20]. Epithelial turnover in skin of type 1 diabetic rats was markedly reduced from normal animals. However, systemic and topical application of NTX increased DNA synthesis (up to 2-fold higher) within 12 hours of administration. Topical application of NTX ( $10^{-5}$  M) in moisturizing cream resulted in significantly smaller wound areas relative to wound sizes of diabetic rats receiving only moisturizing cream 3 times daily (Figure 1). During the first 2 weeks following surgery, Normal rats receiving NTX had reductions of 6% to 26% in wound size relative to normal rats receiving vehicle. Diabetic rats receiving vehicle had 3% to 14% larger wounds relative to normal animals receiving sterile saline in vehicle, with residual wounds being up to 4-fold larger than those in the normal group (Figure 1, N +Vehicle). Reductions in residual wound size for the diabetic group treated with NTX ranged from 5% to 88% relative to the vehicle-treated diabetic rats. The mechanism of action of NTX appeared to be blockade of the OGF-OGFr axis as DNA synthesis was enhanced following NTX treatment in comparison to control levels. These data suggest that topical application of NTX is a non toxic and efficacious facilitator for healing full thickness wounds in T1D.



### Angiogenesis Phase of Wound Closure

To thoroughly investigate different phases of wound healing, granulation tissue was evaluated to ascertain other cellular targets that were impaired in diabetic wounds, including the production of new blood vessels in the region of the injury [21,22]. The number of new blood vessels immunoreactive to fibroblast growth factor-2 (FGF-2), vascular endothelial growth factor (VEGF), and alpha smooth muscle actin ( $\alpha$ -SMA) antibodies was assessed periodically (days 3, 5, 8, 10, 15 and 20 days) following full-thickness dorsal cutaneous wounding in normal and type 1 diabetic rats. Within 3 days of topical application of NTX, type 1 diabetic rats had an increase of 46% in FGF-2 positive cells relative to normal rats, and a 4-fold increase in FGF-2 stained blood vessels relative to diabetic animals receiving vehicle.

VEGF is useful for identification of endothelial cells, and expression was elevated at 3 and 5 days after wounding in both normal and diabetic rats receiving NTX. Nearly twice the number of VEGF stained cells were detected in wound tissue in these rats relative to normal animals (22 vessels/area); untreated diabetic animals had even less VEGF expression (14 vessels/area). By days 15 and 20 following the surgical wounding, the number of vessels with VEGF staining in all groups was comparable indicating the NTX did not overcompensate or create a pathological region on the skin.

A third marker indicating the growth of new blood vessels is  $\alpha$ -smooth muscle actin. Examination of granulation tissue adjacent to the wound revealed elevated expression of  $\alpha$ -smooth muscle actin on days 8 and 10 in normal tissues treated with NTX relative to vehicle treated specimens. NTX treatment altered the number of vessels with positive  $\alpha$ -smooth muscle actin reactivity in DB skin relative to both diabetic specimens treated with vehicle by as much as 2 -fold. Within a 3 week period, angiogenesis was comparable in all tissues.

### Remodeling and Wound Integrity Following Rewounding

Wound remodeling in the longest and final phase of injury repair. Remodeling involves formation of connective tissue, blood vessel formation, and development of adhesion markers indicating tissue integrity. Tensile strength was reduced for skin specimens 4 and 8 weeks after wounding in both normal and diabetic rats. Comparison of tensile strength values for skin sections from diabetic rats treated with

NTX or vehicle showed that the force required to tear the skin was significantly less in diabetic animals relative to that required to break apart skins specimens from diabetic rats treated with NTX at both 4 and 8 weeks [22]. To evaluate whether the skin of T1D rats that was previously wounded and treated with NTX exhibited any abnormal pathology, wounded regions on T1D animals that were treated with either NTX or vehicle were rewounded using the same protocol and examined 13 weeks after initiation of the studies [22].

Long-term wound repair was evaluated to determine whether NTX treatment could serve as a chronic, or recurrent, topical therapy. Sixty days following wounding, and 40 days following termination of NTX, Sirius red stained sections revealed 40% of the region had mature collagen in the normal rats and diabetic animals treated with NTX, whereas tissue specimens from diabetic rats receiving topical vehicle displayed 10% or less collagen fibers that were mature [22].

In some animals, a second wound was created to assess rates of healing following repetitive injury. After the second surgery, wounds created in skin that had previously been treated with NTX had comparable closure times to that of the first injury. Visual inspection of the skin did not reveal any histological changes between re-epithelialization of initial wounds or rewounded regions indicating that epithelial tissues were not compromised by NTX treatment. Furthermore, tensile strength testing of rewounded tissue demonstrated that neither NTX nor topical application of Vehicle alone during the first round of wounding altered the integrity of the skin, suggesting that there were no long-term changes observed after 20 days of NTX treatment.

### Summary

The OGF-OGFr regulatory pathway plays an integral role in wound closure, and modulation of the pathway by opioid antagonists enhances these processes. In the first 2 phases of wound repair, NTX accelerated DNA synthesis and increased the number of epithelial and mast cells, as well as an increase in new blood vessel formation. Remodeling was evaluated up to 8 weeks after initial wounding in type 1 diabetic rats. Comparable to the delays observed in earlier phases of repair, birefringence of granulation tissue stained with Sirius Red revealed slow collagen formation and maturation. Wound tissue from diabetic rats topically treated with NTX revealed an accelerated maturation of granulation tissue and greater integrity of wounded skin as evaluated by tensile strength. Observation of skin after 60 days post wounding revealed that the force required to tear skin of NTX-treated diabetic rats was greater than that necessary to tear the skin of vehicle-treated T1D rats, and comparable to that for normal rats. Finally, our experiments with NTX, a general and non-specific opioid antagonist, demonstrate that blockade of opioid receptors restores the delayed wound healing observed in T1D animals [4]. Such an observation implies that excessive opioid-receptor interactions are fundamental to disrupting normal repair mechanisms in T1D rats. Thus, treatment with topical NTX not only accelerated the rate of wound closure, but also stimulated growth of blood vessels and formation of granulation tissue in diabetic animals. These data support observations that a novel biological pathway is impaired under diabetic conditions and can be modulated by topical NTX to enhance proliferative events in wound healing.



## Acknowledgements

The authors acknowledge the technical work of C Pothering and J Immonen. The authors also have intellectual property assigned to Penn State University related to the use of topical naltrexone for treatment of wounds, however, they currently receive no revenue.

## References

1. National Diabetes Information Clearinghouse (NDIC)
2. Statistics About Diabetes, American Diabetes Association, USA.
3. Boulton AJ, Vileikyte L, Ragnarson-Tennvall G, Apelqvist J (2005) The global burden of diabetic foot disease. *Lancet* 366: 1719-1724.
4. Diegelmann RF, Evans MC (2004) Wound healing: an overview of acute, fibrotic and delayed healing. *Front Biosci* 9: 283-289.
5. Nguyen DT, Orgill DP, Murphy GF (2009) The pathophysiologic basis for wound healing and cutaneous regeneration, in *Biomaterials for Treating Skin Loss*, Woodhead Publishing, CRC Press, Cambridge/Boca Raton, USA.
6. Stadelmann WK, Digenis AG, Tobin GR (1998) Physiology and healing dynamics of chronic cutaneous wounds. *Am J Surg* 176: 265-385.
7. O'Loughlin A, McIntosh C, Dinneen SF, O'Brien T (2010) Review paper: basic concepts to novel therapies: a review of the diabetic foot. *Int J Low Extrem Wounds* 9: 90-102.
8. Fallucca F, Tonnarini G, Di Biase N, D'Allessandro M, Negri M (1996) Plasma met-enkephalin levels in diabetic patients: influence of autonomic neuropathy. *Metabolism* 45: 1065-1068.
9. Negri M, Tonnarini G, D'Alessandro M, Fallucca F (1992) Plasma met-enkephalin in type I diabetes. *Metabolism* 41: 460-461.
10. Wanke T, Auinger M, Formanek D, Merkle M, Lahrmann H, et al. (1996) Defective endogenous opioid response to exercise in type I diabetic patients. *Metabolism* 45: 137-142.
11. Vermes I, Steinmetz E, School J, van der Veen EA, Tilders FJ (1985) Increased plasma levels of immunoreactive beta-endorphin and corticotropin in non-insulin-dependent diabetes. *Lancet* 2: 725-726.
12. Greenberg J, Ellyin F, Pullen G, Ehrenpreis S, Singh SP, et al. (1985) Methionine-enkephalin and beta-endorphin levels in brain, pancreas, and adrenals of db/db mice. *Endocrinology* 116: 328-331.
13. Timmers K, Coleman DL, Voyles NR, Powell AM, Rökæus A, et al. (1990) Neuropeptide content in pancreas and pituitary of obese and diabetes mutant mice: strain and sex differences. *Metabolism* 39: 378-383.
14. Timmers K, Voyles NR, Zalenski C, Wilkins S, Recant L (1986) Altered  $\beta$ -endorphin, met- and leu-enkephalins, and enkephalin-containing peptides in pancreas and pituitary of genetically obese diabetic (db/db) mice during development of diabetic syndrome. *Diabetes* 35:1143-1151.
15. Allen RJ Jr, Soares MA, Haberman ID, Szpalski C, Schachar J, et al. (2014) Combination therapy accelerates diabetic wound closure. *PLoS One* 9: e92667.
16. Asahara T, Masada H, Takahashi T, Kalka C, Pastore C (1999) Bone marrow origin of endothelial progenitor cells responsible for postnatal vasculogenesis in physiological and pathological neovascularization. *Circ Res* 85:221-228.
17. Tepper OM, Capla JM, Galiano RD, Ceradini DJ, Callaghan MJ, et al. (2005) Adult vasculogenesis occurs through in situ recruitment, proliferation, and tubulization of circulating bone marrow-derived cells. *Blood* 105: 1068-1077.
18. Tepper OM, Carr J, Allen RJ, Chang CC, Lin CD (1983) Decreased circulating progenitor cell number and failed mechanisms of SDF-1 $\alpha$  mediated bone marrow mobilization impair diabetic tissue repair. *Diabetes* 59:1974.
19. McLaughlin PJ, Rogosnitzky M, Zagon IS (2010) Inhibition of DNA synthesis in mouse epidermis by topical imiquimod is dependent on opioid receptors. *ExpBiol Med (Maywood)* 235: 1292-1299.
20. McLaughlin PJ, Pothering CA, Immonen JA, Zagon IS (2011) Topical treatment with the opioid antagonist naltrexone facilitates closure of full-thickness wounds in diabetic rats. *ExpBiol Med (Maywood)* 236: 1122-1132.
21. McLaughlin PJ, Immonen JA, Zagon IS (2013) Topical naltrexone accelerates full-thickness wound closure in type 1 diabetic rats by stimulating angiogenesis. *ExpBiol Med (Maywood)* 238: 733-743.
22. Immonen JA, Zagon IS, Lewis GS, McLaughlin PJ (2013) Topical treatment with the opioid antagonist naltrexone accelerates the remodeling phase of full-thickness wound healing in type 1 diabetic rats. *ExpBiol Med (Maywood)* 238: 1127-1135.
23. Immonen JA, Zagon IS, McLaughlin PJ (2014) Topical Naltrexone as Treatment for Type 2 Diabetic Cutaneous Wounds. *Adv Wound Care (New Rochelle)* 3: 419-427.
24. McLaughlin PJ, Keiper CL, Verderame MF, Zagon IS (2012) Targeted overexpression of OGF $\alpha$  in epithelium of transgenic mice suppresses cell proliferation and impairs full-thickness wound closure. *Am J PhysiolRegulIntegr Comp Physiol* 302: R1084-1090.
25. McLaughlin PJ, Zagon IS (2012) The opioid growth factor-opioid growth factor receptor axis: homeostatic regulator of cell proliferation and its implications for health and disease. *BiochemPharmacol* 84: 746-755.
26. Zagon IS, Sassani JW, Kane ER, McLaughlin PJ (1997) Homeostasis of ocular surface epithelium in the rat is regulated by opioid growth factor. *Brain Res* 759: 92-102.
27. Zagon IS, Jenkins JB, Sassani JW, Wylie JD, Ruth TB, et al. (2002) Naltrexone, an opioid antagonist, facilitates reepithelialization of the cornea in diabetic rat. *Diabetes* 51: 3055-3062.
28. Klocek MS, Sassani JW, McLaughlin PJ, Zagon IS (2007) Topically applied naltrexone restores corneal reepithelialization in diabetic rats. *J OculPharmacolTher* 23: 89-102.
29. Zagon IS, Wu Y, McLaughlin PJ (1996) The opioid growth factor, [Met $^5$ ]-enkephalin, and the zeta opioid receptor are present in human and mouse skin and tonically act to inhibit DNA synthesis in the epidermis. *J Invest Dermatol* 106: 490-497.
30. Bigliardi PL, Büchner S, Rufli T, Bigliardi-Qi M (2002) Specific stimulation of migration of human keratinocytes by mu-opiate receptor agonists. *J Recept Signal Transduct Res* 22: 191-199.
31. Bigliardi-Qi M, Gaveriaux-Ruff C, Pfaltz K, Bady P, Baumann T, et al. (2007) Deletion of  $\mu$ - and  $\delta$ -opioid receptors in mice changes epidermal hypertrophy, density of peripheral nerve endings, and itch behavior. *J Invest. Dermatol.* 127:1479-1488.
32. Bigliardi-Qi M, Gaveriaux-Ruff C, Zhou H, Hell C, Bady P, et al. (2006) Deletion of delta-opioid receptor in mice alters skin differentiation and delays wound healing. *Differentiation* 74: 174-185.
33. Cheng B, Liu HW, Fu XB, Sheng ZY, Li JF (2008) Coexistence and upregulation of three types of opioid receptors, mu, delta and kappa, in human hypertrophic scars. *Br J Dermatol* 158: 713-720.
34. Salemi S, Aeschlimann A, Reisch N, Jüngel A, Gay RE, et al. (2005) Detection of kappa and delta opioid receptors in skin--outside the nervous system. *BiochemBiophys Res Commun* 338: 1012-1017.
35. Bigliardi PL, Sumanovski LT, Büchner S, Rufli T, Bigliardi-Qi M (2003) Different expression of mu-opiate receptor in chronic and acute wounds and the effect of beta-endorphin on transforming growth factor beta type II receptor and cytokeratin 16 expression. *J Invest Dermatol* 120: 145-152.
36. Nezami BG, Talab SS, Emami H, Assa S, Rasouli MR, et al. (2009) Chronicupregulation of the endogenous opioid system impairs the skin flap survival in rats. *Ann Plast Surg* 63: 558-563.
37. Bigliardi PL, Stammer H, Jost G, Rufli T, Büchner S, et al. (2007) Treatment of pruritus with topically applied opiate receptor antagonist. *J Am Acad Dermatol* 56: 979-988.
38. Nissen JB, Kragballe K (1997) Enkephalins modulate differentiation of normal human keratinocytes in vitro. *ExpDermatol* 6: 222-229.

- 
39. Blumberg H, Dayton HB. Naloxone, naltrexone, and related noroxymorphones in: *Narcotic Antagonists* (eds. M.C. Braude, L.C. Harris, E.L. May et al.), Raven Press, NY, USA
40. Zagon IS, Donahue RN, McLaughlin PJ (2009) Opioid growth factor-opioid growth factor receptor axis is a physiological determinant of cell proliferation in diverse human cancers. *Am J PhysiolRegulIntegr Comp Physiol* 297: R1154-1161.