

## Osteomas in a Patient with Familial Adenomatous Polyposis

Almeida FT, Leite AF, Acevedo AC and Guerra ENS\*

Laboratory of Oral Histopathology, Faculty of Health Sciences and Oral Care Center for Inherited Diseases, University of Brasilia, Brasilia, Brazil

\*Corresponding author: Dr. Eliete Neves Silva Guerra, Laboratory of Oral Histopathology, Faculty of Health Sciences and Oral Care Center for Inherited Diseases, University of Brasilia, Brasilia, Brazil, Tel: 5561-3107-3300; E-mail: elieteneves.unb@gmail.com

Rec date: July 18, 2017; Acc date: August 02, 2017; Pub date: August 07, 2017

Copyright: © 2017 Almeida FT, et al. This is an open-access article distributed under the terms of the creative commons attribution license, which permits unrestricted use, distribution, and reproduction in any medium, provided the original author and source are credited.

### Abstract

This case report aimed to characterize dento-osseous anomalies in Familial Adenomatous Polyposis (FAP) in a Brazilian patient. Furthermore, FAP was investigated for possible causative. This case report showed the importance of dento-osseous knowledge related to FAP. Early dento-osseous anomalies diagnosis revealed the need to follow-up FAP family members from childhood and was essential for subsequent clinical or genetic FAP diagnosis. The authors think that this work is important as it provides highlights about the role of the dentist in the early diagnosis of FAP, a disease that predisposes colorectal cancer.

**Keywords:** Inherited diseases; Chromosome 5q21; Colorectal polyps; Dento-osseous lesions; Bone anomalies

prevalence of FAP has been estimated to be approximately 1 in 10,000 live births [4,5].

### Introduction

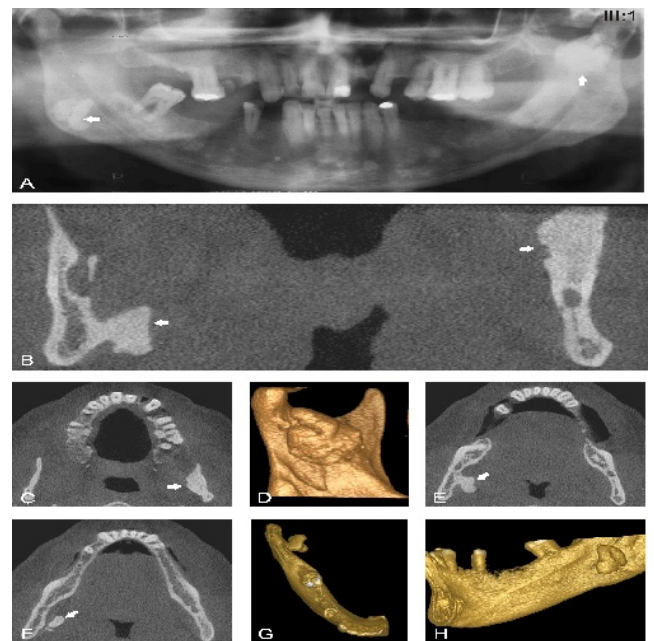
A 41-year-old male patient was referred to Oral Care Center for Inherited Diseases, University of Brasilia, Brasilia, Brazil, with a presumptive diagnosis of Temporomandibular joint (TMJ) disorders. Intraoral examination revealed pain and limited mouth opening. The medical history and general physical condition were obtained and the patient reported recent diagnosis of gastrointestinal polyps.

### Case Report

Dental panoramic radiographs revealed two radiopaque masses suggesting osteomas, one on the right mandibular angle region, and the other on the left side of the mandible, near the notch region (Figure 1A, white arrows). Furthermore, an increased diffuse radiopacity was observed in both jaw bones (Figure 1A). Based on the clinical and imaging findings, it could be concluded that the osseous changes were related to Familial Adenomatous Polyposis, rejecting the previous diagnosis of TMJ disorder. The bone anomalies and their relationship with the adjacent anatomic structures were more precisely assessed on cone-beam computed tomography scans (Figures 1B-1H). The patient was referred from Division of Coloproctology of the University Hospital of Brasilia (Brasilia, Brazil). A colonoscopy was performed following genetic analysis. A next-generation sequencing panel was made for the APC gene (Ion Ampliseq Custom Panels, Thermo Fisher) that confirmed the diagnosis of familial adenomatous polyposis.

### Discussion

Familial adenomatous polyposis (FAP) (OMIM #175100) is an autosomal dominant inherited CRC syndrome caused by a germline mutation of the adenomatous polyposis coli (APC) gene located at chromosome 5q21 [1,2]. APC is a tumor suppressor gene expressed in a variety of human tissues including colorectal epithelium, and their inactivation constitutes the initial step in the development of CRC [3]. The majority of patients with FAP have a family history. The



**Figures 1A-1H:** A: Dental panoramic radiograph showing two radiopaque masses suggesting osteomas, one on the right mandibular angle region, and the other at the left side, near the notch region (White arrows). An increased diffuse radiopacity was also observed in both jaw bones. B to H: Cone-beam computed tomography images revealing bilateral osteomas and their relationship with anatomic structures. B: Coronal reformed image. C: Axial scan. D: 3D image, superior view. E: Axial scan. F: Axial scan. G: 3D image, axial view. H: 3D image, lateral view.

In addition to colorectal manifestations, patients with FAP can develop a variety of extra colonic alterations such as other types of

cancers, gastric and duodenal polyps, desmoids tumors, hypertrophy of the retinal pigment epithelium, epidermal cysts, and oral manifestations. Oral manifestations can emerge before the development of the colorectal polyps and are reported to be present from 58% to 100% of affected individuals [6-13]. The oral manifestations of FAP include osseous jaw lesions, odontomas, supernumerary teeth, unerupted teeth, and oral mucosa alteration. A recent meta-analysis showed that the frequency of osseous jaw and dental anomalies in affected individuals were 65.35% and 30.48%, respectively [14]. There has been growing interest in characterizing these alterations because they may precede CRC and may be used as an early disease diagnostic marker [15-20].

## Conclusion

In conclusion, this case report showed the importance of studying dento-osseous lesions related to FAP. The early diagnosis of such bone anomalies reinforces the need to follow-up FAP family members from childhood and may be essential for subsequent clinical or genetic FAP diagnosis.

## References

1. Kinzler KW, Nilbert MC, Su LK, Vogelstein B, Bryan TM, et al. (1991) Identification of FAP locus genes from chromosome 5q21. *Science* 253: 661-665.
2. Groden J, Thliveris A, Samowitz W, Carlson M, Gelbert L, et al. (1991) Identification and characterization of the familial adenomatous polyposis coli gene. *Cell* 66: 589-600.
3. Goss KH, Groden J (2000) Biology of the adenomatous polyposis coli tumor suppressor. *J Clin Oncol* 18: 1967-1979.
4. Samadder NJ, Jasperson K, Burt RW (2015) Hereditary and common familial colorectal cancer: Evidence for colorectal screening. *Dig Dis Sci* 60: 734-747.
5. Bisgaard ML, Fenger K, Bulow S, Niebuhr E, Mohr J (1994) Familial adenomatous polyposis (FAP): Frequency, penetrance, and mutation rate. *Hum Mutat* 3: 121-125.
6. Campos FG, Martinez CA, Novaes M, Nahas SC, Cecconello I (2015) Desmoid tumors: Clinical features and outcome of an unpredictable and challenging manifestation of familial adenomatous polyposis. *Fam Cancer* 14: 211-219.
7. Wijn MA, Keller JJ, Giardiello FM, Brand HS (2007) Oral and maxillofacial manifestations of familial adenomatous polyposis. *Oral Dis* 13: 360-365.
8. Burt RW (2003) Gastric fundic gland polyps. *Gastroenterology* 125: 1462-1469.
9. Bertario L, Russo A, Sala P, Eboli M, Giarola M, et al. (2001) Genotype and phenotype factors as determinants of desmoid tumors in patients with familial adenomatous polyposis. *Int J Cancer* 95: 102-127.
10. Chapman PD, Church W, Burn J, Gunn A (1989) Congenital hypertrophy of retinal pigment epithelium: A sign of familial adenomatous polyposis. *BMJ* 298: 353-354.
11. Offerhaus GJ, Levin LS, Giardiello FM, Krush AJ, Welsh SB, et al. (1987) Occult radiopaque jaw lesions in familial adenomatous polyposis coli and hereditary nonpolyposis colorectal cancer. *Gastroenterology* 93: 490-497.
12. Ida M, Nakamura T, Utsunomiya J (1981) Osteomatous changes and tooth abnormalities found in the jaw of patients with adenomatosis coli. *Oral Surg Oral Med Oral Pathol* 52: 2-11.
13. Gardner EJ (1962) Follow-up study of a family group exhibiting dominant inheritance for a syndrome including intestinal polyps, osteomas, fibromas and epidermal cysts. *Am J Hum Genet* 14: 376-390.
14. Almeida FT, Pacheco-Pereira C, Porporatti AL, Flores-Mir C, Leite AF, et al. (2016) Oral manifestations in patients with familial adenomatous polyposis: A systematic review and meta-analysis. *J Gastroenterol Hepatol* 31: 527-540.
15. Edelstein DL, Giardiello FM, Basiri A, Hyland LM, Romans K, et al. (2011) A new phenotypic manifestation of familial adenomatous polyposis. *Fam Cancer* 10: 309-313.
16. Aggarwal VR, Sloan P, Horner K, Macfarlane TV, Clancy T, et al. (2003) Dento-osseous changes as diagnostic markers in familial adenomatous polyposis families. *Oral Dis* 9: 29-33.
17. Thakker N, Davies R, Horner K, Armstrong J, Clancy T, et al. (1995) The dental phenotype in familial adenomatous polyposis: Diagnostic application of a weighted scoring system for changes on dental panoramic radiographs. *J Med Genet* 32: 458-464.
18. Jarvinen HJ, Peltokallio P, Landtman M, Wolf J (1982) Gardner's stigmas in patients with familial adenomatosis coli. *Br J Surg* 69: 718-721.
19. Utsunomiya J, Nakamura T (1975) The occult osteomatous changes in the mandible in patients with familial polyposis coli. *Br J Surg* 62: 45-51.
20. Almeida FT, Leite AF, De Souza Figueiredo PT, Melo NS, Sousa JB, et al. (2012) Dento-osseous anomalies associated to familial adenomatous polyposis mimicking florid cemento-osseous dysplasia. *J Craniomaxillofac Surg* 40: 498-502.