

Pancreas Cancer: Epidemiological, Clinical, Morphological Aspects, and Therapeutic Modalities: Result of a Moroccan University Centre

Aomari A*, Firwana M, Rahaoui A, Bakkali M, Afifi R and Essaid EA

Department of Gastroenterology and Liver Diseases, Medicine C, Ibn Sina University Hospital, Rabat, Morocco

*Corresponding author: Aomari A, Department of Gastroenterology and Liver Diseases, Medicine C, IBN SINA University Hospital, Rabat, Morocco, 10100, Tel: 212653656377; E-mail: ayoub.medinterne@gmail.com

Receiving date: August 01, 2017; Accepted date: August 10, 2017; Published date: August 17, 2017

Copyright: © 2017 Aomari A, et al. This is an open-access article distributed under the terms of the Creative Commons Attribution License, which permits unrestricted use, distribution, and reproduction in any medium, provided the original author and source are credited

Abstract

Introduction: Cancer of the pancreas is one of the most aggressive solid tumors often discovered at a locally advanced or metastatic. Adenocarcinoma is the most common histological type. The aim of our study was to analyze the profile of pancreatic cancer by the various imaging techniques.

Materials and methods: Descriptive retrospective study over a period of 7 years including all patients who were followed for pancreatic cancer. The epidemiological data, clinical, morphological and treatment were collected, all the patients were hospitalized. The therapeutic decision was taken after a multidisciplinary meeting between the different specialists in the Department of Gastroenterology and liver diseases, medicine C, ibn sina hospital, Rabat, Morocco.

Results: Over a period of 7 years, 67 patients were collected. These 37 men and 30 women with a sex ratio of 1.23. The average age was 60 years (26-93 ans). 37% of patients had a history of diabetes. Clinically 43% of patients had cholestatic jaundice, 28% had abdominal pain. Clinical examination revealed an abdominal mass in 23% of cases. Abdominal ultrasound showed dilatation of the biliary tract in 67% of cases, the abdominal scanner allowed the diagnosis of pancreatic cancer in 88% of cases. The tumor site was cephalic in 67% of cases, corporeal in 7% of cases and caudal in 25% of cases. Magnetic resonance imaging (MRI) was reported in 11% of patients for suspected intra-ductal papillary mucinous neoplasms (IPMNs) or as a complement to the diagnosis. Echoendoscopy was performed in 11% of the patients as part of the locoregional extension. The average size of the tumor was 48 mm. CA19-9 was only dosed in 26 patients. It was positively positive in 65% of patients and normal in 35% of patients. Histologically, 83% had adenocarcinoma, 3% had lymphoma, 3% had neuroendocrine tumors, and 5% had degenerated IPMNs. Cancer was resectable in 9 patients (13%). The main operative contraindications were vascular and lymph node invasion in 6 patients (8%) and pulmonary or peritoneal liver metastases in 53 patients (80%). For patients with non-resectable cancer, palliative treatment was indicated either by surgical biliary drainage in 4% patients or by endoscopic insertion of biliary prosthesis in 14% of cases or by external biliary drainage in 4% of cases. Chemotherapy was indicated in 78% of patients. Therapeutic abstention was indicated in 10 patients.

Conclusion: In our study 82% of pancreatic cancers were diagnosed in the metastatic stage and 10% in locally advanced stage. The only curative treatment currently exists is surgery that has been achieved only in 8% of our patients.

Keywords: Pancreatic cancer; Diagnosis; Therapeutic modalities

radiological aspects of pancreatic cancers, and by defining some elements of the management of pancreatic cancers in this department.

Introduction

Pancreatic cancer is the 13th most common cancer in humans in the world and one of the most aggressive solid tumors [1]. It is still, the third digestive cancer in both sexes, preceding colon cancer [2]. Pancreatic cancer is dominated by exocrine pancreatic cancer. The most common histological type is adenocarcinoma in 95% of cases. Surgery remains the only curative treatment. However, only 20% of pancreatic cancers are judged to be operable at the time of diagnosis. For non-operable pancreatic cancers, several therapeutic modalities are possible either by chemotherapy, surgery or endoscopy. The aim of the work is to analyze the profile of pancreatic cancer by determining the epidemiology of pancreatic cancers in the medical department C of the Ibn Sina, Rabat Hospital, describing the clinical, biological and

Materials and Methods

Descriptive retrospective study over a period of 7 years (2009-2016) including all patients who were followed for pancreatic cancer. The epidemiological data, clinical, morphological and treatment were collected, all the patients were hospitalized. The therapeutic decision was taken after a multidisciplinary meeting between the different specialists in the Department of Gastroenterology and Liver diseases, medicine C, Ibn Sina University Hospital, Rabat, Morocco. The epidemiological, clinical and morphological data of the patients are recorded in electronic files. The quantitative variables were expressed as mean and standard deviations, the qualitative variables in numbers and in percentages. A value of $p < 0.05$ was considered significant. The analysis was performed by SPSS Software Version 15.0 (SPSS Inc.,

Chicago, IL). All patients consulted with a private gastroenterologist and then sent to the department of gastroenterology medicine C. During this hospitalization the epidemiological, clinical and morphological data are recorded in electronic files. It should be noted that this study was authorized by the head of the department and the director of Ibn Sina Rabat Hospital, Morocco.

Results

Epidemiological data

The total number of patients in this study was 67 (n=67). The average age of patients was 60 years, with a low male predominance of 55% (n=37). The sex ratio was 1.23. 25 patients (37%) had a history of diabetes, 9 patients (13%) had a history of smoking, and 3 (4%) had a history of alcoholism. No history found in 28 patients.

Clinical data

Among all patients 29 patients had cholestatic jaundice, which was isolated in 12 patients and associated with other symptoms in 17 patients. Abdominal pain was present in 19 patients (28%), isolated in 4 patients and associated with other symptoms in 15 patients, and 02 patients were asymptomatic. Clinical examination revealed abdominal mass in 15 patients (23%), hepatomegaly in 5 patients (8%), ascites in 4 patients (7%), and a large gallbladder in 02 patients.

Morphological data

Out of total patients 80% of the patients (n=54) had an abdominal ultrasound. She showed the pancreatic process with a double duct sign in 67% of the cases (n=45). In 13% of the cases (n=9) ultrasound showed an isolated dilatation of the bile ducts intra and extra-hepatic without obstacle. One patient had ultrasound signs of associated segmental portal hypertension. Abdominal CT scanner was required in 61 patients. She diagnosed pancreatic cancer in 96% of the cases (n=59). Magnetic resonance imaging (MRI) was performed in 11% of cases (n=8).

Imaging techniques	Number of patients	Visualization of pancreatic cancer	Bile ducts		Duct of Wirsung	
			Dilated	Not dilated	Dilated	Not dilated
Abdominal ultrasound	54	45	42	9	30	-
Abdominal CT scanner	61	59	59	0	59	-
Abdominal MRI	8	8	8	-	8	-
Endoscopy Ultrasound (EUS)	8	8	8	-	8	-

Table 1: Results of different imaging techniques.

It is allowed to visualize the tumor not seen on ultrasound and abdominal CT scanner in 2 patients, in whom the tumor was less than 2 cm. It was performed to refine the diagnosis of intra-ductal papillary mucinous neoplasms (IPMNs) in 2 patients, and it allowed a better appreciation of the ganglionic extension in 4 patients. Endoscopic ultrasound (EUS) was performed in 11% of patients (n=8) in whom

ultrasound and abdominal CT scanner showed no clear signs of non-resectability (Table 1). The tumor site was cephalic in 67% of cases (n=45), corporeal in 7% of cases (n=5) and caudal in 25% of cases (n=17). In one case the tumor was diffuse.

Biological data

Out of total patients 71% of patients had biological cholestasis, the tumor marker CA 19-9 was dosed in 26 patients. It was elevated in 65% of cases (n=16) and normal in 35% of cases (n=9) in our work, there was no correlation between tumor size and CA19-9.

Histological data

Among all patients 38% of patients (n=26) had histologic evidence of biopsy. There were 23 cases of adenocarcinoma, 1 case of lymphoma, 1 case of neuroendocrine tumor and 1 patient with a poorly differentiated carcinoma of which the immunohistochemistry was inconclusive. In 9 patients, the histological type was defined by the anatomopathological examination of the surgical specimen. 7 patients had an adenocarcinoma, and 1 patient had a pseudo-papillary and solid tumor (Figure 1). The diagnosis of degenerated (IPMNs) was retained on radiological techniques in 2 patients. The mean size of the tumor was 48 mm with extremes ranging from 10 mm to 10 cm.

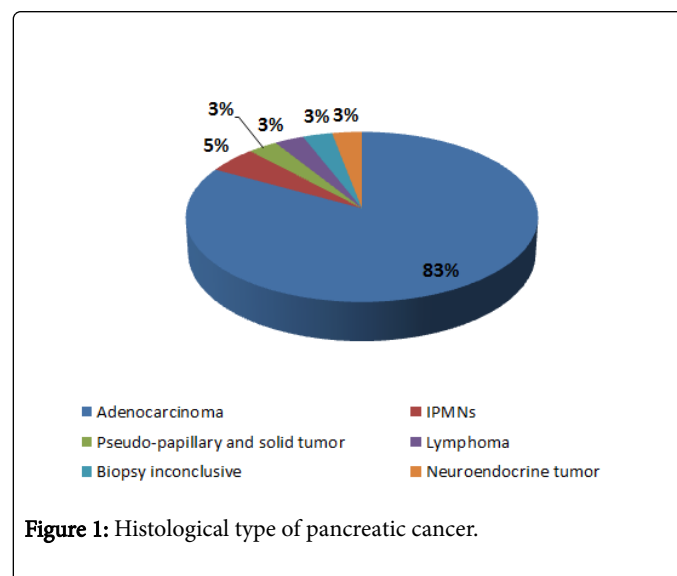


Figure 1: Histological type of pancreatic cancer.

Treatment

Of total patients, 9 patients (13%) had a localized resectable tumor without loco regional extension or distant metastasis. 58 patients (88%) had an unresectable tumor by vascular and lymph node extension without visceral metastases in 6 patients (8%), and with visceral metastases in 52 patients (80%). Curative treatment was indicated in 9 patients but only 6 patients (05 cephalic duodenopancreatotomy and caudal splenopancreatotomy in one patient). As for the 3 remaining patients, one patient was pre-operatively challenged because he had decompensated heart failure. And two patients had a contra-indication of resectability (invasion of the meso colon) discovered during surgery. The various palliative treatments indicated in our patients are described in (Table 2). For the two cases of TIPMP found in our series, one of the patients had IPMNs (intraductal papillary mucinous neoplasms) immediately metastatic:

Pulmonary and hepatic metastases and the indication of palliative chemotherapy were posed. The other patient had a resectable IPMNs, and had a curative cephalic duodeno-pancreatectomy. The evolution in this patient could not be appreciated because it was lost sight of.

Palliative treatment	Number of patients
Abstinence therapeutic	10
Palliative chemotherapy	47
Choledoco-duodenal bypass	4
Gastro-jejunal anastomosis	4
External biliary drainage	3
Biliary prosthesis	10

Table 2: Palliative treatment of pancreatic cancer.

Discussion

Pancreatic cancer is the 13th most common cancer in humans in the world [1]. In France this is the second cause of mortality from gastrointestinal cancer after colorectal cancer. At the national level, and particularly in Rabat, pancreatic cancer, accounting for 2.9% of all cancers, is ninth among male cancers and 1.8% of all cancers among women, Then twelfth place in women's cancers. It is, however, the third digestive cancer in both sexes, preceding colon cancer [2]. It is more common in men with a sex ratio of 1.6 [3] and the mean age at diagnosis is 60 years. In our study, we noted a small male predominance of 55% with a sex ratio of 1.23. The mean age of our patients was 60 years, which is identical to the data in the literature. Some risk factors have been identified as advanced age. Smoking: 20% of cancers of the pancreas are related, the risk being multiplied by 2.7 for a regular smoker. 13% of our patients (n=9) had a personal history of smoking, diabetes chronic pancreatitis, with a risk of pancreatic cancer on chronic pancreatitis is 30% to 40% [3,4]. Alcoholism in the context of chronic pancreatitis related to alcohol and other (obesity, a family history of pancreatic cancer).

Clinical symptoms are not very specific. They are more frequently represented by jaundice and abdominal pain. 43% of our patients (n=29) had jaundice and were a cephalic tumor in all of these patients. Abdominal pain was found in 28% of cases (n=15) and was the major mode of diagnosis of caudal localizations. Other clinical manifestations include diabetes, acute pancreatitis, fatty diarrhoea, signs of portal hypertension. Clinical examination seeks jaundice, abdominal mass, large gallbladder, weight loss, signs in favour of tumor extension (hepatomegaly, ascites), and signs in favour of portal hypertension. Sometimes clinical examination may be normal. In our study the clinical examination found an abdominal mass in 23% of the patients, a hepatomegaly in 8% of the patients, an ascites in 7% of the patients and a large gallbladder in 1% of the patients.

Biologically, an inflammatory syndrome may be present. In the icteric forms one can find a cholestasis, cytotoxicity, decrease of the rate of prothrombin [5]. In our series, cholestasis was present in 71% of patients (n=48). Pancreatic enzymes are normal in the majority of cases. The CA 19-9 can refine the diagnosis but of low specificity and sensitivity [6,7]. The latter was increased in 65% of our patients (n=16). In our study we did not find a correlation between the size of the tumor and the value of the CA 19-9: A 1 cm tumor had a very high CA

19-9 rate and paradoxically a tumor at 10 cm had a normal CA 19-9 rate. Radiologically, ultrasound is the first examination required before jaundice or abdominal pain. Its sensitivity for the diagnosis of pancreatic cancer is insufficient, varying between 55 and 90% according to the authors [8,9]. Its main limitations are tumors of small size <2 cm, tumors of the left pancreas and the conventional limits of ultrasound (obesity, digestive interpositions). It can show direct signs: A hypoechoic mass, with irregular contours. We recovered the pancreatic process in 67% of cases (n=45). This result is close to that of Landi et al. [10] who had recovered a pancreatic tumor in 70% of cases and that of Bengue et al. [11] in 68.8% of cases. Sometimes indirect signs are the only ones found: 20% in the literature [12] and 13% in our study (n=9). It was therefore necessary to seek dilation of the Wirsung duct (>3 mm) and dilation of the bile ducts. The abdominal scan remains the reference examination for the diagnosis of pancreatic cancer. Diagnosis is based on direct and, above all, indirect signs, sometimes only present. The direct signs to be sought are a focal mass tissue, hypodense or sometimes isodense with deformation of the contours of the gland. Indirect signs are represented by a double duct sign, which is suggestive of the diagnosis of pancreatic adenocarcinoma, parenchymatous atrophy, infiltration of peri-pancreatic fat, rupture of dilated secondary pancreatic duct. In our series the abdominal scan revealed the process of the pancreas in 88% of the cases (n=59). A result close to the data of the literature (90%) [13]. The abdominal scan also allows to study the signs of local or remote extension. Magnetic Resonance Imaging (MRI) abdominal, is indicated especially in the case of small tumors not seen with abdominal CT scan, and sometimes in the study of liver and ganglionic extension. Magnetic resonance imaging (MRI) was performed in 11% of patients (n=9). It allowed to visualize the tumor not seen on ultrasound and abdominal scan in 2 patients, in whom the tumor was less than 2 cm. It was carried out to refine the diagnosis of IPMNs (Intraductal Papillary Mucinous Neoplasms) in 2 patients and it allowed a better appreciation of the ganglionic extension in 4 patients. Endoscopic ultrasound (EUS) normal eliminates the diagnosis of pancreatic cancer. Its sensitivity ($\geq 95\%$) is independent of the size of the tumor [14,15]. It is particularly effective in the detection of small tumors of less than <2 cm and allows the realization of echo-guided biopsies. The appearance is the same as that in standard ultrasound, finding a hypoechoic mass, with irregular contours. In our study we performed Endoscopic ultrasound (EUS) in 11% of cases (n=8). It made it possible to study with precision the ganglionic extension in all these patients. PET scan (positron emission tomography) is of no interest for the moment either in the initial diagnosis or in the study of resectability [16]. It's specificity for differentiating a tumor from an inflammatory focus of chronic pancreatitis varies greatly from study (53% to 93%) [17]. It's sensitivity is insufficient for the diagnosis of peritoneal carcinoma or small metastases [18]. Histologically, a histological diagnosis should be obtained when non-surgical treatment is considered, as 10% of malignant tumors of the pancreas are not exocrine and all tumors of the pancreas are not malignant. A negative biopsy does not eliminate the diagnosis of cancer and a second biopsy attempt should be made before considering surveillance. For exocrine cancers, adenocarcinomas account for 85% of cases [5]. Other cancers are less frequent: Cystadenocarcinomas, degenerated intraductal papillary mucinous neoplasms (IPMNs) and lymphomas. In our study we found an adenocarcinoma in 85% of the cases (n=35), a degenerated IPMNs in 5% of the cases (n=2), a lymphoma in 3% of the cases (n=1), a neuroendocrine tumor in 3% (n=1) and a pseudo-papillary and solid pancreatic tumor in 3% (n=1). The treatment of pancreatic cancers is linked to the resectability or not of the tumor.

Resected cancers alone account for 10 to 20% of pancreatic cancers [19] (13% in our series), while unresectable cancers account for 35% and 50% of pancreatic cancers. In our study we found 82% of cancers diagnosed at the metastatic stage (n=52). And 10% (n=6) at the locally advanced stage. Exercise surgery, is the only curative treatment, thus concerns only 20% of the patients. This surgical treatment, which allows for a five-year survival rate of around 10% in multi-center trials, can no longer be used in isolation. Indeed, adjuvant chemotherapy makes it possible to double the survival rates to five years in two phase III trials it has become a standard and recommended in operated patients regardless of the lymph node status. Two options are possible, 5FU modulated by folic acid, or gemcitabine. On the other hand, adjuvant or neoadjuvant radio-chemotherapy has not shown any benefit in terms of survival and is no longer recommended [20]. Biliary and duodenal prostheses are an alternative to palliative surgery for the treatment of biliary and/or duodenal stenosis.

Conclusion

In our study 82% of pancreatic cancers were diagnosed in the metastatic stage and 10% in locally advanced stage. The only curative treatment currently exists is surgery that has been achieved only in 8% of our patients. Current strategies aim to improve early detection and start treatment more quickly.

References

1. Balian A (2005) *Tumor of the pancreas* (3rd edn) Paris: Vernazobres-Gregg pp: 291-298.
2. Tazi MA, Benjaafar N, Er-raki A (2009) Registry of cancers of Rabat, incidence of cancers in rabat year 2005.
3. Hammel P, Neuzillet C, Bendaoud S, Lekhal C, de Mestier L, et al. (2015) Medical treatment of pancreatic cancer: In 10 years, finally progress. *Bulletin du Cancer* 102: S62-S71.
4. Lesur G, Sauvanet A, LE Belghitti, Bernades P (1990) Cancer of the exocrine pancreas. *Hépatologie*.
5. McPhee JT, Hill JS, Whalen GF, Zayaruzny M, Litwin DE, et al. (2007) Prioperative mortality for pancreatectomy: A national perspective. *Ann Surg* 246: 246-253.
6. Menu Y (2008) Biological exploration of pancreatic tumors. *EMC Hepatology*: 1-6.
7. Buffet C (2009) Cancer of the exocrine pancreas. Clinical, diagnostic and pre-therapeutic. *Hépatologie*: 1-10.
8. Petrowsky H, Clavien PA (2005) Should we deny surgery for malignant hepato-pancreatico-biliary tumors to elderly patients. *PA World J Surg* 29: 1093-1100.
9. Campbell JB, Wilson SR (1988) Pancreatic neoplasms: How useful is evaluation with US? *Radiology* 167: 341-344.
10. Rösch T, Lorenz R, Braig C, Feuerbach S, Siewert JR, et al. (1991) Endoscopic ultrasound in pancreatic tumor diagnosis. *Gastrointest Endosc* 37: 347-352.
11. Bengue MM, Diouf ML, Pouye A, Dangou JM, Diop BM (1999) Contribution of ultrasound in the diagnosis and prognosis of pancreatic cancer in Senegal. *Jemu* 4: 225-229.
12. Conroy T, Desseigne F, Ychou M, Bouché O, Guimbaud R, et al. (2011) Folfirinox versus Gemcitabine for metastatic pancreatic cancer. *N Engl J Med* 364: 1817-1826.
13. Nishiharu T, Yamashita Y, Abe Y, Mitsuzaki K, Tsuchigame T, et al. (1999) Local extension of pancreatic carcinoma: Assessment with thin-section helical CT versus with breath-hold fast MR imaging-ROC analysis radiology. 212: 445-452.
14. Palazzo L, Roseau G, Gayet B, Vilgrain V, Belghiti J, et al. (1993) Endoscopic ultrasonography in the diagnosis and staging of pancreatic adenocarcinoma. Results of a prospective study with comparison to ultrasonography and CT scan. *Endoscopy* 25: 143-150.
15. Legmann P, Vignaux O, Dousset B, Baraza AJ, Palazzo L, et al. (1998) Pancreatic tumors: Comparison of dual-phase helical CT and endoscopic sonography. *Am J Roentgenol* 170: 1315-1322.
16. Moutardier V, Giovannini M, Magnin V, Viret F, Lelong B, et al. (2004) How to improve treatment of resectable pancreatic adenocarcinomas? Surgical resection, histopathological examination, adjuvant therapies. *Gastroenterol Clin Biol* 28: 1083-1091.
17. Coulibaly S, Kéïta K, Sissoko SB, Diallo M, Touré M, et al. (2013) Contribution of ultrasound in the diagnosis of tumors of the pancreas to the radiology service of chu of the point: *J Afr Img Med* 3: 164-1723.
18. Maire F, Sauvanet A, Trivin F, Hammel P, O'Toole D, et al. (2004) Staging of pancreatic head adenocarcinoma with spiral CT and endoscopic ultrasonography: An indirect evaluation of the usefulness of laparoscopy. *Pancreatology* 4: 436-440.
19. Krishnan S, Rana V, Janjan NA, Abbruz-zese JL, Das P, et al. (2007) Induction chemotherapy selects patients with locally advanced, unresectable pancreatic cancer for optimal benefit from consolidative chemoradiation therapy. *Cancer* 110: 47-55.
20. Seitz JF, Sibertin-blanc C, Norguet E, Dahan L (2015) What adjuvant treatment of adenocarcinoma of the pancreas today: What prospects? *Oncology* 17: 493-499.