

Case Report

Open Access

Pentasa Enema in Acute Pancreatitis Patients: A Case Report

A. Aomari*, M. Firwana, A. Rahaoui, Kh. Abdelwali, I. Benelbarhdadi and FZ Ajana

Department of Gastroenterology and Liver Diseases, IBN SINA University Hospital, Rabat, Morocco

*Corresponding author: A. Aomari, Department of Gastroenterology and Liver Diseases, IBN SINA University Hospital, Rabat, Morocco, Tel: 212653656377; E-mail: Ayoub.medinterne@gmail.com

Received date: May 09, 2017; Accepted date: May 19, 2017; Published date: May 21, 2017

Copyright: © 2017 Aomari A, et al. This is an open-access article distributed under the terms of the Creative Commons Attribution License, which permits unrestricted use, distribution, and reproduction in any medium, provided the original author and source are credited.

Abstract

Background: The aminosalicylates have a direct local anti-inflammatory effect on the mucous membrane of the small intestine and colon. They have been used for many years in the treatment of inflammatory bowel disease (IBD), these are, generally, well tolerated, however, like all drugs; they may, in rare cases, cause Side effects. We report a patient with a distal ulcerative colitis who presented with acute pancreatitis under Pentasa® enema.

Conclusion: The evolution was marked by the disappearance of pain and vomiting with normalization of lipase and enteral nutrition was retained without any difficulties. The diagnosis is pancreatitis in 5-ASA. The acute pancreatitis secondary to aminosalicylates is a very rare complication. In our case, taking the Pentasa® enema for 03 days was sufficient to cause acute inflammation of the pancreas.

Keywords: Mesalazine; Chronic inflammatory bowel disease (IBD); Acute pancreatitis

Introduction

The aminosalicylates have a direct local anti-inflammatory effect on the mucous membrane of the small intestine and colon. They have been used for many years in the treatment of inflammatory bowel disease (IBD), these are, generally, well tolerated, however, like all drugs; they may, in rare cases, cause Side effects. We report a patient with a distal ulcerative colitis who presented with acute pancreatitis under Pentasa® enema.

Case Report

This is a patient of 24 years old, without medical history, followed for a year for a distal ulcerative colitis. Initially he was treated by oral corticosteroids (Cortancyl 60 mg); the steroid dose was tapered to 20 mg with recurrence of clinical manifestations (diarrhea 08 stools/day +rectal urgency), rectosigmoidoscopy indicates exacerbation of his illness. The decision was to put the patient on a dose of 60 mg Cortancyl associated with a local treatment with Pentasa enema to reduce the rectal syndrome. The patient presented 03 days after a violent epigastric pain radiating to the back associated with bilious vomiting, with laboratory showed a lipase 7 x normal. The diagnosis of acute pancreatitis was retained with an abdominal CT scan after 48 h (Figure 1) that showed a normal sized homogeneous pancreas, (stage A of Balthazar), normal pancreas,acalculous gallbladder, and no intra or extra hepatic bile duct dilatation.

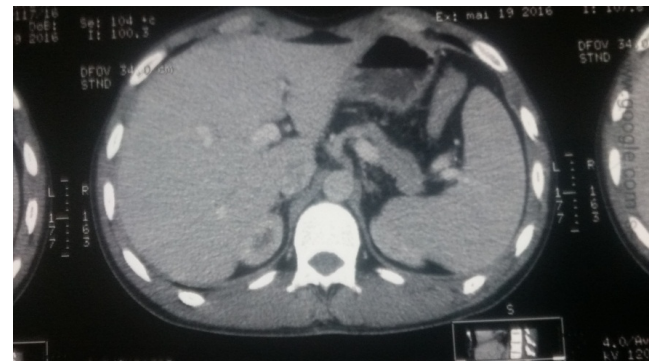


Figure 1: Scannographic image of the pancreas 48 h after onset of pain.

The calcium and triglyceride were normal, IgG4 was also normal. The patient was strictly fasted for 48 h and the Pentasa® enema suspended. The evolution was marked by the disappearance of pain and vomiting with normalization of lipase and enteral nutrition was retained without any difficulties. The diagnosis is pancreatitis in 5-ASA.

Discussion

Acute pancreatitis secondary to Mesalazine is rare. Only about fifty cases have been published in the literature [1-3]. Acute oedematous pancreatitis attributable to the treatment of chronic inflammatory bowel disease by mesalazine is rare and often benign in character. The time to onset was 12 hours to 2 days and the regression time was two days to one month. The supposed mechanism is allergic [4]. The symptoms were constantly epigastric pain, often associated with vomiting and sometimes a fever [5]. Our patients had acute pancreatitis 02 to 04 days after taking Pentasa®, with symptom

regression, and normalization of the lipase level in the blood stream 02 to 04 days after discontinuation of treatment, which is identical to the data of the literature. In 10 to 15% of cases, acute pancreatitis medications can have signs of severity and progress to a necrotic-haemorrhagic mode. The mortality observed during acute pancreatitis drug is related to the fragilized ground (cancer, immunosuppression) on which occurs the iatrogenic complication [6]. Conversely, there are clinically silent manifestations defined by the term "biological pancreatitis" resulting in an isolated serum elevation of lipase greater than three times the upper limit of normal values. The actual significance of these purely biological abnormalities in terms of pancreatotoxicity is not clearly established and the decision as to whether or not to continue drug therapy in this context is not codified [7].

Conclusion

The acute pancreatitis secondary to taking Mesalazine is a rare complication of the treatment of inflammatory bowel disease. This diagnosis should be considered in case of epigastric pancreatic-type pain installed sharply after administration of Mesalazine.

References

1. Marteau P, Cellier C (1997) Effets indésirables de l'acide 5-aminosalicylique. *Gastroenterol clin biol* 21: 377-386.
2. Marteau P, Nelet F, Devaux C (1996) Adverse events in patients treated with 5-aminosalicylic acid: 1993-1994 pharmacovigilance report for pentasa in France. *Aliment pharmacol ther* 10: 946-956.
3. Wilmink T, Frick TW (1996) Drug induced pancreatitis. *Drug safety* 14: 406-423.
4. Biour M, Daoud H, Bensalem C (2005) Pancréatotoxicité des médicaments. *Gastroenterol Clin Biol* 28: 353-359.
5. Besseau M, Delchier JC, Blazquez M, Soule JC (1999) Pancréatite aigue due à la mésalazine pentasa. *Gastroenterol Clin Biol* 15: 174.
6. Banerjee A, Patel K, Grainger S (1989) Drug induced pancreatitis: A critical review. *Med Toxicol Adverse Drug Exp* 4: 186-198.
7. Biour M, Delcenserie R, Grange JD, Weissenburger J (2001) Pancréatotoxicité des médicaments. *Gastroenterol Clin Biol* 25: 1S22-1S27.