

Percutaneous Nephrolithotomy under Thoracic Paravertebral Block: A Preliminary Report

Doaa G Ahmed^{1*}, Diab Fuad Hetta¹ and Abdelraouf M S Abdelraouf²

¹Department of Anesthesia and Pain Management, South Egypt Cancer Institute, Assuit University, Egypt

²Department of Anaesthesia and Critical Care, Assuit University, Egypt

*Corresponding author: Doaa Gomaa Sayed, Department of Anesthesiology and Pain Management, South Egypt Cancer Institute, Assiut University, Egypt, Tel: +201113607950; Fax: +20882348609; E-mail: doaa Gomaa78@yahoo.com

Received date: April 15, 2017; Accepted date: April 26, 2017; Published date: April 30, 2017

Copyright: © 2017 Ahmed DG, et al. This is an open-access article distributed under the terms of the Creative Commons Attribution License, which permits unrestricted use, distribution, and reproduction in any medium, provided the original author and source are credited.

Abstract

Background: The second look percutaneous nephrolithotomy (PCNL) is usually done under general anesthesia. Thoracic paravertebral block has been shown to provide sufficient postoperative analgesia for a variety of thoracic and upper abdominal surgeries.

Objectives: We propose a case series study for performing the second look PCNL under paravertebral block (PVB) and conscious sedation using dexmedetomidine.

Methods: 33 patients scheduled for second look PCNL received PVB at the level of T 11, 15 ml of 0.5 % of bupivacaine was injected under ultrasonographic guidance. During the procedure, the patients received conscious sedation with dexmedetomidine (initial infusion of 1 µg/kg/h, followed by a maintenance infusion of 0.2 µg/kg/h). We measured the rate of success of the anesthetic technique, the level of sedation and hemodynamics. The time to complete recovery using (MPADSS), postoperative paracetamol consumption and postoperative intensity of pain using VAS.

Results: the anesthetic technique was satisfactory in 30 patients. The median (IQ) patient's satisfaction with the anesthetic technique was 6 (6:7). The median (IQ) surgeon's satisfaction with the anesthetic technique was 7 (6:7). Complete recovery from sedation using the modified post anesthesia discharge scoring system (time to score 10) was achieved within 40 (30:52.5) min. The mean MAP and heart rate were significantly decreased in comparison to baseline value.

Conclusion: We concluded that the anesthetic technique with PVB and conscious sedation with dexmedetomidine for patients undergoing second look PCN provided sufficient sedation, adequate analgesia, minimal side effects, and rapid recovery.

Keywords: PCNL; PVB; Dexmedetomidine

Introduction

The incidence and prevalence of urolithiasis are globally increasing [1] and is considered a major healthcare concern that affects approximately 10% of the American population. [2] Percutaneous nephrolithotomy (PCNL) is currently the gold standard for treatment of patients with renal stones as it is less invasive than open surgery and is generally associated with lower morbidity and faster recovery [3].

PCNL is a percutaneous extraction of renal stone >2 cm with a nephroscope, through a small incision, in the patient's back on the side overlying the affected kidney. It is usually done under general anesthesia and sometimes neuraxial anesthesia [4-6].

Unfortunately, missed stones after PCNL are not uncommon [7]. According to the size of the remained stone, it could be managed by ESWL or if it is larger enough, it should be picked up through another session of PCNL what is called "a second look PCNL". Anesthetic management for a second look PCNL ranges from intravenous sedation for a small stone that can be extracted easily by dormia basket

to general anesthesia for larger stones that needs further disintegration. Indeed, re-exposure to general anesthesia for second look PCNL especially in prone position has its own hazards [4]. While many of the issues related to positioning are resolved with neuraxial anesthesia, hypotension is still a major concern [6].

Thoracic paravertebral block has been shown to provide sufficient postoperative analgesia for a variety of thoracic and upper abdominal surgeries [8-14].

The aim of this study is to provide alternative anesthetic technique other than general and neuraxial anesthesia for patients undergoing a second look PCNL that is paravertebral block and conscious sedation using dexmedetomidine.

Methods

The ethical committee of the faculty of medicine, Assiut University approved a feasibility study in 33 patients (IRB NO; IRB0008718) who gave written informed consent for the procedure and the study.

The inclusion criteria included patients, classified as American Society of Anesthesiologists (ASA) physical status class I and II, aged 20 to 70 years and scheduled for second look PCNL for removal of residual renal stones that needs disintegration, (multiple stones or solitary stone >2 mm). The exclusion criteria included patients with mental dysfunction, morbid obesity, a history of substance abuse, chronic analgesic use, and a history of allergy to the study drugs.

During the preoperative visit, it was made very clear to all patients that any pain, discomfort, or anxiety would be dealt with, immediately by the administration, on their request, of a potent analgesic or, if they preferred, conversion to general anesthesia. Similarly, the surgeons were instructed to ask for general anesthesia if they felt that the anesthetic technique was adding to the technical difficulty of the procedure. Also, the patients were instructed how to evaluate their pain intensity using VAS (visual analogue scale) scored from 0 to 10 where 0=no pain and 10=worst pain imaginable.

On arrival to the preoperative room, an IV catheter was inserted and a baseline measurement of vital signs was recorded.

The PVB was performed under ultrasonographic guidance in the sitting position. Surgical disinfection of thoracoabdominal paravertebral area was done. A linear high-frequency transducer (10-12 MHz, Sonosite, Bothell, WA, USA) was used. The scanning process (Longitudinal out-of-plane technique) was started at 5-10 cm lateral to the spinous process of T11 to identify the rounded ribs and parietal pleura underneath. The transducer is then moved progressively more medially until the transverse processes are identified as more squared structure deeper to the ribs. Once the transverse processes were identified, skin infiltration with 2 ml of 1% lidocaine was done. A 100 mm needle (Stimuplex D, B Braun, Melsungen AG, Germany) was inserted out-of-plane to contact the transverse process of T11 and then, walked off above the transverse process 1-1.5 cm deeper searching for loss of resistance injecting 15 ml of 0.5% bupivacaine in incremental doses of 5 ml. This will result in a displacement of the parietal pleura. Test of the block was done by pinprick examination every 3 min in the ipsilateral flank area in comparison to the other side. Failure to obtain loss of pinprick sensation within 20 min was considered a failed block. After confirmation of the success of the block, the patient was transferred to the operating room, monitoring probes were attached, the patient was turned to the prone position and conscious sedation was started. To minimize variations in the technique, all the blocks were done by the same experienced investigator. Conscious sedation entailed IV administration of dexmedetomidine, infused initially over 10 min at 1 µg/kg/h, maintained at 0.2 µg/kg/h and manipulated to keep the sedation level, assessed by the modified observer of alertness and sedation (OAA/S) scale at level 3.

During the procedure, if SpO₂ was ≤ 90%, bradycardia (HR<50 beat/min), and hypotension (MAP<50 mmHg), 4 L/min of oxygen was supplemented *via* a nasal cannula, IV 0.01 mg/kg atropine was administered, and IV 6 mg ephedrine was given, respectively.

10 minutes following the beginning of dexmedetomidine infusion and after reaching the conscious sedation state, the technique of PCNL was started by cutting the nephrostomy tube at the skin level, a guide wire is inserted in the collecting system, the remaining part of nephrostomy tube is taken off, a nephroscope is passed alongside the guide wire and the process of disintegration is started.

If the patient complained of pain (VAS>3) or discomfort, we administered IV 50 µ fentanyl boluses, if the problem is not resolved,

the patient is turned supine and received general anesthesia with endotracheal intubation and we reported it as failed anesthetic technique.

After the end of the procedure, all the patients were admitted to the post-anaesthesia care unit (PACU) for one day follow up. Patients' satisfaction with sedation and analgesia was performed after recovery from sedation, also the surgeons were asked to rate their satisfaction with patient sedation at the end of surgery.

Postoperative analgesia consisted of 1 gm. Paracetamol infusion once requested by the patients. The limiting dose was 4 g/day. If the patient was still complaining of pain, 0.1 mg/kg nalbuphine was administered. All postoperative data was reported by a nurse blinded to the study protocol.

The following parameters have been assessed.

- The intensity of pain using VAS measured postoperatively at the following time points, 0 h, 2 h, 4 h, 6 h, 10 h, 16 h and 24 h.
- The vital signs including MAP and heart rate measured immediately before dexmedetomidine infusion and each five minutes till end of the procedure and postoperatively at the following time points, 30 min, 60 min and 90 min. SpO₂ less than 90% during the procedure and till 90 min postoperatively is recorded
- The level of sedation using the modified observer of alertness and sedation (OAA/S) scale, assessed every five minutes intraoperatively and at 30 min, 60 min and 90 min postoperatively.
- The level of recovery from sedation was studied using the modified post anesthesia discharge scoring system (MPADSS) [15]. Time to reach a score of 10 was reported.
- The level of satisfaction of the patients and the surgeons with the procedure assessed by Likert-like verbal rating scale, where: Extremely dissatisfied=1. Dissatisfied=2. Somewhat dissatisfied=3. Undecided=4. Somewhat satisfied=5. Satisfied=6. Extremely Satisfied=7
- The time to first analgesic request and the first 24 h analgesic consumption were recorded.

Statistical analysis

Statistical analysis was carried out on a personal computer using SPSS version 20 software. Normally distributed data was expressed as mean ± SD, where categorical and skewed data were expressed as median ± (IQ) range. Comparison of VAS pain score at each time point was compared with baseline using student's t test.

Results

33 patients were recruited for second look PCNL under PVB and conscious sedation with dexmedetomidine, the demographic data of the patients are shown in (Table 1), the procedure was successful in 30 patients, one patient is excluded due to block failure and another 2 patients are excluded due to intraoperative pain necessitating IV fentanyl administration (200 µ).

The median (IQ) patient's satisfaction with the anesthetic technique was 6 (6:7). The median (IQ) surgeon's satisfaction with the anesthetic technique was 7 (6:7), (Table 2). The level of sedation assessed by OAA/S score was maintained at the level 3 most of the time during the procedure and returned to level 5 within 30 min postoperatively (Figure 1).

Variable	Value
Age (year)	36 ± 7
Sex, M/F	18/12
BMI (kg/m ²)	25 (20-30)
ASA grade, I/II	27/3
BMI: Body Mass Index; ASA: American Society of Anesthesiologists; M/F: Male/Female	

Table 1: Demographic data and patients characteristics.

Variable	Value
Operative duration (min) (mean ± SD)	46 ± 5.5 (35-50)
Failed anesthetic technique (n)	3
Failed block (n)	1
Patient received fentanyl (n)	2
Patient received general anesthesia (n)	0
Patient satisfaction score, median (IQ)	6 (6:7)
Surgeon satisfaction score, median (IQ)	7 (6:7)
Time to aldrete score 10, (min), median (IQ)	40 (30:52.5)

Table 2: Procedure characteristics and overall satisfaction.

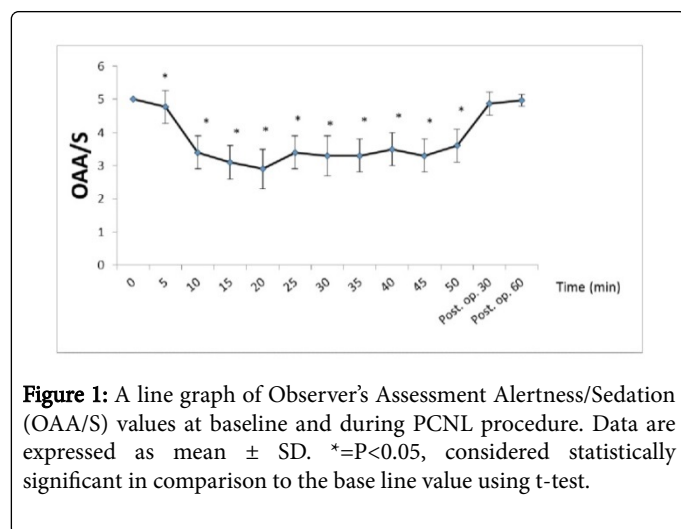


Figure 1: A line graph of Observer's Assessment Alertness/Sedation (OAA/S) values at baseline and during PCNL procedure. Data are expressed as mean ± SD. * $P < 0.05$, considered statistically significant in comparison to the base line value using t-test.

Complete recovery from sedation (time to score 10) was achieved within 40 (30:52.5) min (Table 2). The mean MAP was significantly decreased in comparison to baseline value starting from 5 min after initial infusion of dexmedetomidine till the end of the procedure while no significant reduction was observed at the following time points 30, 60 and 90 min postoperatively (Figure 2).

None of the patients developed severe hypotension (mean BP < 50 mmHg) necessitating treatment. The mean heart rate was significantly decreased in comparison to baseline value starting from 5 min after

initial infusion of dexmedetomidine till 30 min postoperatively, while no significant reduction was observed at the following time points 60 and 90 min postoperatively (Figure 2).

Two patients developed bradycardia and successfully treated with atropine. Two patients developed oxygen desaturation ($SpO_2 < 90\%$) and successfully managed with nasal oxygen administration (Table 3). The patients required analgesic (paracetamol) in the first 24 h postoperatively were 8 (26.7 %) (Table 4).

Variable	Value
Hypotension (mean BP < 50) (n) %	0
Bradycardia (pulse < 50) (n) %	2 (6.67)
Oxygen desaturation ($SpO_2 < 90\%$) (n) %	2 (6.67)
Dry mouth (n) %	6 (20%)
Nausea (n) %	3 (10 %)
Vomiting (n) %	1 (3.33%)

Table 3: Adverse events.

Variable	Value
VAS 0 h	1 (0:1)
VAS 2 h	1 (1:2)
VAS 4 h	2 (1:2)
VAS 6 h	2 (1:2)
VAS 10 h	2 (2:2)
VAS 16 h	2 (1:3)
VAS 24 h	2 (2:3)
Patients required analgesic in 24 h (n)	8/30 (26.7 %)
Patients consumed paracetamol, 1 gm (n)	7
Patients consumed paracetamol, 2 gm (n)	1
Patients consumed nalbuphine (n)	0
Time to first analgesic request (h)	15 ± 3.9 (6-18)

Table 4: Postoperative analgesia.

Discussion

The present study showed that anesthesia with thoracic PVB and conscious sedation for patients undergoing a second look PCNL is a reasonable and a safe alternative to general or neuraxial anesthesia.

In this study, we enrolled the patients scheduled for a second look PCNL as the primary PCNL necessitates cystoscopy for ureteric catheterization, which could not be covered by unilateral PVB. Thoracic PVB has been introduced in anesthesia practice for postoperative analgesia. Few case reports described it as a sole anesthetic technique for patients with multiple comorbidities undergoing mastectomy (Figure 2) [16,17].

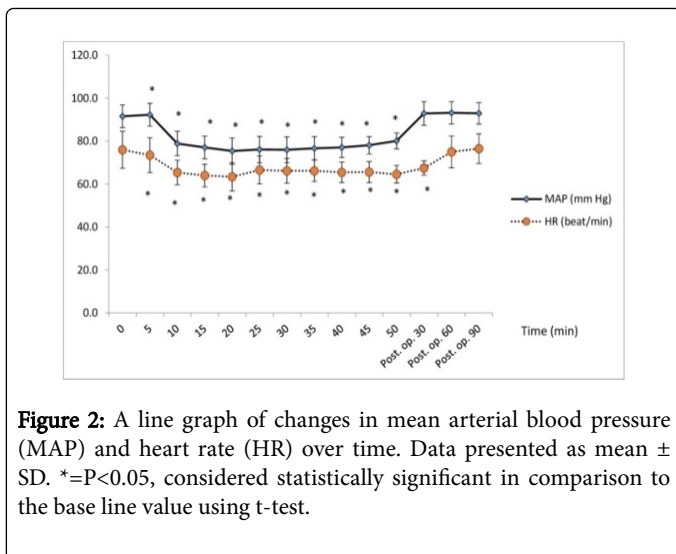


Figure 2: A line graph of changes in mean arterial blood pressure (MAP) and heart rate (HR) over time. Data presented as mean \pm SD. *= $P < 0.05$, considered statistically significant in comparison to the base line value using t-test.

Thoracic paravertebral block has been shown to be a proven technique to provide sufficient postoperative analgesia for a variety of thoracic and upper abdominal surgeries [8-11].

Although PCNL can be done under spinal or epidural anesthesia, they carry their own drawbacks (which can be avoided by using PVB) that include, hypotension especially after positioning the patient prone (due to sympathetic blockade) which necessitates fluid administration added to the irrigation fluids with subsequent electrolyte imbalance and subsequent increased perioperative shivering, the surgeon may not feel comfortable in making skin punctures, especially those close to the 11th rib, patient discomfort increases with increased duration of the procedure and they carry the risks of post-dural puncture headache (PDPH) and neurological complications [6].

The thoracic paravertebral space has been illustrated as a wedge-shaped area, the parietal pleura resembles its anterior boundary and the postero-lateral aspect of the vertebra, the intervertebral foramen, and the intervertebral disc resemble its medial boundary, posteriorly it is bounded by the superior costotransverse ligament and inferiorly by the origin of the psoas major muscle limiting the caudal extension of local anesthetic [18-20].

In the present study, we performed PVB under ultrasonographic guidance as the classic, blind landmark technique [21] has an overall failure rate of 10% and pleural puncture of 1.1%. [22] We reported only one case of failed block that could be attributed to injection anterior to endothoracic fascia which is not visible by ultrasonography making contact with injected local anesthetic is unlikely.

We administered 15 ml of 0.5% bupivacaine as a single injection at the level of T 11 and were successful in nearly all cases. Cheema and colleagues injected 15 ml of bupivacaine 0.5% in thoracic PVB and resulted in somatic block of at least five dermatomes and a sympathetic block of eight dermatomes [13], thus, we believe that multilevel injections would unnecessarily expose patients to additional risks related to multiple punctures.

The pain signals of renal origin travel through afferent A δ and C sympathetic fibers on the adventitia of the renal arteries, reaching the renal and intermesenteric plexus, then pass through the lowest splanchnic nerve, to enter the spinal cord *via* T11 - L2 dorsal roots and finally relay on the medial medullary reticular formation [23].

The mechanism of action of anesthesia and analgesia produced by PVB is most probably due to direct penetration of LA into the spinal nerves contained within the PV space, where they lack their coverings, except of a thin layer which is easily and efficiently blocked [24]. Also, block of thoracic sympathetic ganglia relieves visceral pain arising from the kidney.

More than two thirds of our patients do not require supplemental postoperative analgesia at all, reflecting the efficiency of PVB facilitated by IV dexmedetomidine administration. It deserves mentioning, PCNL is a moderately painful procedure as it is performed percutaneously (no major tissue destruction).

Our choice of dexmedetomidine as a conscious sedative is due to its unique sedation without affection of respiration [25], which is of specific importance for operations in the prone position, in addition to its analgesic-sparing effect, which markedly reduced perioperative opioid consumption [26]. In the present study, only two patients developed oxygen desaturation less than 90% and corrected easily by supplemental oxygen administration through a nasal cannula.

The reduction in hemodynamics in comparison to the baseline values observed in the current study was in concordance with previous studies used dexmedetomidine [27]. Only two cases developed bradycardia and readily reversed with atropine. This is explained by the activation of presynaptic α_2 -adrenoceptors on sympathetic nerves and in the central nervous system leading to a reduction of sympathetic outflow [28].

Future studies using PVB and conscious sedation with dexmedetomidine for more painful surgery, like open nephrolithotomy or nephrectomy are suggested.

The study is limited by the small sample size, the observation period is limited only to 24 h postoperatively and no comparison has yet been made with other regional or general anesthetic technique for such procedure.

Conclusion

We concluded that the anesthetic technique with PVB and conscious sedation with dexmedetomidine for patients undergoing second look PCN provided sufficient sedation, adequate analgesia, minimal side effects, and rapid recovery.

Conflict of Interest

None declared

Funding

None

References

1. Knoll T, Schubert AB, Fahlenkamp D, Leusmann DB, Wendt-Nordahl G, et al. (2011) Urolithiasis through the ages: data on more than 200,000 urinary stone analyses. J Urol 185: 1304-1311.
2. Scales CJ, Smith AC, Hanley JM, Saigal CS (2012) Prevalence of kidney stones in the United States. Eur Urol 62: 160-165.
3. Antonelli JA, Pearle MS (2013) Advances in percutaneous nephrolithotomy. Urol Clin North Am 40: 99-113.
4. Movasseghi G, Hassani V, Mohaghegh MR, Safaeian R, Safari S, et al. (2014) Comparison between spinal and general anesthesia in percutaneous nephrolithotomy. Anesth Pain Med 4: e13871.

5. Cicek T, Gonulalan U, Dogan R, Kosan M, Istanbuluoglu O, et al. (2014) Spinal anesthesia is an efficient and safe anesthetic method for percutaneous nephrolithotomy. *Urology* 83: 50-55.
6. Mehrabi S, Karimzadeh Shirazi K (2010) Results and complications of spinal anesthesia in percutaneous nephrolithotomy. *Urol J* 7: 22-25.
7. Antonelli JA, Pearle MS (2013) Advances in percutaneous nephrolithotomy. *Urol Clin North Am* 40: 99-113.
8. Richardson J, Sabanathan S, Jones J, Shah RD, Cheema S, et al. (1999) A prospective, randomized comparison of preoperative and continuous balanced epidural or paravertebral bupivacaine on post-thoracotomy pain, pulmonary function and stress responses. *Br J Anaesth* 83: 387-392.
9. Davies RG, Myles PS, Graham JM (2006) A comparison of the analgesic efficacy and side-effects of paravertebral vs. epidural blockade for thoracotomy-a systematic review and meta-analysis of randomized trials. *Br J Anaesth* 96: 418-426.
10. Baik JS, Oh AY, Cho CW, Shin HJ, Han SH, et al. (2014) Thoracic paravertebral block for nephrectomy: a randomized, controlled, observer-blinded study. *Pain Med* 15: 850-856.
11. Klein SM, Bergh A, Steele SM, Georgiade GS, Greengrass RA (2000) Thoracic paravertebral block for breast surgery. *Anesth Analg* 90: 1402-1405.
12. Saito T, Gallagher ET, Cutler S, Tanuma K, Yamada K, et al. (1996) Extended unilateral anesthesia. New technique or paravertebral anesthesia? *Reg Anesth* 21: 304-307.
13. Cheema SP, Ilsley D, Richardson J, Sabanathan S (1995) A thermographic study of paravertebral analgesia. *Anaesthesia* 50: 118-121.
14. Gilbert J, Hultman J (1989) Thoracic paravertebral block: a method of pain control. *Acta Anaesthesiol Scand* 33: 142-145.
15. Chung F (1995) Discharge criteria-a new trend. *Can J Anaesth* 42: 1056-1058.
16. Oguz S, Kucuk C, Eskicirak E, Akaltan A, Kuru N, et al. (2007) Thoracic paravertebral block for breast surgery in a patient with myasthenia gravis. *J Anesth* 21: 449.
17. Mozanski MM, Rustecki B, Kalicki B, Jung A (2015) Thermal imaging evaluation of paravertebral block for mastectomy in high risk patient: case report. *J Clin Monit Comput* 29: 297-299.
18. Cowie B, McGlade D, Ivanusic J, Barrington MJ (2010) Ultrasound-guided thoracic paravertebral blockade: a cadaveric study. *Anesth Analg* 110: 1735-1739.
19. Richardson J, Lonnqvist PA (1998) Thoracic paravertebral block. *Br J Anaesth* 81: 230-238.
20. Lonnqvist PA, Hildingsson U (1992) The caudal boundary of the thoracic paravertebral space. A study in human cadavers. *Anaesthesia* 47: 1051-1052.
21. Eason MJ, Wyatt R (1979) Paravertebral thoracic block-a reappraisal. *Anaesthesia* 34: 638-642.
22. Lonnqvist PA, MacKenzie J, Soni AK, Conacher ID (1995) Paravertebral blockade. Failure rate and complications. *Anaesthesia* 50: 813-815.
23. Saito T, Den S, Cheema SPS, Tanuma K, Carney E, et al. (2001) A single-injection, multisegmental paravertebral block extension of somatosensory and sympathetic block in volunteers. *Acta Anaesthesiol Scand* 45: 30-33.
24. Ammons WS (1992) Bowditch Lecture. Renal afferent inputs to ascending spinal pathways. *Am J Physiol* 262: R165-176.
25. Kenan Kaygusuz k, Gokce G, Gursoy S, Ayan S, Mimaroglu C, et al. (2008) A comparison of sedation with dexmedetomidine or propofol during shockwave lithotripsy: A randomized controlled trial. *Anesth Analg* 106: 114-119.
26. Karmakar MK (2001) Thoracic paravertebral block. *Anesthesiology* 95: 771-780.
27. Herr DL, Sum-Ping STJ, England M (2003) ICU sedation after coronary artery bypass graft surgery: dexmedetomidine-based versus propofol-based sedation regimens. *J Cardiothorac Vasc Anesth* 17: 576-184.
28. Hoy SM, Keating GM (2011) Dexmedetomidine: a review of its use for sedation in mechanically ventilated patients in an intensive care setting and for procedural sedation. *Drugs* 71: 1481-1501.