

Periapical Surgery with Biodentine™ as a Retrograde Root-end Seal: A Clinical Case Series Study

Dan-Åke Wälivaara

Oral and Maxillofacial Department, Halland Sjukhus Halmstad, Sweden

Abstract

Purpose: To evaluate the ability of Biodentine™ as a retrograde root-end filling in conjunction with a well-documented periapical surgery protocol in a clinical case series study.

Material and Methods: Thirteen teeth in 13 patients referred for periapical surgery were included in the study. Teeth with obvious signs of root-fracture or apical-marginal communications were excluded from the study. The root-canals of the included teeth were prepared with an ultrasonic technique after an apicectomy of at least 3 mm of the apex. The treated canals were then filled with Biodentine™ as a retrograde root-end seal.

Results: Twelve teeth were available for follow-up after a minimum of 12 months healing time. One patient was not available for the review. A radiological and clinical examination were performed at the follow-up visit and revealed a success of 92%. One tooth was stated as a failure (8%). The majority of the treated teeth were molars (n=8).

Conclusion: Biodentine™ seems to be a suitable retrograde root-end filling material when used with a modern periapical surgery technique. However larger prospective studies are needed to compare the material to other well-documented materials. Alterations of the material to increase the usability and evaluation opportunity would be desirable.

Key Words: Periapical surgery, Biodentine™, Retrograde root-end filling

Introduction

Persistent apical lesions after primary orthograde endodontic treatment occur in 4-21% [1,2]. Orthograde revision of the root-canal filling should be the first treatment of choice whenever possible. Sometimes conventional revision is not feasible due to previous prosthodontic treatment i.e. a crown or a core anchored in the root canal. In such cases the coronal access to the root canal is highly limited. Removal of the prosthodontic construction could even cause a root fracture. In those circumstances periapical surgery can be performed. Many materials have been suggested to serve as a root-end seal and the most recommended nowadays are IRM (intermediate restorative material) and MTA (mineral trioxide aggregate) [3,4]. A relatively new dentine replacement material, Biodentine™ (Septodont, Saint-Maur-de-Fossés, France) primary for use in the crown and root region, is also proposed to be used as retrograde root-end filling in periapical surgery procedures [5]. Case studies of 2 cases using Biodentine™ in periapical surgery, have previously been reported [6,7]. Due to the psychical and chemical characteristics similar to mineral trioxide aggregate and good biocompatibility [8-11], the use of Biodentine™ in periapical surgery should be advantageous. Biodentine™ consists of a liquid and a powder. The liquid is formed by an aqueous solution of calcium chloride with addition of polycarboxylate. The powder contains di- and tricalcium silicate and calcium carbonate. Zirconium dioxide is added for radiographic contrast. The aim of this case series study was to evaluate the ability of Biodentine™ to serve as a retrograde root-end seal in a well-documented periapical surgery model [12,13].

Material and Methods

Patient selection

Thirteen teeth in 13 patients (10 women and 3 men with an

average age of 59 years) referred for periapical surgery due to apical periodontitis, were included in this prospective study. Teeth with obvious root-fractures or advanced periodontal disease (e.g. apical marginal communications) were not included.

Preoperative examination

Preoperative radiographic examination was performed with 2 intraoral radiographs together with a clinical examination. The quality of the orthograde root-filling judged from the radiograph was not an inclusion criterion for participating in the study. The pre- and perioperative variables were noted according to a protocol (Tables 1-2). Information about the study and the intended procedure were given to all patients. No financial compensation was given to the patients except a free-of-charge 1-year follow-up.

Table 1. Pre- and perioperative protocol.

Variable	Comment
Type of restoration	Filling or crown/bridge restoration
Number of affected/treated roots/canals	
Presence of root-canal post	composite, screw-post or casted
Presence of pockets	> 6 mm
Type of lesion	Granuloma, abscess or cyst set from a clinical evaluation
Size of the lesion	Graduated from a clinical evaluation of the diameter of the lesion into three groups: 1) < 5mm 2) 5-9mm 3) > 9mm
Buccal bone status	Presence of buccal bone coverage of the root
Quality of the orthograde root-filling	Evaluated on the preoperative radiograph as complete, uncomplete, shortage or overfilled
Perioperative hemostasis	sufficient or insufficient

Corresponding author: Dan-Åke Wälivaara, DDS, PhD, Consultant in Oral and Maxillofacial Department, Halland Sjukhus Halmstad, Sweden; e-mail: dan-ake.valivaara@regionhalland.se

Table 2. Data from the pre- and perioperative assessment protocol

Pat. No	Gender/Age	Tooth No.	Type of crown restoration	No. of roots/canals	Post	Pockets > 6 mm	Type of lesion	Lesion size group	Intact buccal cortical bone	Root-filling quality	Perioperative hemostasis
1	F/44	21	None	1/1	-	-	Granuloma	3	No	Incomplete (obliterated)	sufficient
2	F/68	44	Crown	1/1	-	-	Granuloma	3	Yes	Complete	sufficient
3	F/64	46	Crown	2/3	Cast	-	Granuloma	2	No	Incomplete	insufficient
4	F/53	36	Composite	1/2	-	-	Granuloma	2	No	Complete/overfilled	sufficient
5	F/50	16	Composite	1/2	-	-	Granuloma	2	No	Shortage	sufficient
6	M/64	16	Crown	1/2	-	-	Granuloma	2	No	Incomplete/shortage	sufficient
7	F/66	25	Crown	1/3	-	-	Granuloma	2	Yes	Shortage	insufficient
8	F/45	46	Composite	2/4	-	-	Granuloma	3	Yes	Shortage	sufficient
9	F/78	44	Crown	1/1	Cast	-	Abscess	3	No	Shortage	sufficient
10	M53	46	Composite	2/3	-	-	Granuloma	3	No	Shortage	sufficient
11	F/56	16	Crown	2/3	Screw-post	-	Granuloma	3	No	Incomplete/shortage	sufficient
12	F/49	16	Crown	2/3	-	-	Granuloma	3	No	Shortage	sufficient
13	M/77	23	Crown	1/1	-	-	Granuloma	1	Yes	Complete	sufficient

Surgical procedure

The surgical procedures were performed by the same surgeon using 4.2 X magnification operating loupes. Local anaesthesia 3.6-5.4 mL, 2% lidocaine with adrenaline was injected into the operating field both as infiltration and/or ID nerve blocks depending on the region. A full-thickness mucoperiosteal buccal flap was raised over the affected tooth. The bony periapical area was exposed using a round-bur followed by removal of the granuloma or cystic lesion from the periapical area. Slightly oblique root-end resection of at least 3 mm with a fissure bur was performed. The root-canal was prepared and cleaned with ultrasonic root-end cavity preparation of 3 mm in depth (Sybron Endo by EMS and diamond coated retrotips). All preparations in the alveolar bone, the apicectomies and the ultrasonic preparation were performed under constant saline irrigation. A small gauze soaked with 1% adrenaline was packed into the bone cavity for 2-3 minutes to achieve haemostasis in the operating field. The canal was then thoroughly dried with 70% alcohol and endodontic paper points. The prepared canals were filled with Biodentine™ (Figure 1) after mixing the powder and liquid for 30 seconds in a triturator. The flap was sutured with Vicryl 4-0 sutures. Two intraoral radiographs were taken immediately after the operation.

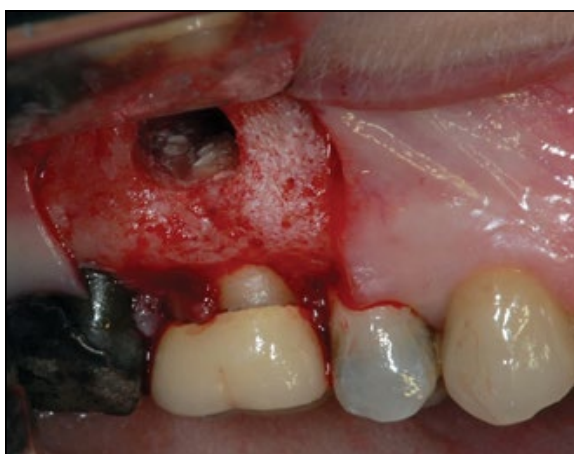

Figure 1. Perioperative situation of tooth 16, with Biodentine™ material in situ.

Clinical and radiographic evaluation

After a minimum period of 12 months healing a radiographic and clinical examination were performed. The clinical reviews of the patients were made by the operating surgeon according to a protocol. Registration of clinical findings such as tenderness on percussion, tenderness on palpation of the crown or/and in the apical area, gingival swelling, presence of a fistula or an apico-marginal communication were recorded as a failure.

All radiographs were reviewed by the operating surgeon. Measurements and classifications according to previously reported models for healing after periapical surgery [14,15] were performed. The following four different classifications were used: 1. Complete healing 2. Incomplete healing (scar tissue) 3. Uncertain healing and 4. Unsatisfactory healing. Group 1 and 2 were recorded as success and group 3 and 4 as failures. The second group, incomplete healing (scar tissue) could be regarded as success at the one year follow-up [16]. The tooth should not present with any clinical or radiographic signs of remaining infection for a successful outcome. Success and failure rates were calculated.

Results

Radiologic assessment

Twelve teeth were available for review. One patient did not attend in the follow-up. The radiological assessment placed eleven teeth in group 1 (Figure 2), complete healing; no tooth in group 2, incomplete healing (scar tissue); one tooth in group 3, uncertain healing (Figure 3) and no tooth in group 4, unsatisfactory healing.

Clinical assessment

One tooth, an upper right first molar showed signs of remaining infection in the form of a fistula. That tooth also had radiographic signs of uncertain healing (group 3). The other 11 teeth were clinically without remark.

Total outcome

The clinical and radiological examination revealed only one failure case (Table 3). The success and failure rates were calculated on 12 teeth with a success of 91.7% (n=11) and

a failure of 8.3% (n=1). The failed tooth 16, which primary treatment involved the mesio-buccal root, was re-operated. This second surgery showed a more widespread apical periodontitis especially on the palatal root (*Figure 3c*), which resulted in a treatment of both the disto-buccal and palatal roots. This palatal apical process was probably undiagnosed at the primary procedure (*Figure 3a*).

Discussion

This study shows a success number of 91.7%, which support the use of Biodentine™ as a retrograde root-end seal, when performing periapical surgery on teeth with apical periodontitis. The study contains a rather low number of included teeth but the result gives an indication that Biodentine™ is a suitable retrograde material. The success figure is in line with previous outcome studies on periapical surgery with success numbers of 82-92% [13,17]. The comparison anyway is weak because of the low number of teeth in the present study. The periapical tissue healing pattern after the use of Biodentine™ resembles MTA [4,9,18], in the way that the periapical bone re-establish very close to the surface of the retrograde material. An experimental model would reveal more proof for the previous statement. The handling of the Biodentine™ material is inconsistent, as the liquid has to be manually added with six drops into the powder and then mixed together for 30 seconds. The consistency of the material often varies probably due to the difference in the amount of fluid from the manual handling. The management of the powder and liquid would be benefited from a package where all ingredients were in one container, harbouring the powder and liquid in two separated compartments until the time of mixing. In such way the uncertainty regarding the amount of fluid added would be eliminated and the consistency of the material would be more standardized. During the insertion of the material into the prepared canal, only small portions of the material can be applied every time, which relates to the softness of the material. This result in more cycles of portions and condensation, compared to MTA and IRM where greater amount of the materials can be handled each time. Secondly the final height of the filling can also be affected due to the softness of the

material. Zirconium dioxide is added to the material to achieve radiographic contrast against the surrounding tissue. The present study shows that the contrast for Biodentine™ on the follow-up radiographs could be higher which is previous reported [19]. Teeth treated with IRM or MTA, which both have greater contrast, show more distinction between the retrograde material, dentine and the surrounding periapical tissue. According to that, the contrast of the Biodentine™ material should be improved for a better density evaluation of the apical seal over time. The manufacturer of Biodentine™ mentions the setting time as one objective to invent the material [5]. The comparison is performed to the original MTA (ProRoot MTA®, Maillefer, Dentsply, Switzerland), which has a setting time of approximately 3 hours, due to the addition of calcium sulphate dehydrate (gypsum). This argument is less important when comparing to an alternative brand of MTA (Angelus®, Londrina, PR, Brazil), which solidifies in 10 minutes, as a result from removal of calcium sulphate dehydrate. Another advantage for the use of Biodentine™ as retrograde obturation is the obtained micro-mechanical adhesion in the interface between the material and human dentine. This is due to an obturation of the dentine tubules by re-crystallisation from the Biodentine™ material [5]. The similar interface pattern is present in MTA because of a gradual formation of hydroxyapatite crystals in the MTA-dentine contact area, which leads to an initial mechanical bond and a gradual transition to a chemical bond [18]. Also the releasing capabilities of free calcium ions adding the interface progression has been reported favouring Biodentine™ over ProRoot MTA® [20].

Conclusion

The result of this case series study using Biodentine™ as a root-end seal in an established and well documented periapical surgery procedure, indicates that the material can be used as a retrograde root-end filling. To achieve scientific evidence for the material, prospective studies comparing Biodentine™ to other documented retrograde materials are needed. The radiographic contrast and the preparation procedure of the material have to be improved by the manufacturer.

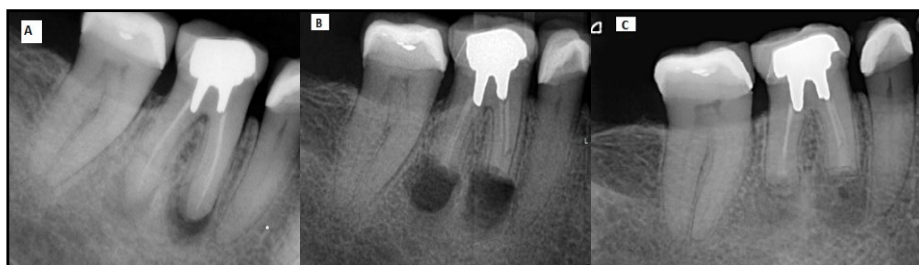

Figure 2. Tooth 46 with apical periodontitis in both roots. Radiographs showing status: (A) preoperative, (B) postoperative and (C) at follow-up revealing complete healing (group 1).

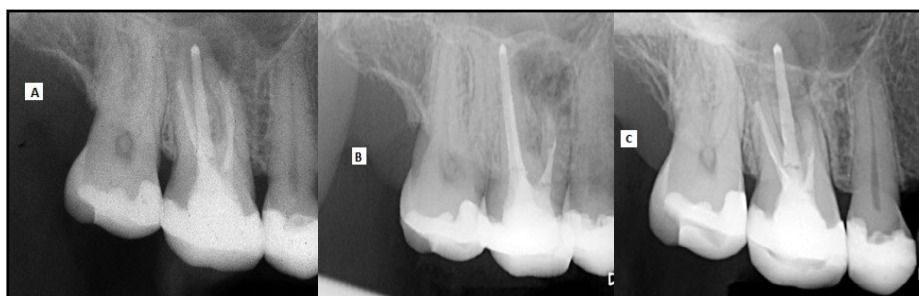


Figure 3. Status of tooth 16 which failed to heal: (A) preoperative, (B) postoperative and (C) follow-up revealing an uncertain healing situation (group 3).

Table 3. Clinical and radiographic assessment follow-up data and final outcome.

Pat No.	Tooth No.	Swelling/sinus	Tender on percussion	Tender on palpation	Apico-marginal communication	Radiographic outcome	Total outcome
1	21	-	-	-	-	1	Success
2	44	-	-	-	-	1	Success
3	46	-	-	-	-	1	Success
4	36	-	-	-	-	1	Success
5	16	+	-	-	-	3	Failure
6	16	-	-	-	-	1	Success
7	25	-	-	-	-	1	Success
8	46	-	-	-	-	1	Success
9	44						D.N.A
10	46	-	-	-	-	1	Success
11	16	-	-	-	-	1	Success
12	16	-	-	-	-	1	Success
13	23	-	-	-	-	1	Success

References

- Kojima K, Inamoto K, Nagamatsu K, Hara A, Nakata K, Morita I, Nakagaki H, Nakamura H. Success rate of endodontic treatment of teeth with vital and nonvital pulps. A meta-analysis. *Oral Surgery, Oral Medicine, Oral Pathology, Oral Radiology and Endodontology*. 2004; **97**: 95-9.
- Sjogren U, Hagglund B, Sundqvist G, Wing K. Factors affecting the long-term results of endodontic treatment. *Journal of Endodontics*. 1990; **16**: 498-504.
- Tang Y, Li X, Yin S. Outcomes of MTA as root-end filling in endodontic surgery: a systematic review. *Quintessence International*. 2010; **41**: 557-66.
- Walivaara DA, Abrahamsson P, Isaksson S, Salata LA, Sennerby L, Dahlin C. Periapical tissue response after use of intermediate restorative material, gutta-percha, reinforced zinc oxide cement, and mineral trioxide aggregate as retrograde root-end filling materials: a histologic study in dogs. *Journal of Oral and Maxillofacial Surgery*. 2012; **70**: 2041-7.
- Septodont. Biodentine™ Active Biosilicate Technology™ Scientific file.
- Caron G, Azerad J, Faure MO, Machtou P, Boucher Y. Use of a new retrograde filling material (Biodentine) for endodontic surgery: two case reports. *International Journal of Oral Science*. 2014; **6**: 250-3.
- Bachoo IK, Seymour D, Brunton P. Clinical case reports using a novel calcium-based cement. *British Dental Journal*. 2013; **214**: 61-4.
- Laurent P, Camps J, De Meo M, Dejous J, About I. Induction of specific cell responses to a Ca(3)SiO(5)-based posterior restorative material. *Dental Materials*. 2008; **24**: 1486-94.
- Torabinejad M, Hong CU, McDonald F, Pitt Ford TR. Physical and chemical properties of a new root-end filling material. *Journal of Endodontics*. 1995; **21**: 349-53.
- Parirokh M, Torabinejad M. Mineral trioxide aggregate: a comprehensive literature review--Part I: chemical, physical, and antibacterial properties. *Journal of Endodontics*. 2010; **36**: 16-27.
- Laurent P, Aubut V, About I. Development of a bioactive Ca₃SiO₅ based posterior restorative material (Biodentine™). M IG, editor. Coxmoor: Oxford; 2009.
- Walivaara DA, Abrahamsson P, Samfors KA, Isaksson S. Periapical surgery using ultrasonic preparation and thermoplasticized gutta-percha with AH Plus sealer or IRM as retrograde root-end fillings in 160 consecutive teeth: a prospective randomized clinical study. *Oral Surgery, Oral Medicine, Oral Pathology, Oral Radiology and Endodontology*. 2009; **108**: 784-9.
- Walivaara DA, Abrahamsson P, Fogelin M, Isaksson S. Super-EBA and IRM as root-end fillings in periapical surgery with ultrasonic preparation: a prospective randomized clinical study of 206 consecutive teeth. *Oral Surgery, Oral Medicine, Oral Pathology, Oral Radiology and Endodontology*. 2011; **112**: 258-63.
- Rud J, Andreasen JO, Jensen JE. Radiographic criteria for the assessment of healing after endodontic surgery. *International Journal of Oral and Maxillofacial Surgery*. 1972; **1**: 195-214.
- Molven O, Halse A, Grung B. Observer strategy and the radiographic classification of healing after endodontic surgery. *International Journal of Oral and Maxillofacial Surgery*. 1987; **16**: 432-9.
- Molven O, Halse A, Grung B. Incomplete healing (scar tissue) after periapical surgery--radiographic findings 8 to 12 years after treatment. *Journal of Endodontics*. 1996; **22**: 264-8.
- Chong BS, Pitt Ford TR, Hudson MB. A prospective clinical study of Mineral Trioxide Aggregate and IRM when used as root-end filling materials in endodontic surgery. *International Endodontic Journal*. 2003; **36**: 520-6.
- Sarkar NK, Caicedo R, Ritwik P, Moiseyeva R, Kawashima I. Physicochemical basis of the biologic properties of mineral trioxide aggregate. *Journal of Endodontics*. 2005; **31**: 97-100.
- Gutiérrez CAG. Apicectomy treated with an active biosilicate cement: Biodentine™. *Septodont Case Studies Collection*. 2013; 18-22.
- Gandolfi MG SF, Polimeni A. In Vitro Screening of the Apatite-Forming Ability, Biointeractivity and Physical Properties of a Tricalcium Silicate Material for Endodontics and Restorative Dentistry. *Dentistry Journal*. 2013; **1**: 41-60.