

Periapical Surgery with IRM and MTA as Retrograde Root-end Fillings—A Prospective Randomized Clinical Study of 186 Consecutive Teeth

Walivaara DA*, Abrahamsson P and Fogelin M

Maxillofacial Unit, Hospital of Halland Halmstad, Sweden

*Corresponding author: Walivaara DA, Maxillofacial Unit, Hospital of Halland Halmstad, Sweden, Tel: +46 3513 4000; Fax: +46 3513 4064; E-mail: dan-ake.valivaara@regionhalland.se

Received date: Aug 16, 2016; Accepted date: Aug 28, 2016; Published date: Sep 08, 2016

Copyright: © 2016 Walivaara DA et al. This is an open-access article distributed under the terms of the Creative Commons Attribution License, which permits unrestricted use, distribution, and reproduction in any medium, provided the original author and source are credited.

Abstract

Aim: The first aim of this study was to evaluate the healing outcome after periapical surgery performed using an ultrasonic cleaning technique in conjunction with the use of either Intermediate Restorative Material (IRM) or mineral trioxide aggregate (MTA) as a retrograde root-end seal in teeth with apical periodontitis. A second aim was to determine if the type of coronal restoration had any impact on the healing outcome.

Methodology: One hundred eighty-six consecutive teeth in 177 patients referred for periapical surgery were randomly allocated into two parallel groups, receiving either IRM or MTA as a retrograde root-end seal. The patients were reviewed 12 months after surgery. Fisher's exact test and Z-test analysis were performed.

Results: One hundred sixty-six teeth in 158 patients were reviewed 12 months after surgery. Radiological evaluation and clinical examination revealed an 86% success rate for the IRM group and 85% for the MTA group. There was no statistically significant difference ($p=0.829$) between the two groups regarding the healing outcome (Fisher's test). The type of coronal restoration ($p=0.575$) had no impact on the healing outcome (Z-test).

Conclusions: The tested materials, IRM and MTA, are both suitable as retrograde root-end filling materials in conjunction with an ultrasonic root-end preparation technique according to the results at the 12-month follow-up. The results of this study also show that the type of coronal restoration had no impact on the healing outcome following periapical surgery.

Keywords: Coronal restoration; IRM; MTA; Periapical surgery; Ultrasonic

Introduction

Teeth with previous conventional endodontic root-canal treatment may present persistent symptomatic or asymptomatic apical periodontitis [1]. Such teeth could be a subject to periapical surgery using a modern technique [2] with an expected good outcome [3-7]. However, uninstrumented teeth with a need of conventional endodontic treatment can also benefit from such a surgical procedure [8]. In a long-term perspective the orthograde retreatment of the root filling offers a more favorable outcome, 83% versus 72% for periapical surgery after 4-6 years [9]. In contrast to that a meta-analysis from Kang et al. revealed a significantly higher success rate for periapical surgery in a short term perspective (less than 4 years) compared to orthograde retreatment, whereas no significant difference could be detected after more than 4 years [10]. Another study has reported a success rate of 62% when performing a revision procedure [11]. In many cases, a prosthetic crown or post has to be removed before the retreatment of the orthograde root filling can be performed and this procedure can involve the risk of causing a root fracture. In such cases periapical surgery is the best treatment alternative. The retrograde obturation of the root canal is a vital part of the periapical procedure [12]. The filling of the apical part of the root canal aims to seal the canal in order to stop leaking of bacterial contents causing the periapical lesion. Suggested requirements for a retrograde root-filling

material are, in addition to sufficient apical obturation, it should be nontoxic, non-resorbable, stable, and biocompatible [13]. In previous studies, different types of retrograde sealing materials have been used [3-5,14-18]. IRM and MTA are commonly used materials today and both have been reported to produce a favorable treatment outcome [19]. The response of the periapical tissue to retrograde fillings in IRM and MTA is also favourable [20]. IRM (DENTSPLY International Inc.) is reinforced zinc-oxide eugenol cement. MTA was invented and developed at Loma Linda University, California by Torabinejad and co-workers [21]. The material's physical and chemical properties, sealing ability, and tissue reaction have been thoroughly investigated both experimentally and clinically [22-25]. MTA has been shown to produce new root cementum formation on its surface, which is unique to this material [20,26,27]. The primary aim of this clinical study was to evaluate if there is a difference in the healing outcome using IRM or MTA as retrograde root-end fillings in a well-documented surgical procedure protocol. Secondly, the aim was to assess the influence of the type of coronal restoration on treatment outcome.

Materials and Methods

The study was designed as a single-center randomized clinical study with parallel groups. The study was carried out between January 2009 and December 2010, at the Oral and Maxillofacial Surgery Department, Hospital of Halland, Halmstad, Sweden. One hundred eighty-six consecutive teeth in 177 patients (86 women and 91 men) with clinical or radiographic signs of periapical periodontitis, referred

for periapical surgery, living 40 kilometres from the Hospital, were included in the study. All patients were invited to participate in the trial at the time prior to surgery and received verbal and written information about the study, as well as their right to end their participation at any time. The patients were given a free-of-charge 1-year follow-up. No financial compensation was given to the patients. Teeth with advanced periodontal disease (e.g. apical marginal communications) or teeth diagnosed with root fractures were excluded from the study. The quality of the persistent root-filling was not an exclusion criterion to participate in the study, rather all teeth were included. The included teeth were allocated into two groups receiving either IRM (89 teeth) or MTA (97 teeth) as a retrograde root-end seal was performed according to a standard randomization table (Figure 1).

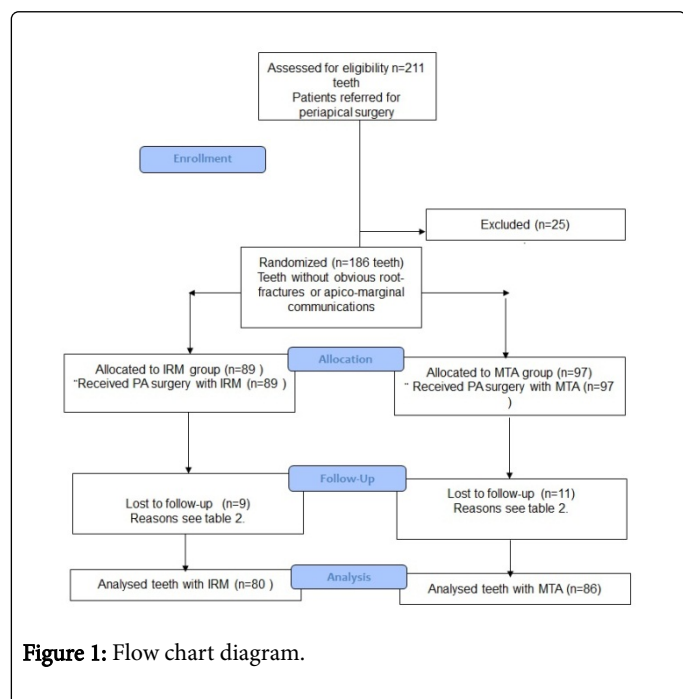


Figure 1: Flow chart diagram.

Preoperative examination

A radiographic and clinical examination was performed preoperatively. The radiographic examination included 2-3 intraoral periapical radiographs taken using a paralleling technique in different horizontal angulations. Upper molars were mostly depicted with 2-3 radiographs. Processing was performed using a Durr-Dental machine, Germany. The results from the clinical examination were noted in the pre- and perioperative protocol. All included teeth were evaluated regarding the quality of the orthograde root filling as judged from the radiographs. The pre- and perioperative protocol contained baseline data variables according to Table 1.

Surgical procedure

Two surgeons independently performed all surgical procedures using operating loupes with 2.3X or 4.2X magnification. The operating field was anaesthetized with 3.6-5.4 ml, 2% lidocaine with adrenaline, both as infiltration and/or as an ID nerve block depending on the region treated. A full-thickness mucoperiosteal buccal flap was raised at the affected tooth. In order to expose the affected root, an osteotomy of the periapical area was performed using a carbon round-bur with a speed of 40000 rpm.

n=number of teeth	IRM followed n=80	MTA followed n=86	Drop-outs IRM n=9	Drop-outs MTA n=11
Number of Incisors U=upper L=lower	U=14, L=3	U=10, L=3	U=0, L=0	U=2, L=1
Number of Canines	U=1, L=0	U=4, L=3	U=0, L=0	U=0, L=1
Number of Premolars	U=7, L=8	U=8, L=12	U=1, L=1	U=2, L=2
Number of Molars	U=19, L=28	U=21, L=25	U=1, L=6	U=2, L=2
Type of restoration F=filling, C=crown	F=34, C=46	F=44, C=42	F=4, C=5	F=8, C=3
Number of affected/ treated canals (I-IV)	I=23, II=20, III=30, IV=7	I=30, II=21, III=25, IV=10	I=1, II=2, III=4, IV=2	I=4, II=5, III=1, IV=1
Presence of root-canal post N=none Cp=composite Scp=screw-post Ca=casted	N=50 Cp=6 Scp=5 Ca=19	N=59 Cp=4 Scp=5 Ca=17	N=5 Cp=2 Scp=1 Ca=1	N=8 Cp=1 Scp=1 Ca=1
Presence of pockets ≥ 6 mm N=number of teeth	N=3	N=4	N=0	N=2
Type of lesion				
G=granuloma	G=71	G=81	G=8	G=11
C=cyst	C=9	C=5	C=1	C=0
Lesion size				
1 ≤ 5 mm	1=28	1=32	1=2	1=3
2=5-9 mm	2=35	2=38	2=7	2=8
3 ≥ 9 mm	3=17	3=16	3=0	3=0
Buccal bone present				
Y=yes	Y=47	Y=21	Y=9	Y=8
N=no	N=33	N=65	N=0	N=3
Quality of the ortho- grade root-filling				
C=complete	C=17	C=14	C=4	C=0
U=uncompleted	U=26	U=33	U=2	U=4
S=shortage	S=34	S=35	S=3	S=5
O=over-filled	O=3	O=4	O=0	O=2
Perioperative haemostasis				
S=sufficient	S=66	S=74	S=7	S=10
I=insufficient	I=14	I=12	I=2	I=1

Table 1: Baseline data follow-ups and drop-outs

The granuloma or cyst was removed from the periapical area followed by a 3-4 mm slightly oblique resection of the root with a fissure bur. A root-end cavity preparation with a depth of 3 mm into

the root canal was performed with an ultrasonic device (Sybron Endo, EMS) and diamond-coated retreaters (EndoMark). The osteotomies, apicectomies and the ultrasonic preparation were carried out under constant saline irrigation. A gauze soaked with 1% adrenaline was packed into the cavity for 2-3 minutes to achieve hemostasis in the operating field. Endodontic paper points soaked with 70% alcohol was used to dry and clean the canal. The prepared canals were then filled with either handspatulated (IRM Dentsply®) or (MTA Angelus®, Londrina, PR, Brazil). The flap was sutured with Vicryl® 4-0 sutures. Two to three intraoral radiographs were taken immediately after the operation.

Clinical and radiographic evaluation

After 12 months (range 12-25 months, average 14 months) a clinical and a radiographic examination were performed. The clinical reviews of the patients were performed by one of three independent surgeons in accordance with a study protocol. If clinical findings such as tenderness on percussion, tenderness on palpation of the crown or/and in the apical area, gingival swelling, presence of a fistula or an apico-marginal communication were present the treatment was recorded as a failure. The two operating surgeons and a maxillofacial radiologist reviewed all radiographs independently. The X-ray evaluation was performed in a light room with ambient lightning using a light-box (Lysta, Ultra Luna, Denmark) and a Matsson viewer (binoculars) with 2X magnification. If there was any disagreement about the findings, a joint discussion followed. Measurements and classifications according to previously reported models for evaluating healing after periapical surgery [28,29] were performed. The following four classifications were used: 1) complete healing 2) incomplete healing (scar tissue) 3) uncertain healing and 4) unsatisfactory healing. Group 1 and 2 were considered as successes and group 3 and 4 as failures. The second group, incomplete healing (scar tissue), can according to Molven et al. be regarded as a success at the 1-year follow-up [30] if there are no clinical or radiographic findings indicating a remaining infection. Success and failure rates for the two filling materials, the healing outcome from different areas in the mouth and the possible influence on outcome of the coronal restoration were analyzed.

Results

One hundred sixty-six teeth (80 IRM and 86 MTA) in 158 patients were assessed at the follow-up visit. Nineteen patients with 20 teeth (9 IRM and 11 MTA), dropped out (Table 2).

Reason	n
Death	1
Moved	1
Did not attend review appointment	5
Extracted due to root-fracture	7
Extracted due to periodontitis	1
Extracted due to unknown reason	1
Patient declined participation	3
Total	19

Table 2: Distribution of reasons for the drop-out patients

IRM group

Of the 80 teeth in the IRM group, the radiological assessment placed 63 teeth in group 1 (Figure 2), complete healing; 10 teeth in group 2 (Figure 3), incomplete healing (scar tissue); 6 teeth in group 3, uncertain healing (Figure 4) and 1 tooth in group 4, unsatisfactory healing. Following the final clinical and radiological examination a total of 11 failures were recognized. The success and failure rates were calculated on 80 teeth with success in 69 teeth (86.3%) and 11 failures (13.7%), (Table 3).

IRM (n=80)	MTA (n=86)		p-value (p=0.05)
	success	failure	
	n (%)	n (%)	
Incisor Upper	12 (85.7)	2 (14.3)	0.192
Lower	3 (100)	0	1.000
Canine Upper	1 (100)	0	1.000
Lower	0	0	1.000
Premol Upper	6 (85.7)	1 (14.3)	1.000
Lower	7 (87.5)	1 (12.5)	0.400
Molar Upper	17 (89.5)	2 (10.5)	0.412
Lower	23 (82.1)	5 (17.9)	0.196
Total	69 (86.2)	11 (13.8)	0.829

Table 3: Outcome for different types of teeth in the maxilla and mandible in both material groups and statistical result of the difference in healing between the two material groups

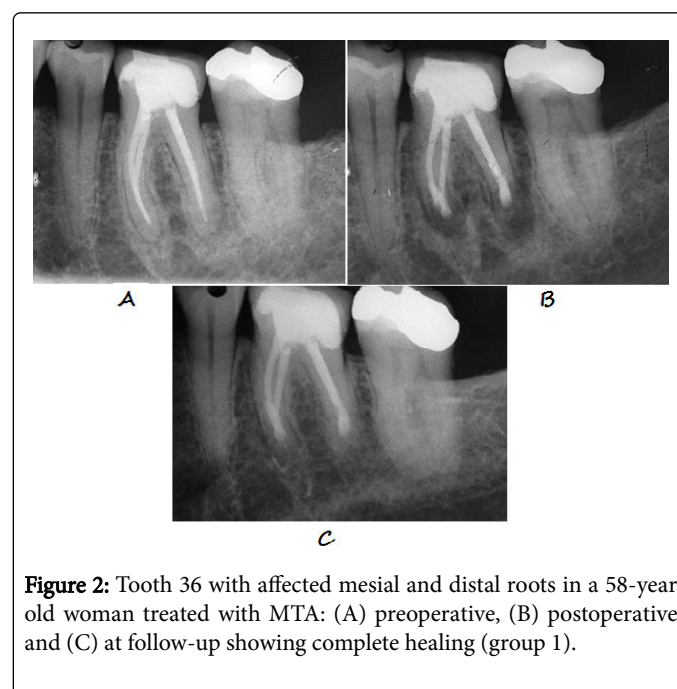


Figure 2: Tooth 36 with affected mesial and distal roots in a 58-year old woman treated with MTA: (A) preoperative, (B) postoperative and (C) at follow-up showing complete healing (group 1).

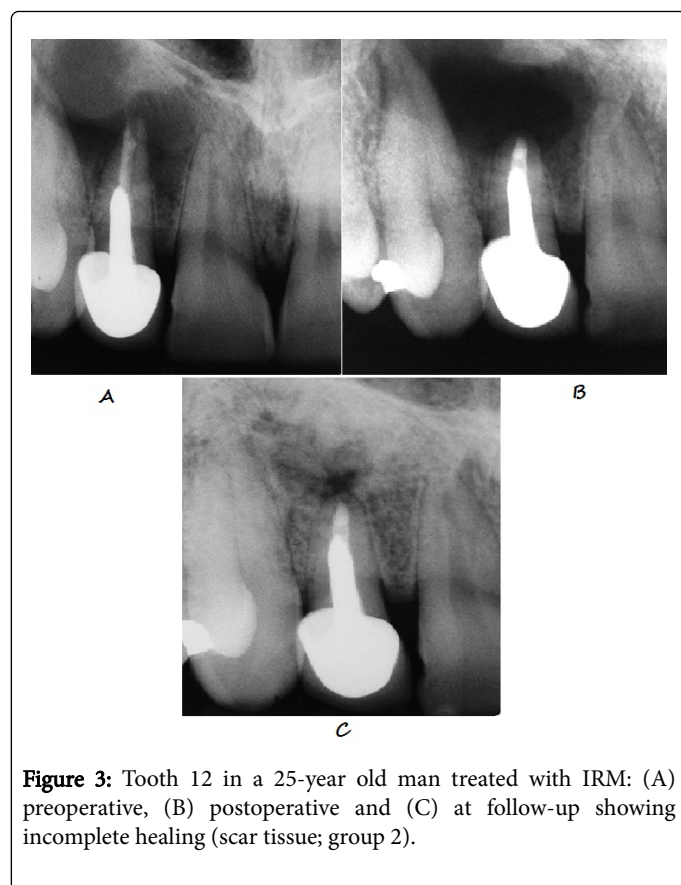


Figure 3: Tooth 12 in a 25-year old man treated with IRM: (A) preoperative, (B) postoperative and (C) at follow-up showing incomplete healing (scar tissue; group 2).

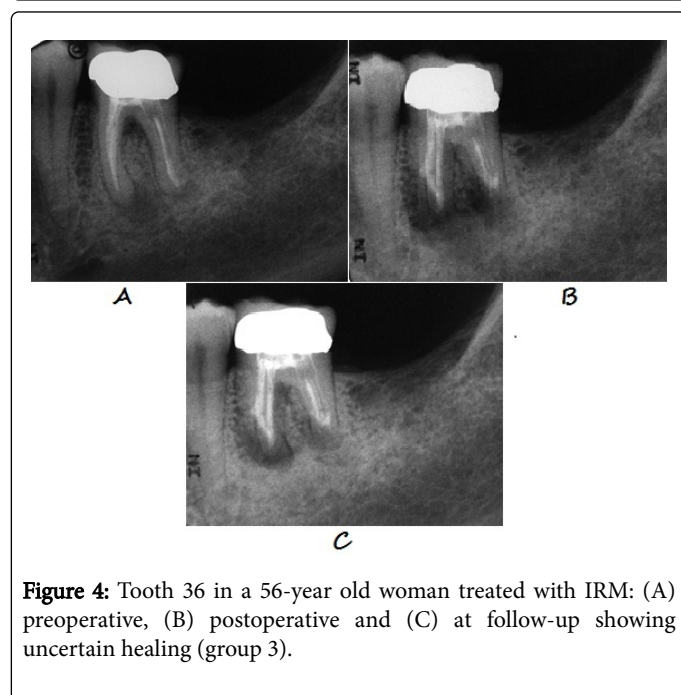


Figure 4: Tooth 36 in a 56-year old woman treated with IRM: (A) preoperative, (B) postoperative and (C) at follow-up showing uncertain healing (group 3).

MTA group

Of the 86 teeth in the MTA group the radiological assessment placed 77 teeth in group 1, complete healing; 7 teeth in group 2, incomplete healing (scar tissue); 2 teeth in group 3, uncertain healing

and no teeth in group 4, unsatisfactory healing. Following the clinical and radiological examination results there were a total of 13 failures. The success and failure rates were calculated on 86 teeth with success in 73 teeth (84.9%) and 13 failures (15.1%) (Table 3).

Overall treatment results

The distribution of success and failure among different types of teeth, retrograde material, and upper and lower jaw are presented in Table 3.

Distribution of teeth according to coronal restoration

The distribution of the teeth according to the type of coronal restoration, filling, or crown is presented in Table 4. The influence from the type of coronal restoration on the treatment outcome was statistically analysed.

Type restoration	of	Outcome	IRM (n)	MTA (n)	Total (n)
Crown		success	36	38	74
		failure	10	4	14
Filling		success	33	35	68
		failure	1	9	10
			80	86	166

Table 4: Distribution of teeth and success rates with respect to the type of coronal restoration

Statistical analysis

Fisher's exact test was used for a statistical analysis regarding the differences in healing between the retrograde materials. When comparing all teeth together, there was no statistically significant difference between the two groups (IRM and MTA) regarding the healing outcome, $p=0,829$. There was also no significant difference in the healing outcome between the material groups when examining the results for maxillary and mandibular teeth separately (Table 3).

There was no statistically significant difference regarding the impact of the type of coronal restoration on healing outcome. This analysis was performed with a Z-test with CI=95%: $p=0.575$.

Discussion

Considering the entry protocol for the patients included, the treatment results presented in this paper must be regarded as good. No preoperative exclusion of teeth with doubtful root-filling status evaluated on two-dimensional radiographs was performed. Only teeth with obvious root fractures or advanced periodontal tissue loss i.e. apico-marginal communications were excluded. The surgical protocol of the study included a modern retrograde cleaning technique with ultrasonic preparation, which has been shown to have significantly better outcome results than the use of a traditional round-bur technique [6,31]. The overall outcome of the study revealed no significant difference between IRM and MTA which is in line with other reported studies [3,7]. IRM has been used as a retrograde root-end filling material before MTA which was invented in the early 1990s [21]. The high powder/liquid ratio when mixing the IRM material

gives a high physical strength and a considerably easier manipulation. As a retrograde filling material, IRM has been reported to have good long-term follow-up results. In both a 10-year retrospective study [14] and a prospective study with a 12-month follow-up [5] the success rate was reported to be 91%. These results and the fact that IRM is easy to handle make it a good sealing alternative. The results of the present study should be compared to the outcome of a similar study by Chong et al. with respect to the materials tested and the prospective study design [3]. Their study reported a success rate of 92% for MTA and 87% for IRM at a 24-month follow-up, which is slightly higher than the present study. There are two main differences in the study protocols. The first concerns the type of teeth included in studies. Chong et al. only treated single-rooted teeth, one premolar or the mesio-buccal root of the maxillary molar. That distinction was not made in the present study where all types of teeth were included. The majority of the included teeth were molars (Table 1), which might explain the slightly lower success rates. The second difference is the assessment of the quality of the root filling as judged from the preoperative radiographs. The study by Chong et al. did not allow for any radiolucency along the root filling whilst the present study protocol allowed for the inclusion of all types of radiographic appearance. Support for this inclusion criterion can be obtained from a previous report, which concluded that the pre-operative root-filling status judged from a two-dimensional radiograph has no significant influence on the healing outcome after periapical surgery [5]. However, there is a study reporting a better outcome after periapical surgery on teeth with dense orthograde root fillings positioned 2 mm or less from the apex [32]. The importance of performing a periapical root-end seal together with the root-end resection, especially in teeth with insufficient orthograde root-fillings has previously been stated [33]. There is a significant difference in the treatment outcome between the option of performing only a root-end resection followed by a smoothing of the gutta-percha surface and the option of preparing the root canal with an ultrasonic technique followed by a retrograde root-end seal with MTA [34]. The latter procedure has a more favorable outcome, 96% versus 52% success rate. The present paper recorded the type of coronal restoration preoperatively (Table 1), but no significant influence on the healing outcome could be detected. This can be compared to conventional endodontic treatment, where the outcome is dependent on the subsequent coronal restoration. Teeth with temporary fillings that have previously been treated endodontically are also more often lost than teeth treated with permanent coronal restorations (cast restorations, amalgam and composite) [35]. It has also been suggested that a permanent restoration should be performed as soon as possible after completing a conventional endodontic treatment [36]. The 5-year survival of endodontically treated molars is 36% when not covered with a crown restoration. The extent of remaining tooth substance seems to affect the survival rate of endodontically treated teeth without crown restorations [37].

Conclusion

The results of the present study indicate that both evaluated retrograde root-filling materials, IRM and MTA can serve as a root-end seal in periapical surgery performed with an ultrasonic root-end preparation technique. This conclusion is supported by a publication by Tang et al. [19], who reports that both MTA and IRM can be used as root-end fillings. The type of coronal restoration has no impact on the outcome after periapical surgery according to the result from the present study.

Ethical Approval

The study was approved by the human ethical committee Dnr 173/2005, at the University of Lund, Sweden and was conducted

References

1. Kojima K, Inamoto K, Nagamatsu K, Hara A, Nakata K, et al. (2004) Success rate of endodontic treatment of teeth with vital and nonvital pulps. A meta-analysis. *Oral Surg Oral Med Oral Pathol Oral Radiol Endod* 97: 95-99.
2. Kim S, Kratchman S (2006) Modern endodontic surgery concepts and practice: a review. *J Endod* 32: 601-623.
3. Chong BS, Pitt Ford TR, Hudson MB (2003) A prospective clinical study of Mineral Trioxide Aggregate and IRM when used as root-end filling materials in endodontic surgery. 36: 520-526.
4. Wälivaara DA, Abrahamsson P, Sämfors KA, Isaksson S (2009) Periapical surgery using ultrasonic preparation and thermoplasticized gutta-percha with AH Plus sealer or IRM as retrograde root-end fillings in 160 consecutive teeth: a prospective randomized clinical study. *Oral Surg Oral Med Oral Pathol Oral Radiol Endod* 108: 784-789.
5. Walivaara DA, Abrahamsson P, Fogelin M, Isaksson S (2011) Super-EBA and IRM as root-end fillings in periapical surgery with ultrasonic preparation: a prospective randomized clinical study of 206 consecutive teeth. *Oral Surg Oral Med Oral Pathol Oral Radiol Endod* 112: 258-263.
6. Tortorici S, Difalco P, Caradonna L, Tetè S (2014) Traditional endodontic surgery versus modern technique: a 5-year controlled clinical trial. *J Craniofac Surg* 25: 804-807.
7. Kim S, Song M, Shin SJ, Kim E (2016) A Randomized Controlled Study of Mineral Trioxide Aggregate and Super Ethoxybenzoic Acid as Root-end Filling Materials in Endodontic Microsurgery: Long-term Outcomes. *J Endod* 42: 997-1002.
8. Jonasson P, Reit C, Kvist T (2008) A preliminary study on the technical feasibility and outcome of retrograde root canal treatment. *Int Endod J* 41: 807-813.
9. Torabinejad M, Corr R, Handysides R, Shabahang S (2009) Outcomes of nonsurgical retreatment and endodontic surgery: a systematic review. *J Endod* 35: 930-937.
10. Kang M, In Jung H, Song M, Kim SY, Kim HC, et al. (2015) Outcome of nonsurgical retreatment and endodontic microsurgery: a meta-analysis. *Clin Oral Investig* 19: 569-582.
11. Sjogren U, Hagglund B, Sundqvist G, Wing K (1990) Factors affecting the long-term results of endodontic treatment. *J Endod* 16: 498-504.
12. Otani K, Sugaya T, Tomita M, Hasegawa Y, Miyaji H, et al. (2011) Healing of experimental apical periodontitis after apicoectomy using different sealing materials on the resected root end. *Dent Mater J* 30: 485-492.
13. Chong BS, Pitt Ford TR (2005) Root-end filling materials: rationale and tissue response. *Endod Topics* pp: 114-130.
14. Dorn SO, Gartner AH (1990) Retrograde filling materials: a retrospective success-failure study of amalgam, EBA, and IRM. *J Endod* 16: 391-393.
15. Frank AL, Glick DH, Patterson SS, Weine FS (1992) Long-term evaluation of surgically placed amalgam fillings. *J Endod* 18: 391-398.
16. Jesslén P, Zetterqvist L, Heimdahl A (1995) Long-term results of amalgam versus glass ionomer cement as apical sealant after apicoectomy. *Oral Surg Oral Med Oral Pathol Oral Radiol Endod* 79: 101-103.
17. Zuolo ML, Ferreira MO, Gutmann JL (2000) Prognosis in periradicular surgery: a clinical prospective study. *Int Endod J* 33: 91-98.
18. Rud J, Rud V, Munksgaard EC (2001) Periapical healing of mandibular molars after root-end sealing with dentine-bonded composite. *Int Endod J* 34: 285-292.
19. Tang Y, Li X, Yin S (2010) Outcomes of MTA as root-end filling in endodontic surgery: a systematic review. *Quintessence Int* 41: 557-566.
20. Walivaara DA, Abrahamsson P, Isaksson S, Salata LA, Sennerby L, et al. (2012) Periapical tissue response after use of intermediate restorative material, gutta-percha, reinforced zinc oxide cement, and mineral

- trioxide aggregate as retrograde root-end filling materials: a histologic study in dogs. *J Oral Maxillofac Surg* 70: 2041-2047.
21. Torabinejad M, Watson TF, Pitt Ford TR (1993) Sealing ability of a mineral trioxide aggregate when used as a root end filling material. *J Endod* 19: 591-595.
 22. Torabinejad M, Hong CU, McDonald F, Pitt Ford TR (1995) Physical and chemical properties of a new root-end filling material. *J Endod* 21: 349-353.
 23. Torabinejad M, Rastegar AF, Kettering JD, Pitt Ford TR (1995) Bacterial leakage of mineral trioxide aggregate as a root-end filling material. *J Endod* 21: 109-112.
 24. Fischer EJ, Arens DE, Miller CH (1998) Bacterial leakage of mineral trioxide aggregate as compared with zinc-free amalgam, intermediate restorative material, and Super-EBA as a root-end filling material. *J Endod* 24: 176-179.
 25. Gondim E Jr, Kim S, de Souza-Filho FJ (2005) An investigation of microleakage from root-end fillings in ultrasonic retrograde cavities with or without finishing: a quantitative analysis. *Oral Surg Oral Med Oral Pathol Oral Radiol Endod* 99: 755-760.
 26. Torabinejad M, Pitt Ford TR, McKendry DJ, Abedi HR, Miller DA, et al. (1997) Histologic assessment of Mineral Trioxide Aggregate as a root-end filling in monkeys. *Int Endod J*: 225-228.
 27. Baek SH, Plenk H Jr, Kim S (2005) Periapical tissue responses and cementum regeneration with amalgam, SuperEBA, and MTA as root-end filling materials. *J Endod* 31: 444-449.
 28. Rud J, Andreasen JO, Jensen JE (1972) Radiographic criteria for the assessment of healing after endodontic surgery. *Int J Oral Surg* 1: 195-214.
 29. Molven O, Halse A, Grung B (1987) Observer strategy and the radiographic classification of healing after endodontic surgery. *Int J Oral Maxillofac Surg* 16: 432-439.
 30. Molven O, Halse A, Grung B (1996) Incomplete healing (scar tissue) after periapical surgery--radiographic findings 8 to 12 years after treatment. *J Endod* 22: 264-268.
 31. Setzer FC, Shah SB, Kohli MR, Karabucak B, Kim S (2010) Outcome of endodontic surgery: a meta-analysis of the literature--part 1: Comparison of traditional root-end surgery and endodontic microsurgery. *J Endod* 36: 1757-1765.
 32. Danin J, Linder LE, Lundqvist G, Ohlsson L, Ramsköld LO, et al. (1999) Outcomes of periradicular surgery in cases with apical pathosis and untreated canals. *Oral Surg Oral Med Oral Pathol Oral Radiol Endod* 87: 227-232.
 33. Hirsch JM, Ahlström U, Henrikson PA, Heyden G, Peterson LE (1979) Periapical surgery. *Int J Oral Surg* 8: 173-185.
 34. Christiansen R, Kirkevang LL, Hørsted-Bindslev P, Wenzel A (2009) Randomized clinical trial of root-end resection followed by root-end filling with mineral trioxide aggregate or smoothing of the orthograde gutta-percha root filling--1-year follow-up. *Int Endod J* 42: 105-114.
 35. Lynch CD, Burke FM, Ní Ríordáin R, Hannigan A (2004) The influence of coronal restoration type on the survival of endodontically treated teeth. *Eur J Prosthodont Restor Dent* 12: 171-176.
 36. Willershausen B, Tekyatan H, Krummenauer F, Briseño Marroquin B (2005) Survival rate of endodontically treated teeth in relation to conservative vs post insertion techniques -- a retrospective study. *Eur J Med Res* 10: 204-208.
 37. Nagasiri R, Chitmongkolsuk S (2005) Long-term survival of endodontically treated molars without crown coverage: a retrospective cohort study. *J Prosthet Dent* 93: 164-170.