

Possible Cause for Delay the Testicular Torsion in Adults in North of KSA, Case Report

Mohammed Jayed Alenzi*, Abdulaziz faisal wanees alrabeea and Thamer Manwer Albalasi

College of Medicine, Aljouf University, Saudi Arabia

Abstract

Objectives: Testicular Torsion is a rare to occur in adults. It should not come late and end by missed torsion, particularly when the patients are adults ad mature. In those cases, we want to know why did they come late?

Methods: We faced three cases with missed torsion and end by Orchidotomy. After Taken a clear history and more discussion with them we found one answer which is "Shame habits" to complaining from genitalia?

Results: All three cases and I think most males in our country need more education about how can they deal with genitalia symptoms because the shaming from that became habits in most of males in our country and even in other middle east countries.

Conclusions: To our knowledge, this represents the high percentage of male complaining how can they deal with or expression about their genitalia symptoms. For that, the people education is very important to distribute the knowledge between the parents and the adults you can save yourself if you go directly to the hospital or your physician.

Keywords: Testicular torsion; Nausea; Fertility; Pain

Introduction

Testicular torsion is a twisting of the spermatic cord and its contents and is emergency which need urgent surgical intervention affecting 3.8 per 100,000 males younger than 18 years annually [1]. It is about 10% to 15% of acute scrotum in children [2], and results in an orchiectomy rate of 42% in boys undergoing surgery for testicular torsion [3].

Proper diagnosis and treatment are very important for testicular salvage, and torsion must be excluded in all patients who present with acute scrotum. Testicular torsion is a clinical diagnosis, and patients typically present with severe acute unilateral scrotal pain, nausea, and vomiting [4]. Physical examination may reveal a high-riding testicle with an absent cremasteric reflex. If history and physical examination suggest torsion, immediate surgical exploration is indicated and should not be postponed to perform imaging studies. There is typically a four- to eight-hour window before permanent ischemic damage occurs [5]. Delay in treatment may be associated with decreased fertility, or may necessitate orchiectomy.

Shame involves an internalized feeling of being exposed and humiliated Shame makes people want to hide and disappear, reinforcing shame. Shame is created in children through scolding, judging, criticizing, abandonment, sexual and physical abuse [6-8].

Case Report

A 21years old male was visiting the emergency department with the history of right hemi scrotal swelling one week period. It started with incident pain in the same side and he got some analgesia for that pain. It was associated with swelling in the same side. The pain continued for three days and subsided but the swelling increased in size. No history of change the colour of skin over the swelling. No history of trauma. No history of fever.

On clinical examination, he looks irritable and anxious. Vital signs were stable. Abdomen was soft, lax and no organomegally. External genitalia looked normal except right side was huge swelling, non-tenderness and no hotness.

Left side looked normal in size and shape.

Laboratory results like CBC, Biochemistry and bleeding time were within the normal range.

Doppler ultrasound was done showing absence of blood flows in the testis and epididymis; hypoechoic regions represent necrosis, reactive hydrocele and reactive thickening of the scrotal skin with hyperaemia.

In operation theatre, right side scrotal exploration was performed and the testis was black and necrotic (Figures 1 and 2). The right orchiectomy (Figure 3) was done and left testis was fixed. Compressing dressing was done post-operation around the wound in order to prevent bleeding after the patient felt normal, he was transferred to the ward.

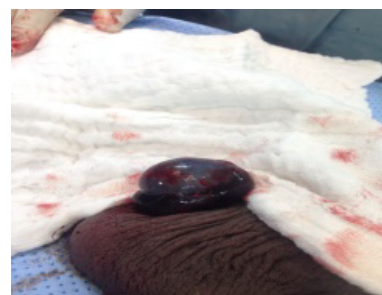

Figure 1: Right side scrotal exploration was performed and the testis was black and necrotic.

*Corresponding author: Mohammed Jayed Alenzi, College of Medicine, Aljouf University, Saudi Arabia, Tel: +966146247493; E-mail: mja@ju.edu.sa

Received January 17, 2017; Accepted March 15, 2017; Published March 20, 2017

Citation: Alenzi MJ, Alrabeea AFW, Albalasi TM (2017) Possible Cause for Delay the Testicular Torsion in Adults in North of KSA, Case Report. J Clin Case Rep 7: 936. doi: 10.4172/2165-7920.1000936

Copyright: © 2017 Alenzi MJ, et al. This is an open-access article distributed under the terms of the Creative Commons Attribution License, which permits unrestricted use, distribution, and reproduction in any medium, provided the original author and source are credited.

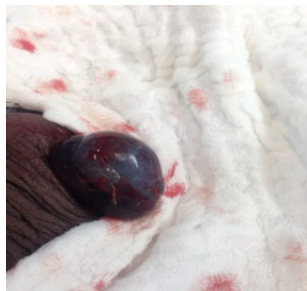


Figure 2: Right side scrotal exploration was performed and the testis was black and necrotic.

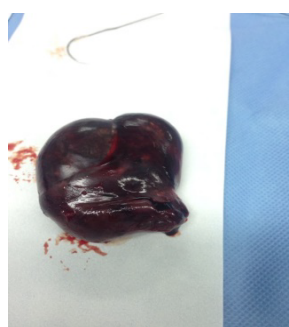

Figure 3: The right orchiectomy was done and left testis was fixed.

Discussion

Currently, In the neonatal form of torsion (extravaginally or supravaginal) the whole content of the hemiscrotum rotates around the spermatic cord at the level of the external inguinal ring [7].

In adolescents or young adults, the more common torsion is intravaginal. The most common underlying abnormality is the so-called bell clapper deformity which allows the testis (and attached epididymis) extensive mobility, and thus places it at risk of twisting around the spermatic cord.

Initially, torsion is sufficient only to obstruct venous outflow (incomplete torsion, less than 360°), resulting in the gradual increase in intratesticular pressure and resistance. Over time and with an additional twisting of the cord (greater than 360 degrees), the arterial inflow is also obstructed, and the testis becomes entirely ischemic [6].

In children, when the boy has pain or something bothers him, he goes directly to his parent to complain for them. but in mature adult, he should go directly to hospital or primary health care. In our case, there are what called “shaming” to complain from the genitalia symptoms among the Saudi guys. This is what we saw in most of cases in clinic of urology for example one patient , 32 years old primary infertility refused clinical examination to exclude the varicocele even ultrasound for his scrotum. The shaming effect on patients with acute scrotum and let him accept the pain and finally come very late to hospital and end with orchidotomy. For that, we should do health education especially in male schools in our country to decrease the level of sensitivity through the males from complaining of symptoms of external genitalia.

Conclusion

This represents the high percentage of male complaining how they can deal with or expression about their genitalia symptoms. For that, the people education is very important to distribute the knowledge between the parents and the adults you can save yourself if you go directly to the hospital or your physician. Also, the use of social media to distribute the information play a role in health education and decrease the sensitivity through the males from complaining of symptoms of external genitalia. Shame can be relieved and healed by taking healthy risks to be seen and known authentically, acting from a positive motive and trying out new behaviors in a safe (non-judgmental) setting. Taking actions that generate pride-the antidote to shame breaking secrecy with people who understand.

References

1. Thomas WE, Cooper MJ, Crane GA, Lee G, Williamson RC (1984) Testicular exocrine malfunction after torsion. *Lancet* 2: 1357-1360.
2. Romeo C, Impellizzeri P, Arrigo T (2010) Late hormonal function after testicular torsion. *J Pediatr Surg* 45: 411-413.
3. Bartsch G, Frank S, Marberger 2-H, Mikuz G (1980) Testicular torsion: Late results with special regard to fertility and endocrine function. *J Urol* 124: 375-378.
4. Kapoor S (2008) Testicular torsion: A race against time. *Int J Clin Pract* 62: 821-827.
5. Bhatt S, Dogra VS (2008) Role of US in testicular and scrotal trauma. *Radiographics* 28: 1617-1629.
6. Eaton SH, Cendron MA, Estrada CR (2005) Intermittent testicular torsion: Diagnostic features and management outcomes. *J Urol* 174: 1532-1535.
7. Wolf K (1995) *Color duplex sonography, principles and clinical applications*. Thieme. ISBN: 0865775427.
8. Margolies L (2016) *Breaking the cycle of shame and self-destructive behavior*. Psych Central.

Citation: Alenzi MJ, Alrabeea AFW, Albalasi TM (2017) Possible Cause for Delay the Testicular Torsion in Adults in North of KSA, Case Report. J Clin Case Rep 7: 936. doi: [10.4172/2165-7920.1000936](https://doi.org/10.4172/2165-7920.1000936)

OMICS International: Open Access Publication Benefits & Features

Unique features:

- Increased global visibility of articles through worldwide distribution and indexing
- Showcasing recent research output in a timely and updated manner
- Special issues on the current trends of scientific research

Special features:

- 700+ Open Access Journals
- 50,000+ editorial team
- Indexing at major indexing services
- Rapid review process
- Quality and quick editorial, review and publication processing
- Indexing at major indexing services
- Sharing Option: Social Networking Enabled
- Authors, Reviewers and Editors rewarded with online Scientific Credits
- Better discount for your subsequent articles

Submit your manuscript at: <http://www.omicsonline.org/submission//>