

## Posterior versus Lateral Plate Fixation of Short Oblique Fractures of the Distal Fibula: A Literature Review

Julia S Sanders<sup>1\*</sup>, Ryan R Fader<sup>1</sup> and Justin J Mitchell<sup>2</sup>

<sup>1</sup>Department of Orthopaedic Surgery, University of Colorado Hospital, Aurora, CO, United States

<sup>2</sup>Gundersen Lutheran Medical Center, Department of Sports Medicine, La Crosse, WI, USA

\*Corresponding author: Julia S Sanders, Department of Orthopaedic Surgery, University of Colorado School of Medicine, 12631 E. 17th Avenue, Mail Stop B202 Aurora, CO, 80045, United States, Tel: 3037242963; Fax: 303.724.1593; E-mail: [julia.sanders@ucdenver.edu](mailto:julia.sanders@ucdenver.edu)

Rec date: May 12, 2016; Acc date: Aug 27, 2016; Pub date: Sep 02, 2016

Copyright: © 2016 Julia SS, et al. This is an open-access article distributed under the terms of the Creative Commons Attribution License, which permits unrestricted use, distribution, and reproduction in any medium, provided the original author and source are credited.

### Abstract

**Background:** Oblique spiral fractures of the distal third of the fibula are commonly encountered in any orthopedic practice. Controversy persists over various fixation methods and their corresponding risks and benefits.

**Methods:** A systematic review of the pertinent literature pertaining to these fractures was performed, and currently published results were summarized.

**Results:** There are advantages and disadvantages to each fixation method. Supporters of direct lateral plating argue for less peroneal irritation, ease of exposure, and direct fracture reduction. Those in favor of posterior plating report increased biomechanical strength, less lateral skin irritation, infrequent need for hardware removal, and ability to use bicortical fixation in the distal fragment. Modern implant advances and minimally invasive approaches have added complexity to fixation choices.

**Conclusion:** Presently there is insufficient evidence to support either posterior or lateral fibular plating as a gold standard. Choice of approach and surgical technique should be individually based on fracture pattern, patient characteristics and surgeon experience.

**Keywords:** Ankle fracture; Fibula; Fibular fracture; Fracture fixation; Plating; Techniques; Lateral plating; Posterior plating; Ankle fixation

### Level of Evidence

Level III, Literature Review

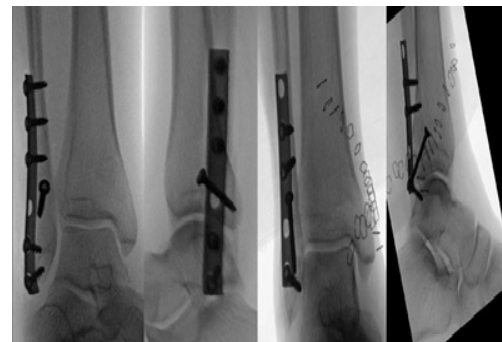
### Introduction

Fractures of the lateral malleolus are among the most common injuries seen and treated by orthopedic surgeons. Short oblique fractures of the distal fibula present a familiar surgical problem, however the ideal method of fixation remains controversial. Lateral neutralization plating and posterior antiglide plating are the two most popular fixation techniques (Figure 1).

Anatomic reduction and fixation of the distal fibula has been shown to improve outcomes in patients with an unstable ankle mortise [1,2].

Historically, this has been accomplished with anatomic reduction, lag screw fixation, and a lateral neutralization plate with bicortical screws proximally and unicortical screws distally [3,4].

More recently, however, potential disadvantages of this technique have arisen, including intra-articular screw placement distally, prominent or symptomatic lateral screws, inadequate distal fixation, loss of fixation, and wound complications [1,4-10].



**Figure 1:** Examples of lateral neutralization and posterior antiglide plating of distal third fibula fractures.

To mitigate these potential complications, the use of a posterior antiglide plate as a method of fibular fixation was proposed in the early 1980's. Proponents of this technique postulated that posterior plating was biomechanically superior and avoided many complications of lateral plating [11].

With the popularization of this method, discussion and research persists regarding the potential advantages and disadvantages of lateral versus posterior plating. As minimally invasive surgical techniques become more prevalent and implant technology advances, this debate

persists. In this paper, we present a review of the available literature on lateral and posterior plating of the distal fibula.

## Mechanism of Injury and Classification

Short oblique fractures of the fibula are typically caused by rotational injury to the ankle, with force transmission through the ankle, exiting through the lateral or posterior aspect of the fibula. This pattern of injury has been classified by three common systems: Weber, AO and Lauge-Hansen. These different schemata categorize these injuries by mechanism, location, and fracture pattern.

The Danis-Weber classification identifies fractures based on location in relation to the syndesmosis. Fractures below the level of the syndesmosis are classified as A-type, while at the level of the syndesmosis is B-type and above is C-type. This classification is useful for quickly conveying the location of the fracture, however, lacks detail in fracture description and injury mechanism. The AO classification reports the fracture pattern more technically with implication toward severity of injury, but is limited in its usefulness for guiding fixation or describing associated soft tissue injuries.

The mechanism-based Lauge-Hansen classification describes supination external rotation (SER) injuries through a rotational force that begins anteriorly causing failure of the anterior-inferior tibio-fibular ligament (ATFL) and proceeds laterally, transmitting force from the talus to the fibula. This initiates a spiral fracture, which usually progresses from antero-inferior to postero-superior (SER II). Further injury propagates energy posteriorly and medially causing injuries to the posterior and medial malleoli (SER III-IV). This classification guides treatment as it addresses both bony injury and soft tissue injury. Although the Lauge-Hansen ideology has recently been questioned, [12,13] many still use it as a treatment guide and it will be used as the primary reference in this discussion.

Management of a fracture to the distal fibula depends on location, type (classification), and ankle stability. Some low energy, non-displaced fractures of the distal fibula are best managed non-operatively, while higher-energy and displaced fractures with soft tissue compromise are ideally managed with open reduction and internal fixation. Despite classification, when the stability of the ankle mortise is compromised or if associated injuries make non-surgical management unreasonable, a decision must be made regarding both surgical approach and method of fixation.

## Surgical Anatomy and Approaches

The distal fibula is a superficial structure with little overlying soft tissue coverage, allowing for both direct lateral and posterolateral approach.

When direct lateral surgical dissection is chosen, the skin is incised directly to the periosteum over the fracture. There are no internervous or muscular planes to guide this approach; however, the short saphenous vein posterior to the distal fibula and the superficial peroneal nerve (which crosses the lateral border of the fibula ten to twelve centimeters proximal to the tip of the distal fibula) must be protected. The sural and lateral dorsal cutaneous nerves, which supply sensation to the lateral aspect of the leg and to the foot, are also at risk. Excessive elevation of skin flaps should be avoided as this can damage the sural artery as it passes posterior to the peroneal tendons, and could potentially devascularize the skin.

The posterolateral approach is typically performed through an eight to ten centimeter incision located half way between the posterior border of the distal fibula and the lateral border of the Achilles tendon. After incision through skin and subcutaneous tissue, dissection should be carried through the deep fascia of the leg. Again, the short saphenous vein and sural nerve must be protected anterior to the incision. The peroneal tendon sheath will then be visible, and can either be retracted posteromedially or incised in line with the skin incision. If the trans-peroneal tendon sheath approach is used, the peroneal tendons are retracted anteriorly to expose the flexor hallucis longus. Incising the lateral fibers of the flexor hallucis longus provides exposure to the periosteum overlying the distal fibula.

Recently a minimally invasive lateral approach to the fibula has been described. This technique attempts to reduce complications associated with standard approaches, especially in patients with comorbidities such as diabetes, peripheral vascular disease, or the elderly who are at higher risk of wound problems. Regardless of approach chosen due to surgeon comfort, experience, and injury patterns, the techniques and treatment concepts remain unchanged.

## Surgical Fixation Techniques

### Lateral plating

A non-locking one-third tubular plate has traditionally been used for direct lateral fixation of the distal fibula [14,15]. Techniques have evolved over time to include locking compression plates, but traditionally at least two bicortical non-locking screws proximal to the fracture site and at least one cortical or cancellous distally, have been used for fixation. Throughout the literature, the use of bicortical versus unicortical screws for distal fixation is inconsistent. Proponents of the use of bicortical screws argue that this provides superior fixation [7]. The critique of the bicortical technique is the risk of intra-articular screw penetration, and its lack of necessity given the use of an interfragmentary lag screw compression prior to applying a lateral plate.

In osteoporotic bone, many surgeons favor the use of locked plating, which theoretically improves fixation strength. A randomized controlled trial comparing locked versus non-locked lateral neutralization plating [16] showed no difference in time to union, functional score or complication rate, indicating this decision should be made on a case by case basis.

If a minimally invasive surgical approach is chosen for lateral plating, the fracture is reduced percutaneously with traction, rotation and forceps placement. An interfragmentary screw may be inserted percutaneously if desired. A small incision at the distal fibula is made and a soft tissue sleeve is created with an elevator through this incision and above the periosteum. The plate is pre-contoured and then inserted through the distal incision and slid proximally inside the soft tissue sleeve. Screws may be placed through existing incisions or through additional stab incisions. Of note, this technique is appropriate for lateral plating only, as deep structures preclude posterior plating through percutaneous incisions. Proponents of this technique reported on 25 patients with none requiring conversion to standard open approach and no wound complications or infections after one year follow up [17].

## Posterior plating

Similar to lateral plating, a one third tubular plate or locking compression plate is typically used for fixation. At least two bicortical non-locking screws are placed proximal to the fracture. Given the typical postero-superior apex nature of the fracture, an axilla is created, which is supported by the plate. This plate configuration creates an antiglide construct, and some authors argue that no further fixation is required [6,8,11,13,18]. Additional distal unicortical or bicortical screws provide additional stability but negate the antiglide construct. Some also argue for the placement of an inter-fragmentary compression screw perpendicular to the fracture through the plate with or without further distal fixation. This method requires planning when placing the plate such that an accessible hole with correct angulation to the fracture can be chosen.

## Outcomes in the Literature

The clinical and literary pendulum continues to swing between lateral and posterior plating, with advocates on either side demonstrating data to support their position. A summary of pertinent literature and outcomes related to the differing methodologies is presented here.

## Biomechanics

Shaffer and Manoli performed a cadaveric biomechanical study to compare the strength of traditional lateral plating with posterior antiglide plating of the distal fibula [19]. 24 fresh-frozen cadaveric lower extremities were axially loaded using a biaxial electrohydraulic testing system to create SER II fractures (no medial or posterior injury). Ten fibulae were fixed with 5-hole one-third tubular contoured lateral plates with three proximal 3.5 mm bicortical screws and two 4.0 mm unicortical cancellous screws distally. No lag screw fixation was performed. Fourteen fibulae were then fixed with posterior 4-hole one-third tubular antiglide plate with two bicortical 3.5 mm screws proximally and no distal fixation. Each specimen was then loaded in supination external rotation until failure occurred, while the required torque and force to fracture was measured. Additionally, the last 10 consecutive specimens with antiglide plates were re-plated with new screw holes in an antiglide fashion and a lag screw was placed across the fracture. These were then re-tested.

Results from this study demonstrated multiple methods of failure at multiple energy levels. Several lateral plates failed with low energy by a shearing force between distal fragment and plate causing pullout of the distal cancellous screws. Other lateral plates failed at higher energy by fracture through proximal fragment screw holes. Antiglide plates also failed at low energy but showed distal fragment rotation and distal bicortical screw to pull out. Antiglide plates that required high energy to fail also had distal fragment rotation, but demonstrated plate bending instead of screw pullout.

Regardless of the method of failure, the study demonstrated that the antiglide plate had a significantly higher torque to failure when compared to torque required to produce fracture in the lateral plate ( $p<0.01$ ). They also showed that the antiglide plate had significantly higher stiffness and energy absorbed before failure ( $p<0.05$ ). They were unable to demonstrate a significant difference between the antiglide plate group and the antiglide plate group with the addition of a lag screw. Therefore, they concluded that antiglide plate fixation is biomechanically superior to lateral plating for SER II fractures.

A subsequent review by Minihane et al. compared the biomechanical properties of posterolateral antiglide fixation and lateral locked plate fixation for SER II fractures in osteoporotic bone [8]. They compared 18 fresh frozen ankles paired by bone mineral density after DEXA scan. In this study, an oblique distal fibular osteotomy at level of syndesmosis was created and the deltoid ligament was disrupted to simulate an SER IV fracture pattern.

They then performed fixation of nine fractures with lateral one-third tubular locking plate (six hole plate with two bicortical locking screws proximally and two unicortical locking screws distally) with independent lag screw fixation. Posterolateral antiglide plating (five-hole standard one-third tubular plate with two bicortical screws proximally and one bicortical screw distally) was performed on the remaining nine fractures with adjunctive lag screw fixation through the plate. Following fixation, ankles were loaded in external rotation at controlled rate, during which time torque to failure, angular rotation at failure, and construct stiffness were recorded.

Results demonstrated a significantly higher ( $p=0.01$ ) torque to failure and significantly higher ( $p=0.005$ ) construct stiffness with posterolateral antiglide plate fixation. However, there was no significant difference in angular rotation at failure. The lateral plate failed by cutting out of distal fragment with intact plate and screws. The antiglide plate had seven failures by bending of the plate at the distal diaphyseal screw site and two failed by pullout of screws from the diaphysis. These results demonstrated improved biomechanical stability in posterior antiglide plating as compared to lateral locking plate in osteoporotic bone although no cyclic loading was performed to reproduce early postoperative failures and surgical osteotomy does not accurately represent comminution commonly seen in fractures of osteoporotic bone.

Various authors have discussed unsatisfactory fixation of the distal fragment with lateral plating and unicortical cancellous screws in osteoporotic or comminuted bone. This can lead to loss of fixation, and potential delayed or lack of bony healing [3,4,11] These risks are obviated by the use of a posterior antiglide plate as the posterior to anterior screw orientation does not risk intra-articular penetration even with bicortical fixation.

As a rebuttal to this argument for posterior anti-glide plating, some have suggested the use of a lateral plate with bicortical distal screws based on intricate knowledge of the distal fibular anatomy [7]. Milner et al. reported on the anatomical dissection of 16 cadaver feet and noted that less than half of the total medial surface of the fibula distal to the tibial plafond is articular [7]. Based on this, three zones were described to guide fixation placement. Zone I consisted of the most distal 1.5 cm of the fibula. In this region, the most posterior aspect of the fibula is extra-articular and they suggest that angling bicortical distal screws angled 10 degrees posterior will avoid the complication of intra-articular screw placement. Zone II is the next 11 mm proximal to Zone I and is almost entirely intra-articular. They suggest that bicortical screws in this zone can only be placed safely by angling the screw trajectory 25 degrees cephalad and 10-15 degrees posterior to avoid contact with more proximal screws. Zone III is the level of the fibula above the ankle joint and bicortical screws can be placed in this location without concern for intra-articular penetration. Based on this study, bicortical fixation of the fibula through a lateral plate may in fact be safe and would be preferable to the standard unicortical fixation due to greater pullout strength.

In response to the development of modern polyaxial locking devices, Hallbauer et al. performed a biomechanical study comparing performance of a lateral locking plate and a posterolateral (anti-glide) locking plate [20]. 14 fibulae were osteotomized at the level of the syndesmosis and fixed either laterally or postero-laterally with an interfragmentary lag screw. All plates were precontoured polyaxial locking plates. Specimens were tested for both torsional and bending stiffness with a load of 30 N. In contrast to previous studies demonstrating increased strength with antiglide constructs, this study showed no significant differences between groups. There was a trend towards higher bending stiffness and lower range of motion in the laterally plated group, however this was not statistically significant. Unfortunately these specimens lacked surrounding soft tissue stabilization, and were not tested to failure. As polyaxial locked constructs become more popular it will be important for future studies to expand on the comparison of plate placement with this fixation method.

### Soft Tissue Concerns

Brown et al. retrospectively reviewed the incidence of soft tissue complications and outcomes in 126 patients who underwent open reduction and internal fixation of SER type fractures with a lateral plate during a four year period [5]. Each of these patients were followed for at least six months after injury. They utilized the Short Form-36 (SF-36) Survey and the Short Musculoskeletal Function Assessment (SMFA) to compare results along with detailed patient interviews and analog pain scales. 31% of patients had ongoing lateral ankle pain and 23% had either had their hardware removed or desired to have it removed. Only eleven patients (50% of those who underwent removal) had improvement in their lateral ankle pain after hardware removal. The SF-36 and SMFA scores at final follow-up were significantly lower for patients who had pain, however no significant difference was noted in SMFA or SF-36 scores in those patients who had hardware removed. This study demonstrates that lateral plating causes a substantive amount of ongoing irritation for patients.

If a minimally invasive approach is utilized for placement of a lateral plate there is a theoretical increased risk of neurovascular injury as these structures are not directly visualized and protected. This risk is increased with longer plates as they require instrumentation more proximally along the fibula. A cadaveric study demonstrated direct contact between the plate and the superficial peroneal nerve in 11 of 20 ankles fixed with 10-hole LCP plates (both one-third tubular and straight 3.5 mm LCP). The sural nerve did not contact any plates however is at risk with incisions distal to the tip of the fibula [21]. Therefore, care must be taken to diligently protect soft tissues and utilize shorter plates whenever possible.

Wissing et al. also argued that lateral plating is fraught with several potential soft tissue concerns [13]. In cases of severe soft tissue injury, lateral position of plate more easily becomes exposed or irritating to the lateral skin. Also, the shape and bony structure of distal fibula is not uniform, and a lateral plate must be contoured in order to be seated against the bone, potentially compromising plate mechanics. The thin cortex may not provide adequate fixation distally, and distal screws can easily penetrate the tibiofibular and fibulotalar joints [22]. A proponent of posterior plating, Wissing et al. retrospectively reviewed 48 ankle fractures fixed with a one-third tubular posterior anti-glide plate over a 5-year period. Their results demonstrated that plate positioning caused no symptoms and no limitation of active or passive mobility of ankle joint. They also noted no soft tissue infection

and reported that all patients seen in follow up obtained good mobility of the tibiotalar joint. Unfortunately their findings, although impressive, list no raw data or statistical comparisons and fail to elaborate on specific range of motion achieved by patients in the postoperative time period. This makes it difficult to ascertain the clinical relevance.

Soft tissue irritation has been noted in posterior plating, specifically with the peroneal tendons. Weber and Krause performed a retrospective review of 70 patients treated with posterior antiglide plating and found 43% of patients underwent hardware removal for signs of peroneal tendonitis [10]. However, not all second surgeries could reliably demonstrate irritation caused by the plate as opposed to previous surgical intervention or pathology from the initial injury. They noted intraoperative peroneal tendon lesions in only 30% of hardware removals. Furthermore, they found that plate position did not correlate with the presence or absence of peroneal tendon lesions. However, pain was strongly correlated to use of the most distal hole in the plate, presumably due to screw head prominence. Based on these findings, antiglide plating with a low placement of plate and protruding distal screw heads should be avoided, or hardware should be removed early if this is necessitated based on anatomic differences.

Lamontagne et al. published a retrospective report in 2002 comparing lateral and posterior antiglide fixation of the distal fibula [6]. This is the first and only clinical direct comparison between treatment options. 193 patients with closed, isolated, displaced fibular fractures were fixed with either lateral (n=108) or posterior (85) 1/3 tubular plating based on surgeon preference and followed for at least one year. Anteroposterior lag screws were placed in lateral plate group where possible (86%) and outside of the plate in the antiglide plate (92%). 79% of antiglide plates had screws only proximal to fracture and the remaining had screws through the plate in distal fragment or a posteroanterior lag screw through the plate [23].

Results suggested a higher incidence of hardware removal for lateral plates than antiglide plates, but that this difference was not statistically significant (16.6% vs 12.9%). A higher proportion of discomfort was noted over a lateral plate (12% vs 7%) but this irritation was often not sufficient to warrant hardware removal. Rates of infection and wound dehiscence were slightly higher in the lateral plating, but these lacked statistical significance. The study also concluded that there was no statistical difference in outcome measures clinically, with similar mean ankle scores (89% vs. 91%), although functional results were limited by loss to follow up. Their ultimate recommendation was that no concrete evidence exists to support one treatment modality over another.

### Operative Time/ Tourniquet Time

To date, the only study to directly compare lateral versus antiglide plating options in multiple operative variables is the previously cited 2002 review by Lamontagne et al. [6]. Their results demonstrated no statistically significant difference between lateral and posterior plating in operative time (48.9 versus 42.6 minutes), tourniquet time (48.9 versus 44.3 minutes), or length of hospital stay (3.2 versus 3.0 days). Further studies are needed to illuminate any technical differences between these methods [24].

### Conclusion

The differences between lateral and posterolateral plating for fibula fractures are well described in the literature. However, to date there still exist very few studies that directly compare the two modalities of

fixation. It is evident that lateral plating with interfragmentary compression may be technically easier, but can result in problems including risk of intra-articular screw penetration and poor distal fixation. Posterior antiglide plating is biomechanically superior when using a non-locked construct, but leads to peroneal irritation and is technically more demanding secondary to exposure. Discussion of other potential differences including operative time, the use of interfragmentary compression screws, and the true incidence of soft tissue complications have not been fully explored in the literature, and are still points of debate and question. Each method has its benefits and limitations, and should be utilized with these in mind. As is evidenced by this review, there is not yet a “gold standard” to fibular fixation in short oblique fractures. Presently, the decision for fixation should be based on best clinical judgment, patient factors, and surgeon comfort or ability with the treatment method.

## References

1. Hughes JL, Weber H, Willenegger H, Kuner EH (1979) Evaluation of ankle fractures: non-operative and operative treatment. *Clin Orthop Relat Res* 138: 111-119.
2. Petrone FA, Gail M, Pee D, Fitzpatrick T, Van Herpe LB (1983) Quantitative criteria for prediction of the results after displaced fracture of the ankle. *J Bone Joint Surg* 65: 667-677.
3. Beauchamp CG, Clay NK, Thexton PW (1983) Displaced ankle fractures in patients over 50 years of age. *J Bone Joint Surg* 65: 329-332.
4. Broos PL, Bisschop AP (1991) Operative treatment of ankle fractures in adults: correlation between types of fracture and final result. *Injury* 22: 403-406.
5. Brown OL, Dirschl DR, Obremskey WT (2001) Incidence of hardware-related pain and its effect on functional outcomes after open reduction internal fixation of ankle fractures. *J Orthop Trauma* 15: 271-274.
6. Lamontagne J, Blachut PA, Broekhuysen HM, O'Brien PJ, Meek RN (2002) Surgical treatment of a displaced lateral malleolus fracture: the antiglide technique versus lateral plate fixation. *Journ Orthop Traum* 16: 498-502.
7. Milner BF, Mercer D, Firoozbakhsh K, Larsen K, DeCoster TA, et al. (2007) Bicortical screw fixation of distal fibula fractures with a lateral plate: an anatomic and biomechanical study of a new technique. *J Foot Ankle Surg* 46: 341-347.
8. Minihane KP, Lee C, Ahn C, Zhang L, Merk BR (2006) Comparison of lateral locking plate and antiglide plate for fixation of distal fibular fractures in osteoporotic bone: a biomechanical study. *J Orthop Trauma* 20: 562-566.
9. Ryken TC, Goel VK, Clausen JD, Traynelis VC (1995) Assessment of unicortical and bicortical fixation in a quasistatic cadaveric model: role of bone mineral density and screw torque. *Spine* 20: 1861-1867.
10. Weber M, Krause F (2005) Peroneal tendon lesions caused by antiglide plates used for fixation of lateral malleolar fractures: the effect of plate and screw position. *Foot Ankle Int* 26: 281-285.
11. Brunner CE, Weber BG (1983) The antiglide plate. In: *Special Techniques in Internal Fixation*. Springer-Verlag. pp: 115-133.
12. Treadwell JR, Fallat LM (1993) The antiglide plate for Danis-Weber type B fibular fractures: a review of 71 cases. *J Foot Ankle Surg* 32: 573-579.
13. Wissing JC, van Laarhoven CJ, van der Werken C (1992) The posterior antiglide plate for fixation of fractures of the lateral malleolus. *Injury* 23: 94-96.
14. Michelson JD (1995) Fractures about the ankle. *J Bone Joint Surg Am* 77: 142-152.
15. Michelson JD (2003) Ankle fractures resulting from rotational injuries. *J Am Acad Orthop Surg* 11: 403-412.
16. Tsukada S, Otsuji M, Shiosaki A, Yamamoto A, Komatsu S, et al. (2013) Locking versus non-locking neutralization plates for treatment of lateral malleolar fractures: a randomized controlled trial. *Int Orthop* 37: 2451-2456.
17. Carlile GS, Niles NCL (2011) Surgical technique for minimally invasive fibula fracture fixation. *Foot Ankle Surg* 17: 119-123.
18. Winkler B, Weber BG, Simpson LA (1990) The dorsal antiglide plate in treatment of Danis-Weber type B fractures of the distal fibula. *Clin Orthop* 259: 204-209.
19. Schaffer JJ, Manoli A (1987) The antiglide plate for distal fibular fixation. A biomechanical comparison with fixation with a lateral plate. *J Bone Joint Surg Am* 69: 596-604.
20. Hallbauer J, Klos K, Rausch S, Grafenstein A, Dipl-Ing FW, et al. (2014) Biomechanical comparison of a lateral polyaxial locking plate with a posterolateral polyaxial locking plate applied to the distal fibula. *Foot Ankle Surg* 20: 180-185.
21. Neubauer T, Heidari N, Weinberg AM, Grechenig W, Tesch NP, et al. (2011) The risk of nerve injury with minimally invasive plate osteosynthesis of distal fibula fractures: an anatomic study. *Arch Orthop Trauma Surg* 131: 1409-1412.
22. Harper MC (1995) The short oblique fracture of the distal fibula without medial injury: An assessment of displacement. *Foot Ankle Int* 16: 181-186.
23. Ostrum RF (1996) Posterior plating of displaced Weber B Fibula Fractures. *J Orthop Trauma* 10: 199-203.
24. Reffern DJ, Suave PS, Sakellariou A (2003) Investigation of incidence of peroneal nerve injury following ankle fracture. *Foot Ankle Int* 24: 771-774.