

Case Report

Open Access

A Case of Encephalitis Secondary to NMDA Receptor Antibody with Concurrent Striational Antibodies and Thymic Hyperplasia

Gabriel D McCoy*, Mark Call and Mansi Patel

Greenville Health System, Greenville, SC, USA

Introduction

The number of paraneoplastic encephalitis cases has been gradually rising. The most common one being anti-N-methyl-D-aspartate (NMDAR) encephalitis (over 120 cases reported in literature) [1]. Various other synaptic antibodies have also been associated with autoimmune encephalitis. These include: anti-leucine-rich glioma-inactivated protein (LGI1), anti- α -amino-3-hydroxy-5-methyl-4-isoxazolepropionic acid (AMPA), anti-gamma-aminobutyric acid (GABA-B) receptor, and anti-contactin-associated protein 2 (CASPR-2) [2]. Symptoms of NMDAR encephalitis may vary but are most commonly associated with progressive cognitive decline, psychiatric symptoms, and even seizures [3,4]. The psychiatric manifestations are closely related to the anti-NMDAR antibody predilection for the limbic system. These include emotionally charged psychosis and waxing and waning hallucinations, with appropriate cognitive clarity. There have been documented cases of catatonia, hypoventilation, and dyskinesia's associated with Anti-NMDAR encephalitis [3,4].

The production of the antibody is thought to occur from occult malignancies as a paraneoplastic finding. Once the antibody is produced, it disrupts the NMDAR in the brain. Previous studies suggested that the antibody may inhibit neurotransmitter function by destroying the receptor via CD8 signaling [3]. Due to the blood brain barrier impedance of CD8 molecule, this has been largely discounted. Alternative explanations suggest that antibodies may induce capping and internalization of the receptor which is reversible. In rat models, blockage of the NMDA receptor by the antibody was shown to decrease the density of the receptors in the brain and subsequently decreased the overall frequency of neurotransmission.

To our knowledge, the exact mechanism of why these antibodies cause encephalitis is currently unknown; however, paraneoplastic anti-NMDAR encephalitis cases have been most commonly associated with ovarian teratomas [2,5,6]. Other uncommon tumor sources include thymus, lung, breast, testis [7], and lymph nodes [5]. However, Dalmau et.al. observed that approximately 41% of cases of NMDAR encephalitis had no clinically detectable tumor at diagnosis [4]. There have been cases of anti-NMDAR encephalitis presenting before oophorectomies with subsequent pathological evidence of ovarian teratomas without radiological evidence of tumor at diagnosis [8,9]. Evidence suggests there should be initial screening for malignancy at diagnosis consisting of either a Computed Tomographic (CT) image of the abdomen and pelvis, or transvaginal ultrasound, or both. Serial surveillance with Magnetic Resonance Imaging (MRI) of the abdomen and ultrasound for up to two years after diagnosis has also been recommended [8,10]. However, very little data exists to validate this recommendation for subsequent malignancy screening.

Case Presentation

We report a case of a 30 year old morbidly obese black female who presented to the hospital with her family after being found in an altered state of mind for 24 hours. She had complained to her family for three weeks of a slow onset headache. She had been evaluated, and was diagnosed with simple migraine headaches after a negative Computerized Tomography (CT) scan of the head in an emergency

department. Subsequently, she returned to another outside hospital with similar complaints and was given fioricet for her headaches. This intervention improved her symptoms until one day prior to admission, the patient abruptly began singing loudly and talking nonsensically. She began to have tangential conversations interrupted by loud screams and combativeness. She denied any neck stiffness, visual changes, motor dysfunction, or paralysis. No other neurological signs were noted. There were no reported tuberculosis contacts, or animal bites in the patient's history.

Her medical history consisted only of hypertension and morbid obesity. She was a non-drinker and denied use of any illicit drugs or tobacco.

Physical exam revealed a temperature of 101.0°F in the emergency department with a pulse of 124 beats per minute and was found to be combative, violent, and talking incoherent sentences. She was noted to have some minor left sided horizontal beating nystagmus. Cranial nerves II-XII were intact, motor examination was grossly normal with normal reflexes in bilateral upper and lower extremities with a GCS score of 15. No overt seizures had been witnessed by any nursing staff. At multiple times during the hospital course, the patient was able to describe the date, time, location, and current events. Within a matter of minutes, the patient would become completely disoriented. All basic labs were within normal limits (Complete blood count, comprehensive metabolic profile). Three lumbar punctures were performed in large volume. The results of both serum and CSF are summarized in (Table 1). Two separate meningioencephalitis panel samples were analyzed and both were found to be negative. Pathology and cytology were performed on both samples of CSF which revealed no malignancy or abnormal cell findings. An Electrical Encephalogram (EEG) was performed and showed nonspecific cerebral dysfunction in the left frontotemporal region with asymmetrical appearance compared to the right hemisphere, with no epileptiform discharges consistent with the clinical diagnosis of encephalitis.

The patient had a Magnetic Resonance Image (MRI) of the brain performed upon admission which was negative (Figure 1). Computed tomographic angiography of the brain showed normal study as well. Computerized tomographic image of the abdomen and pelvis was negative. In an effort to better visualize the ovaries; a transvaginal ultrasound was performed and revealed no abnormal findings.

Direction was then turned to alternative explanations for the newly resulted positive serum anti-striational antibodies. Given the

*Corresponding author: Gabriel D McCoy, Greenville Health System, Greenville, SC, USA, Tel: +1 864-455-7000; E-mail: gmccoy@ghs.org

Received June 17, 2014; Accepted July 28, 2014; Published July 30, 2014

Citation: McCoy GD, Call M, Patel M (2014) A Case of Encephalitis Secondary to NMDA Receptor Antibody with Concurrent Striational Antibodies and Thymic Hyperplasia. J Clin Case Rep 4: 396. doi:10.4172/2165-7920.1000396

Copyright: © 2014 McCoy GD, et al. This is an open-access article distributed under the terms of the Creative Commons Attribution License, which permits unrestricted use, distribution, and reproduction in any medium, provided the original author and source are credited.

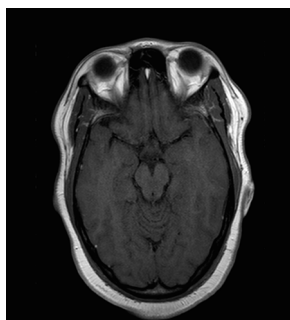


Figure 1: Magnetic resonance image of the brain.

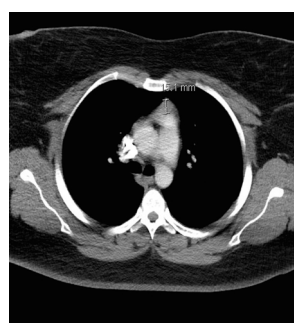


Figure 2: CT thorax showing abnormal mediastinal mass consistent with thymic hyperplasia.

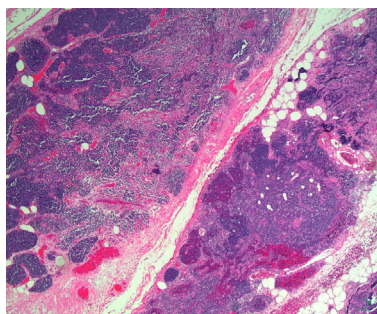


Figure 3: Low power pathology image of removed thymic tissue.

predominance of thymomas with the findings of anti-striational antibodies, a computerized tomographic image of the thorax was obtained and revealed an abnormally large thymus (Figure 2). Given the clinical suspicion, and abnormal thymus, the thymus was excised surgically without any intraoperative findings of an abnormal mass. Pathology results from the thymus revealed thymic hyperplasia with no pathological evidence of thymoma (Figure 3).

Management

The patient was initially thought to have viral encephalitis when she presented with an elevated temperature and altered mental status. She was started on acyclovir which was continued for one week until herpes simplex viral Polymerized Chain Reaction (PCR) was found to be negative. She was given prednisone and multiple antipsychotic medications during the hospitalization. None of the administered medications had a known pharmacological effect on the NMDA receptor. IVIG was administered to the patient subsequently with very

little improvement in symptoms. Given the miniscule improvement, and receipt of the anti-striational antibody results, a tunneled catheter was placed for vascular access and the patient underwent plasmapheresis for a total of four treatments. She then underwent a robotic thymectomy as a definitive treatment. Shortly after the thymectomy was performed, positive results for anti-NMDAR encephalitis were reported in the CSF but not serum.

Discussion

NMDAR antibody was eventually found in the CSF sample after a considerable amount of therapies had been completed and improvement was noted. Interestingly, the serum NMDAR antibody sample was found to be negative within two weeks. Both CSF and serum samples were sent for analysis as NMDAR antibodies typically have a much higher concentration in the CSF than they do in the serum [3]. This concentration disparity is thought to be secondary to early treatment with IVIG and plasmapheresis. The early treatment with IVIG and plasmapheresis was evident as the sample was sent two days after these were initiated. This may have caused a false negative concentration in the serum. This point underscores the extreme importance of examining both CSF and serum for antibodies.

Additionally, the first lumbar puncture that was performed yielded CSF with only a lymphocytic pleocytosis without other abnormalities. A lymphocytic pleocytosis may be indicative of lymphoma; however, cytology was negative in this case. NMDAR antibody is one of the few encephalitic diseases which cause a lymphocytic pleocytosis [4]. Being conscious of a lymphocytic pleocytosis in CSF may allow early diagnosis and allow the clinician to send off the NMDAR antibody test earlier in the hospitalization. Other than serology and CSF analysis, the T2 weighted MRI has a 50% sensitivity for detecting the disease when clinically suspected [3,4]. When positive, the hyper-signal is typically seen in the temporal lobes [4]. In our case, this was not evident (Figure 1).

The absence of a clinically apparent ovarian tumor is seen in up to 41% of patients with this disease process. This patient had negative imaging of the abdomen and pelvis by CT scan in addition to a negative β -hCG. While MRI of the abdomen and pelvis may yield more information, the specificity is low when attempting to screen for malignancy. This case highlights another example of a patient that presented without immediate radiological evidence of a tumor. Additionally, the patient did not have clinical evidence of other sources of anti-NMDAR which have been reported (lymphoma, lung, breast or testicular cancer). Ultimately, the patient workup led to the discovery of the anti-striational antibody. Excision of the thymic tissue in combination with plasmapheresis was thought to be necessary to give definitive treatment to the patient. Interestingly, there have been only a few case reports on encephalitis related to anti-striational antibodies [1,11,12]. This was an unlikely source for her symptoms given that previous cases of encephalitis attributed to the thymus were exclusively related to thymoma and not thymic hyperplasia [1,11-13]. However, in the absence of radiological proven malignancy, thymic hyperplasia must be considered a potential source of the anti-NMDR antibody. There has been only one reported case of thymic hyperplasia with presumptive anti-N-methyl-D-aspartate (NMDAR) encephalitis [14]. However, that case was in a patient who was found to be seronegative for the antibody.

Occult ovarian teratoma may also be a recognized source in this case. Although the patient had initial imaging performed in accordance with previous studies, there was no observed tumor. There is little

CSF	Serum
Viral Adenovirus Antibody: (-) Arbovirus: (-) BK Virus DNA: (-) California encephalitis IgG, IgM: (-) CMV IgG, IgM: (-) CMV DNA PCR quant: (-) Coxsackie B Antibodies(A2,4, 7,9,10,16) : (-) Coxsackie A Antibodies (B1-6) : (-) Eastern Equine IgG, IgM: (-) EBV DNA PCR qualitative and quantitative: (-) Echovirus Antibodies (4,7,9,11,30) : (-) Enterovirus RNA PCR : (-) HSV 1 and 2 IgG and IgM: (-) Influenza A and B Antibodies: (-) Lymphocytic Choriomeningitis IgG, IgM: (-) Measles IgG, IgM: (-) Mumps IgG, IgM: (-) St. Louis Encephalitis IgG, IgM: (-) Varicella-Zoster Antibody: (-) Western Equine IgG, IgM: (-) West Nile IgG, IgM: (-)	Viral HIV RNA: (-) HIV antigen Antibody screen: (-) West Nile Virus IgG, IgM: (-) EBV DNA PCR: (-) CMV PCR: (-)
Bacterial Cryptococcus antigen: (-) VDRL: (-) Borrelia Burgdorferi IgGm, IgM: (-)	Bacterial (min. reactive) FTA Absorption (-) FTA Absorption (6/21) (-) RPR x 2 Bartonella Henselae IgG, IgM, and Antibody titer: (-) Bartonella Quintana IgG, and Antibody titer: (-)
Paraneoplastic panel AMPA-Receptor Antibody CBA: (-) Antineuronal cell: (-) NMDA-R Antibody: (+)	Paraneoplastic panel AGNA-1 : (-) AMPA-R Antibody CBA: (-) CRMP-5 IgG: (-) CASPR-2 Antibody: (-) LGI1 Antibody: (-) NMDA-R Antibody: (-) x 2 P/Q type Ca2+ channel Antibody: (-) N-type Ca2+ Channel Antibody: (-) Ach Receptor (muscle) Bindin: (-) Ach Receptor Ganglionic Neuronal Antibody: (-) Neuronal (V-G) Potassium Channel Antibody: (-) muscle AChR modulation striational Antibodies: (+)
CSF Sample #1: clear, colorless RBC 10 (/CUMM) WBC 555 (/CUMM) PMN 0% Lymphocytes 90% Monocytes 10% Glucose 66 mg/dl Total protein 19.1 mg/dl LDH 18 IU/L	CSF Sample #2: clear, colorless RBC 2 (/CUMM) WBC 27(/CUMM) PMN 0% Lymphocytes 23% Monocytes 4% Other cell types 73% Glucose 58 mg/dl Total protein 20.1 mg/dl LDH 0 IU/L

Table 1: Table with summary of the battery of tests done on both CSF and serum.

evidence to support a prophylactic oophorectomy. Patients with anti-NMDR antibody encephalitis without clinical tumor evidence have a higher relapse rate [10]. Accordingly, serial imaging of the abdomen and pelvis has been continued in this patient on an outpatient basis.

The treatment for NMDAR antibody encephalitis is typically started with high dose steroids which is followed by administration of IVIG [2,5]. Plasma exchange has been found efficacious in extracting the antibodies [6,14,15]. This patient showed a drastic improvement with plasma exchanged but minimal change with steroids and IVIG. Refractory cases are typically treated with rituximab or cyclophosphamide [15]. Additionally, if there is a recognized source of the antibody, it should be removed [8,9]. In this case, the patient had her thymus removed which may have been a plausible source of the antibody production.

The overall prognosis of this disease process is very favorable. Over 75% of patients have only minimal lasting neurological effects

ranging from extremity numbness to dizziness [15]. Although much is not known about the prevalence of this disease, there is thought to be a recurrence in about 20-25% of patients who are effected [16]. Currently, the NMDAR antibody assay carries a 100% specificity and unknown sensitivity. The source of our patient's NMDAR antibody was elusive. The patient has made a complete recovery one year from the diagnosis and has been undergoing periodic imaging and screening for malignancy.

References

1. Suh JW, Haam SJ, Song SW, Shin YR, Paik HC, et al. (2013) Paraneoplastic encephalitis associated with thymoma: a case report. Korean J Thorac Cardiovasc Surg 46: 234-236.
2. Thieben MJ, Lennon VA, Boeve BF, Aksamit AJ, Keegan M, et al. (2004) Potentially reversible autoimmune limbic encephalitis with neuronal potassium channel antibody. Neurology 62: 1177-1182.
3. Dalmau J, Lancaster E, Martinez-Hernandez E, Rosenfeld MR, Balice-Gordon

- R (2011) Clinical experience and laboratory investigations in patients with anti-NMDAR encephalitis. *Lancet Neurol* 10: 63-74.
4. Dalmau J, Gleichman AJ, Hughes EG, Rossi JE, Peng X, et al. (2008) Anti-NMDA-receptor encephalitis: case series and analysis of the effects of antibodies. *Lancet Neurol* 7: 1091-1098.
5. Hammoud K, Kandimala G, Warnack W, Vernino S (2009) Multifocal paraneoplastic cortical encephalitis associated with myasthenia gravis and thymoma. *Arch Neurol* 66: 1407-1409.
6. Rickman OB, Parisi JE, Yu Z, Lennon VA, Vernino S (2000) Fulminant autoimmune cortical encephalitis associated with thymoma treated with plasma exchange. *Mayo Clin Proc* 75: 1321-1326.
7. Huang GZ, Lo YL (2013) Correlation between acetylcholine receptor antibody levels and thymic pathology in myasthenia gravis: a review. *J Clin Neuromuscul Dis* 14: 209-217.
8. Ferdinand F, Mitchell L (2012) Anti-NMDA Receptor Encephalitis. *J Clin Cell Immunol*, S10
9. Iizuka T, Sakai F, Ide T, Monzen T, Yoshii S, et al. (2008) Anti-NMDA receptor encephalitis in Japan: long-term outcome without tumor removal. *Neurology* 70: 504-511.
10. Florance NR, Davis RL, Lam C, Szperka C, Zhou L, et al. (2009) Anti-N-methyl-D-aspartate receptor (NMDAR) encephalitis in children and adolescents. *Ann Neurol* 66: 11-18.
11. Uehara T, Murai H, Yamasaki R, Kikuchi H, Shigeto H, et al. (2011) Thymoma-associated progressive encephalomyelitis with rigidity and myoclonus successfully treated with thymectomy and intravenous immunoglobulin. *Eur Neurol* 66: 328-330.
12. Vernino S, Lennon VA (2004) Autoantibody profiles and neurological correlations of thymoma. *Clin Cancer Res* 10: 7270-7275.
13. Chaudhry MS, Waters M, Gilligan D (2007) Paraneoplastic limbic encephalitis attributable to thymoma. *J Thorac Oncol* 2: 879-880.
14. Shah R, Veerapandiyan A, Winchester S, Gallentine W, Mikati MA (2011) Two patients with an anti-N-methyl-D-aspartate receptor antibody syndrome-like presentation and negative results of testing for autoantibodies. *Pediatr Neurol* 45: 412-416.
15. Day GS, High SM, Cot B, Tang-Wai DF (2011) Anti-NMDA-receptor encephalitis: case report and literature review of an under-recognized condition. *J Gen Intern Med* 26: 811-816.
16. Rosenfeld MR, Dalmau J (2011) Anti-NMDA-Receptor Encephalitis and Other Synaptic Autoimmune Disorders. *Curr Treat Options Neurol* 13: 324-332.