



---

## Research Article

---

### PRELIMINARY PHYTOCHEMICAL ANALYSIS AND ORAL ACUTE TOXICITY STUDY OF THE ROOT OF *ARGEMONE MEXICANA* LINN.

Mergu Prasad<sub>1</sub>, Satya Prasad Venugopal<sub>2</sub>\*

1. Department of Anatomy, Medici Institute of Medical Sciences, Hyderabad, Telangana, India

PhD Scholar of Saveetha University, Saveetha University, Chennai, Tamil Nadu, India.

2. Department of Anatomy, MNR Medical College, Sangareddy, Telangana, India

\*Corresponding author's Email: [satyaprasad33@yahoo.co.in](mailto:satyaprasad33@yahoo.co.in)

(Received: November 24, 2015; Accepted: January 07, 2016)

#### ABSTRACT

**Objectives:** The current study was planned to evaluate the phytochemical analysis of chloroform, ethanolic extracts and acute toxicity study of the root of *Argemone mexicana*.

**Methods:** The soxhalete extraction and standard methods were used for extractions and phytochemical analysis. The drug was administration orally and animal's observed from cage side observations. Animals were anesthetized with ether anesthesia, blood was collected from orbital puncture and analysis was made by standard methods. Various organs were collected, weighted and transferred to cassettes. Fixation was made with 10% buffered formalin and processed for histological embedding by Carleton's histological techniques. Statistical data were analyzed by statistical software Sigma Plot 10.

**Results:** The phytochemical analysis of ethanol extract revealed presence of alkaloids, amino acids, phenolics and fatty acids and chloroform extract revealed presence alkaloids, tannins, flavonoids and phytosterols. The oral acute toxicity study showed no noticeable clinical signs of toxicity and mortality during 14 days of the study period. No statistically significant alterations in body weights, organ weights and hematological parameters compared to control group. The microscopic anatomy of the liver and the reproductive organs showed a normal architecture.

**Conclusions:** We conclude that the outcome of the present study may add scientific information of ethanolic, chloroform extracts and acute toxicity study of the root of *Argemone mexicana* to the system of medical specialization. Ethanolic extract of root of *Argemone mexicana* was found to be nontoxic up to 5000 mg/kg body weight, so the LD50 is greater than 5000 mg/kg body weight.

**Keywords:** Phytochemicals, toxicity study, *Argemone mexicana*, root.

#### INTRODUCTION

Medicinal plants are a fertile source of bioactive phytochemicals, investigations of these plants have achieved in overcoming the complications linked with synthetic drugs in managing little toxicity and less side effects. As per World Health Organization survey around 80% of the world's population of developing countries relies on traditional medication in primary healthcare sectors<sup>1</sup>.

The biologically active naturally occurring chemical compounds found in the plants referred to as phytochemicals ('Phyto-'from Greek - Phyto meaning 'plant') which offer health benefits for humankind. The plant phytochemicals are known for their anticancer, antioxidant, immunity-potentiating, detoxifying functions and neuropharmacological properties. Phytochemicals are classified into tannins, alkaloids, flavonoids, steroids,

glycosides, saponins, terpenes, phenolics, essential oils and anthraquinones<sup>2</sup>.

The toxin is a substance that is capable of producing the illness or death of a living organism when absorbed or introduced. Some substances are relatively harmless after doses in excess of several grams, while others may be produce death in microgram doses<sup>3</sup>. The toxicity produced by a substance when administered in one or more doses during a period not exceeding twenty four hours is known as acute toxicity. Any medicinal substance intended for human use should be tested for acute toxicity study in animals<sup>4</sup>. Routinely the acute toxicity studies used to determine symptoms of toxicity and effects on hematological, biochemical, and histological parameters<sup>5</sup>. Before clinical trial toxicity studies prove the safety and efficacy of herbal and natural drugs provide guidelines for choosing a safe dose in humans<sup>6,7</sup>.

The exotic indigenous weed *Argemone Mexicana* belongs to the family Papaveraceae, it is an erect annual herb commonly known as Mexican prickly poppy, though it is native to South America it is also widely distributed in many sub-tropical and tropical countries, including West Africa, India where it grows in cultivating fields, waste lands and roadsides<sup>8, 9</sup>. Previous works on the root of *Argemone mexicana* have reported several medicinal properties like used in chronic skin diseases, guinea-worm infection, pruritus, leprosy, inflammations, blennorrhagia, all types of poisoning, flatulence, constipation, colic, vesicular calculus, diuretic, anodyne, hypotonic, antihelmentic, malarial fever, antioxidant activity, to treat vaginal discharge and Hepatobiliary problems<sup>9-13</sup>. The *Argemone mexicana* is reported to have reduced sugars, sugars, tannins, flavonoids, carbohydrates, alkaloids and steroids as its phytochemical constitution<sup>14, 15</sup>.

Even though a great deal of scientific literature is available on the phytochemical constituents and toxicity studies of *Argemone mexicana* whole plant, leaves, flowers, aerial parts, and seeds, the phytochemical analysis of chloroform extract and toxicity study of the root of *Argemone* is completely missing. Thus the present study is planned to evaluate the phytochemical analysis of chloroform, ethanolic extracts and acute toxicity of ethanolic extract of root of

*Argemone mexicana* along with the cytoarchitectural study of certain organs.

## MATERIALS AND METHODS

### Plant material

The plant material was collected in the month of May from Hyderabad-17° 22' 31" North, 78° 28' 28" East, Telangana, India, Asia and authenticated by Head of Botany Department, Osmania University, Hyderabad, Telangana, India. The plant specimen was identified as *Argemone mexicana* L., it belongs to family Papaveraceae. The voucher No.023 specimen sample of the plant was deposited in the Department Herbarium for future reference.

### Extraction

After collection of the plants, the roots were broken up, rinsed thoroughly in tap water and dried in shade for about 20 days under controlled temperature ( $25 \pm 2$  °C). Then the crude material was powdered, passed through a 40 mesh sieve and stored in a well closed container for further usage. Coarsely powdered and dried root was successively Soxhlet extracted using petroleum ether, chloroform, ethanol for 72 h. The extracts were filtered and the solvents were evaporated to dryness under reduced pressure in an Eyela rotary evaporator at 40 °C to 45 °C. The root extract was subjected to phytochemical evaluation.

### Phytochemical analysis

The phytochemical analysis of alkaloids, carbohydrates, steroids, phenolics, flavonoids, amino acids, phytosterols, tannins, and fatty acids were performed according to standard methods<sup>16, 17</sup>.

### Animals

Fifteen adult female Wistar rats of age around six months and weighing close to 200-210 g were used for the experimental study. The rats were acquired In-house from Teena Biolabs Pvt. Ltd, Hyderabad, Telangana, India. The rats were acclimatized to the laboratory conditions for a week before the start of the experiments; they were maintained as per the Institutional ethical committee (IAEC) norms. The rats were maintained with 12 hour dark and light cycle with food and water at ad libitum. The study procedures involving the treatment and handling of animals were approved by the Institutional ethical committee by the Institutional Ethical Committee Teena Biolabs Pvt. Ltd.

Reg. No. 177/PO/cb/99/CPCSEA. Project No: TBLSTPRJ0032014.

#### **Acute toxicity study**

At aggregate of fifteen rats were randomly divided into three groups, each containing five rats. The control group (C) was given normal standard diet. The two treated groups were given oral administration of a single dose of ethanolic extract of Argemone Mexicana root 2000 mg/kg (AE2) and 5000 mg/kg body weight respectively (AE5). The oral administration was managed by utilizing a curved ball-tipped intubation needle affixed to a 2 ml syringe. Immediately after administration the animal's behavior, toxic signs and mortality were continuously observed for the first thirty minutes and periodically at hourly intervals for during the first twenty four hours, special attention given during the first four hours, and daily thereafter for a total of 14 days<sup>18</sup>.

#### **Cage side examination**

The cage side examinations included changes in behavior pattern, gait, skin, condition of fur, tremors, convulsions, eyes-for dullness, eye-opacities, pupil diameter, ptosis, color and consistency of faeces, diarrhea, salivation and breathing abnormalities.

#### **Body weight**

The body weight of all control and treated rats was recorded on day zero (before 1st dose), day seven and day fourteen.

#### **Hematology**

The ether anesthesia was given on the day of sacrifice to all animals and blood was collected by orbital puncture into the ethylenediaminetetraacetic acid (EDTA) tubes. Right away after collection the blood was analyzed for hemoglobin (Hb), white blood cells (WBC), red blood cells (RBC), hematocrit (HCT), mean corpuscular volume (MCV), mean corpuscular hemoglobin (MCH), mean corpuscular hemoglobin concentration (MCHC) and platelets (PLT).

#### **Organ weight**

The control and treated animals were euthanized and carefully dissected for ovaries, uterine horns, liver, kidneys, suprarenal glands, spleen, heart, lungs, and brain. Each organ was cleaned of connective tissue and fat examined microscopically for any gross pathology and immediately weighed by using a sensitive electronic balance.

#### **Microscopic Anatomy**

The microscopic anatomy of ovaries, the uterine horns and liver studied by fixing the tissue in 10% buffered formalin and then processed for histological embedding. The routine histological paraffin embedding was followed. The 5  $\mu$ m thick sections of ovary, uterus (uterine horns) and liver were sectioned using a rotary microtome. The sections were stained with Haematoxylin and Eosin (H&E) stains<sup>19</sup>. The stained ovarian, uterine and liver sections were analyzed in binocular microscope using a low power objective lens 4X, 10X and a high power objective lens 40X for any alteration in cellular morphology. The photomicrographs of stained sections were used up with Digi Eye digital microscope camera.

#### **Statistical data analysis**

All the information was compiled and tabulated by using Microsoft excel worksheet. The mean, standard deviation (SD), standard error (SE) and t-test were performed by using statistical software Sigma Plot 10, to find out the significance level. The P value < 0.05 is considered as statistically significant. All the values are shown as mean  $\pm$  SE.

### **RESULTS**

#### **Preliminary phytochemicals**

The preliminary phytochemical screening of ethanolic extract of roots of Argemone mexicana revealed the presence of alkaloids, amino acids, phenolics and fatty acids. Chloroform extract revealed the presence of alkaloids, tannins, flavonoids and phytosterols (Table 1).

#### **Acute toxicity study**

The acute toxic study results of the root of Argemone mexicana showed no noticeable signs of acute toxicity and lack of death at all doses up to 5000 mg/kg body weight.

#### **Cage side observation**

The study of behavior of treated rats carried out by general inspection of each animal on a day- to- day basis from the 0 days of study to the 14th day of the study at all dose levels showed no significant changes between control and treated groups (Table 2).

#### **Body weight**

The body weight of all treated group rats was slightly diminished when compared with control, but the reduction was not statistically significant (Table 3).

**Table 1:** Phytochemical constituents of root of Argemone Mexicana

Phytochemicals	Results	
	Ethanol extract	Chloroform extract
Alkaloids	Present	Present
Carbohydrates	Absent	Absent
Steroids	Absent	Absent
Phenolics	Present	Absent
Flavonoids	Absent	Present
Amino acids	Present	Absent
Phytosterols	Absent	Present
Tannins	Absent	Present
Fatty acids	Present	Absent

**Table 2:** Cage side observation control and treated animals

Parameter	Cage side observation	
	Control	Treated
Behavior pattern	Normal	Normal
Gait	Normal	Normal
Skin	Normal	Normal
Condition of the fur	Normal	Normal
Tremors	Nil	Nil
Convulsions	Nil	Nil
Eyes-Dullness	Nil	Nil
Eyes- Opacities	Nil	Nil
Pupil diameter	Normal	Normal
Ptosis	Nil	Nil
Color & Consistency of the faeces	Normal	Normal
Diarrhea	Nil	Nil
Salivation	Normal	Normal
Breathing abnormalities	Nil	Nil

**Table 3:** Mean body weight control and treated animals in grams

Body Weight	Control	Treated	
	C (g)	AE2 (g)	AE5 (g)
0 Days	200.7 ± 1.9	200.8 ± 1.0	202.9 ± 0.9
7 <sup>th</sup> Day	214.4 ± 1.8	210.2 ± 1.4	211.3 ± 1.1
14 <sup>th</sup> Day	226.6 ± 2.4	222.0 ± 1.0	223.0 ± 0.8

The data were expressed mean ± SE, n=5. No statistical difference in body weight between control and treated. The P value is >0.05.

C-control, AE2 - Ethanolic extract of the root of Argemone mexicana 2000 mg/kg body weight and AE5 - Ethanolic extract of the root of Argemone mexicana 5000 mg/kg body weight.

**Table 4:** Mean organ weight control and treated animals in grams (g).

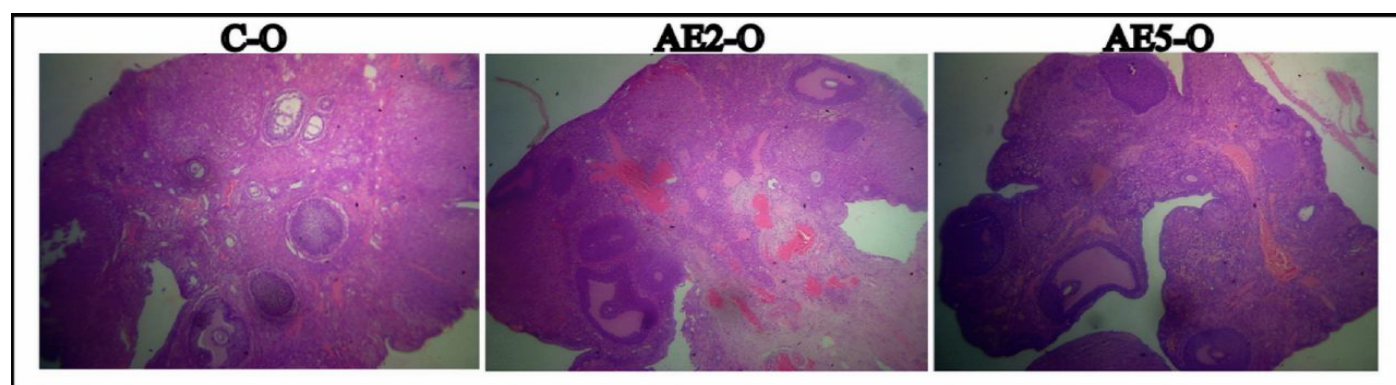
Organs	Control		Treated	
	C (g)	AE2 (g)	AE2 (g)	AE5 (g)
Ovarian *	47.4 ±0.4	47.0±0.8	47.0±0.8	49.2±1.9
Uterus	0.302 ±0.01	0.319±0.01	0.319±0.01	0.324±0.01
Spleen	0.412 ± 0.01	0.414± 0.01	0.414± 0.01	0.418± 0.02
Kidneys	1.51 ± 0.02	1.55 ± 0.07	1.55 ± 0.07	1.69 ± 0.03
Suprarenal Glands *	43.4 ± 1.9	46 ± 2.5	46 ± 2.5	45.6 ± 3.7
Liver	7.04 ± 0.2	7.14 ± 0.2	7.14 ± 0.2	7.5 ± 0.3
Heart	0.720 ± 0.01	0.718 ± 0.02	0.718 ± 0.02	0.764 ± 0.03
Lungs	1.40 ± 0.09	1.41 ± 0.05	1.41 ± 0.05	1.54 ± 0.05
Brain	1.47 ± 0.02	1.51 ± 0.02	1.51 ± 0.02	1.50 ± 0.03

All the data were expressed in g except \* in mg as mean ± SE, n=5. No statistical difference in organ weights between control and treated. The P value is >0.05. C-control, AE2 - Ethanolic extract of the root of Argemone mexicana 2000 mg/kg body weight and AE5 - Ethanolic extract of the root of Argemone mexicana 5000 mg/ kg body weight.

**Table 5:** Hematology parameters of control and treated animals

Parameter (units)	Control	Treated	
	C	AE2	AE5
H (g/dl)	12.92±0.2	13.54±0.3	13.24±0.2
WBC (10 <sup>3</sup> /μl)	11.68±0.2	12.42±0.5	12.06±0.4
RBC (10 <sup>6</sup> /μl)	8.23±0.1	8.70±0.2	8.48±0.3
HCT (%)	40.54±0.6	42.16±0.8	41.6±0.7
MCV (fL)	54.62±0.5	54.52±0.3	54.7±0.7
MCH (pg)	17.18±0.3	17.06±0.1	17.5±0.2
MCHC (g/dl)	31.82±0.3	32.16±0.1	31.9±0.1
PLT (10 <sup>3</sup> /μl)	765±5.3	785±10.6	769±5.5

The values are expressed as mean ± SE, n=5. No statistical difference in hematological parameters between control and treated. The P value is >0.05. C-control, AE2 - Ethanolic extract of the root of Argemone mexicana 2000 mg/ kg body weight and AE5 - Ethanolic extract of the root of Argemone mexicana 5000 mg/ kg body weight



**Figure 1:** Microscopic structure of ovary H&E stain.

**C-O** (Control Ovary)

**AE2-O** (Ovary of ethanolic extract of the root of Argemone mexicana 2000 mg/kg body weight)

**AE5-O** (Ovary of ethanolic extract of the root of Argemone mexicana 5000 mg/kg body weight).

### Organ weights

The organ weights between control and treated rats showed no statistical significant difference, the P value is  $>0.05$  (Table 4).

### Hematology

The blood parameter values showed slightly increased, but not a statistically significant change of HB, WBC, RBC, HCT, MCV, MCH, MCHC & PLT in the treated groups compared to the control group the P value is  $>0.05$  (Table 5).

### Microscopic Anatomy

The results of the microscopic anatomy of ovaries showed the normal histological structure of the cortex with the presence of various stages of follicle, further the medulla also showed the normal stromal tissue (Fig. 1). The histological sections of uterine horns showed normal cytoarchitecture of endometrium, myometrium and perimetrium (Fig. 2).

The liver histology was normal with hepatic lobules contain central vein and radiating hepatocytes arranged in lamellae, the portal triad was also clearly visible without any alterations (Fig. 3).

### DISCUSSION

Over a few decades medicinal value of plants has assumed an important dimension. The preliminary phytochemical screening investigations in plants, perhaps supportive in the recognition of the bioactive principles, may lead to the drug discovery and development. Further, these tests facilitate separation of pharmacologically active chemical compounds, their qualitative and quantitative estimation<sup>20</sup>.

The preliminary phytochemical screening of ethanolic extract of root of *Argemone mexicana* revealed the presence of alkaloids, amino acids, phenolics and fatty acids, these solutions do not concur with the previous study, which

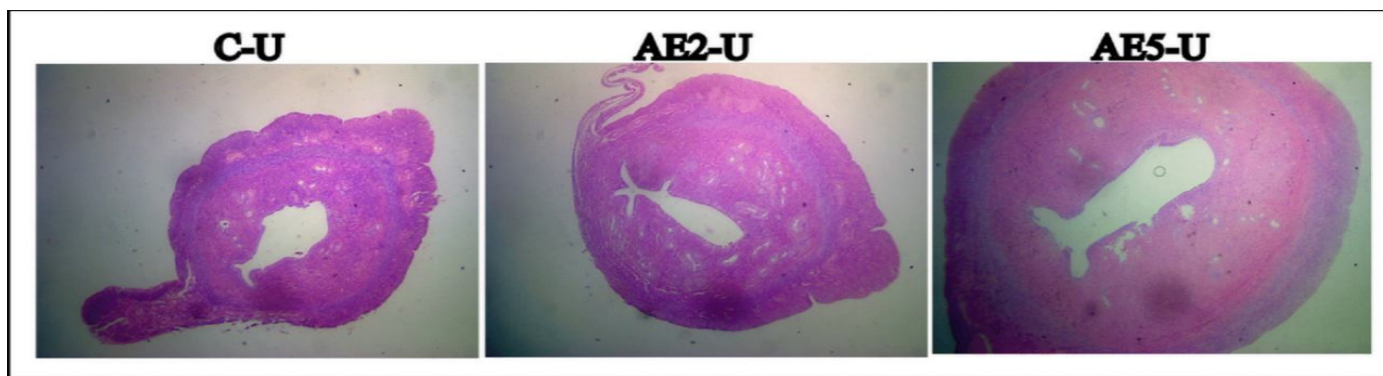


Figure 2: Microscopic structure of uterine horn H&E stain

C-U (Control Uterine horn)

AE2-U (Uterine horn of ethanolic extract of the root of *Argemone mexicana* 2000 mg/kg body weight)

AE5-U (Uterine horn of ethanolic extract of the root of *Argemone mexicana* 5000 mg/kg body weight).

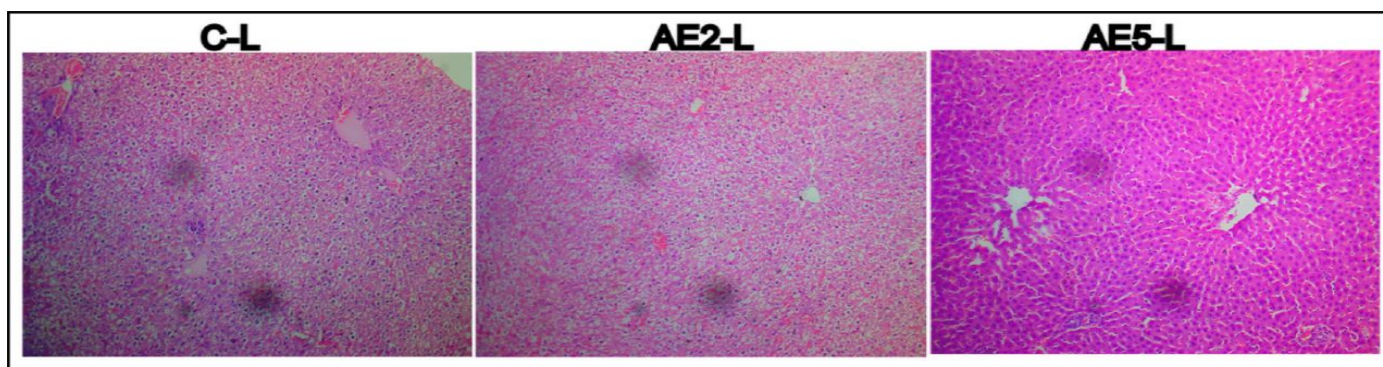


Figure 3: Microscopic structure of liver H&E stain

C-L (Control Liver)

AE2-L (Liver of ethanolic extract of the root of *Argemone mexicana* 2000 mg/kg body weight)

AE5-L (Liver of ethanolic extract of the root of *Argemone mexicana* 5000 mg/kg body weight).

describes the presence of reducing sugars, breads, carbohydrates, alkaloids, flavonoids, steroids and tannins<sup>14</sup>.<sup>15</sup>. Chloroform extract of root of *Argemone* revealed the presence of alkaloids, tannins, flavonoids and phytosterols. There were no previous reports on the phytochemicals of chloroform extract of root of *Argemone*. These outcomes suggest that the root of *Argemone mexicana* contains many secondary metabolites which are responsible for various medicinal properties and will be of great importance in phytomedicine like alkaloids which may have many pharmacological activities including analgesic, antihypertensive effects, antimalarial activity, antiarrhythmic effect and anticancer actions<sup>2</sup>. The phenolic acids may have antioxidant activity, reduces blood cholesterol, increases bile secretion, lipid levels, antimicrobial activity, anti-inflammatory, antiulcer, antispasmodic, antidepressant, cytotoxic, and antitumor activities<sup>2</sup>. The tannins may have antioxidant activity, anticancer mechanisms, decrease in the risk of cardio-vascular diseases, anti-inflammatory properties and considered as anti-nutritional factors<sup>2, 21</sup>. The flavonoids present in the root of *Argemone* may have antioxidant, antibacterial, hepatoprotective, anti-inflammatory, antiviral, anticancer activities, free radical scavenging capacity, coronary heart disease prevention, oestrogenic activity, anti-allergic<sup>2, 22</sup>. The presence of sterols has pharmacological activity like lowering blood cholesterol and anti-inflammatory<sup>23</sup>.

The oral acute toxic study results indicated no significant alterations in final body weight, organ weights, blood parameters and microscopic anatomy of ovaries, the uterine horns and liver of rats treated with ethanolic extract of root of *Argemone mexicana* in comparison with the mastery group. Further, during the study period of 14 days there were no noticeable signs of acute toxicity. Lack of death at all doses showed that the LD50 of ethanolic extract of root of *Argemone mexicana* is greater than 5000 mg/kg body weight. On that point are no late accounts in literature on acute toxicity studies of the root of *Argemone mexicana*.

## CONCLUSIONS

We resolve that the consequence of the present study may add to the scientific literature with respect to the phytochemical composition of the chloroform extract of *Argemone mexicana* as there is no data available in the

literature. Further, the consequences of the acute toxicity study revealed that ethanolic extract of root of *Argemone mexicana* was found to be nontoxic up to 5000 mg/kg body weight, so the LD50 of ethanolic extract of root of *Argemone mexicana* is greater than 5000 mg/kg body weight. This is likewise an important determination as the reports on the root extract are lacking. Therefore the present study offers a satisfactory preclinical proof of safety of root of *Argemone mexicana* in toto including maintenance of cellular architecture.

## REFERENCES

1. WHO. Traditional Medicine Strategy 2002-2005. Geneva, 2002.
2. Mamta Saxena, Jyoti Saxena, Rajeev Nema, Dharmendra Singh, Abhishek Gupta. (2013). Phytochemistry of medicinal plants. J Pharmacogn Phytochem. 1: 168-182.
3. Shirish S. Pingale. (2013). Toxicity study for *Argemone mexicana* L. World J Pharm Sci. 1: 151-155.
4. Ugbabe GE, Ezeunala MN, Edmond IN, Apev J, Salawu OA. (2010). Preliminary phytochemical, antimicrobial and acute toxicity studies of the stem bark and the leaves of a cultivated *Syzygium cumini* Linn. (Family: Myrtaceae) in Nigeria. Afr J Biotechnol. 9: 6943-6947.
5. Glauco Morales, Adrian Paredes, Alberto Olivares and Jaime Bravo. (2014). Acute oral toxicity and anti-inflammatory activity of hydroalcoholic extract from *Lampaya medicinalis* Phil in rats. Biological Research. 47: 6.
6. Narviya MB, Parmar P, Shukla VJ, Ravishankar B. (2011). Toxicological study of *Balakaturbhandrika churna*. J Ayurveda Integr Med. 2: 79-84.
7. Rashid Ali, Raisuddin Ali, Abhinav Jaimini, Dhruv Kumar Nishad, Gaurav Mittal, Om Prakash Chaurasia, et al. (2012). Acute and sub acute toxicity and efficacy studies of *Hippophae rhamnoides* based herbal antioxidant supplement. Indian J Pharmacol. 44: 504-508.
8. Goutam Brahmachari, Dilip Gorai, Rajiv Roy. (2013). *Argemone mexicana*: chemical and pharmacological aspects. Rev Bras Farmacogn Braz J Pharmacogn. 23: 559-575.
9. Charles Lekhya Priya, Kokati Venkata Bhaskara Rao. (2012). Ethanobotanical and current ethanopharmacological aspects of *Argemone mexicana* Linn: An overview. Int J Pharm Sci Res. 3: 2143-2148.
10. Saurabh Rajvaidhya, B.P. Nagori, G.K. Singh, B.K. Dubey, Prashant Desai, Sanjay Jain. (2012). A review on *Argemone mexicana* Linn. An Indian medicinal plant. Int J Pharm Sci Res. 3: 2494-2501.
11. M. S. Saranya, T. Arun, P. Iyappan. (2012). In vitro antibacterial activity and preliminary phytochemical

- analysis of leaf extracts of *Argemone mexicana* Linn – a medicinal plant. *Int J Curr Pharm Res.* 4: 85-87.
12. N.R. Dey, K.C. Das, Yogender Rai. (2008). *Argemone mexicana*. A multicentric double blind Homeopathic pathogenetic trial (Drug Proving) carried out by CCRH. *Indian J Res Homeopathy.* 2: 13-18.
  13. Rekha Sharanappa, Vidyasagar G.M. (2014). Plant profile, phytochemistry and pharmacology of *Argemone mexicana* Linn. A review. *Int J Pharm Pharm Sci.* 6: 45-53.
  14. Selvaraj Varun, Sudha Sellappa. (2014). In vitro screening of phytochemicals and anticancer activity of *Argemone mexicana* leaf extract. *World J Pharm Res.* 3: 547-556.
  15. Perumal P, Sekar V, Rajesh V, Gandhimathi S, Sampathkumar R, Shuja Nazimudin K.H. (2010). In vitro antioxidant activity of *Argemone mexicana* roots. *Int J PharmTech Res.* 2: 1477-1482.
  16. Prashant Tiwari, Bimlesh Kumar, Mandeep Kaur, Gurpreet Kaur, Harleen Kaur. (2011). Phytochemical screening and extraction: A review. *Int Pharm Sci.* 1: 98-106.
  17. Palanisamy P, Jayakar B, Kumuthavalli MV, Yoganath Kumar, Srinath KR. (2012). Preliminary phytochemical evaluation of whole plant extracts of *Dipteracanthus prostratus* nees. *Int Res J Pharm.* 3: 150-153.
  18. OECD/ OCDE, OECD Guideline for testing of chemicals, acute oral toxicity- Acute toxicity class method, 423. Adopted 17th December, 2001.
  19. H.M Carleton's. *Histological technique.* 5th Ed. USA: Oxford University Press; November 6, 1980.
  20. Satheesh Kumar Bhandary , Suchetha Kumari N. , Vadisha S. Bhat, Sharmila K.P., Mahesh Prasad Bekal. (2012). Preliminary phytochemical screening of various extracts of *Punica granatum* peel, whole fruit and seeds. *Nitte University Journal of Health Science.* 2: 34-38.
  21. T. Ozcan, A. Akpınar-Bayazit, L. Yilmaz-Ersan, B. Delikanli. (2014). Phenolics in Human Health. *Int J Chem Eng Appl.* 5: 393-396.
  22. Shashank Kumar and Abhay K. Pandey. (2013). Chemistry and Biological activities of flavonoids: An overview. *Scientific World J.* 2013; doi:10.1155/2013/162750.
  23. Abhishek Kumar Sah, Vinod K. Verma. (2011). *Syzygium cumini*: An overview. *J Chem Pharm Res.* 3: 108-113.