



---

## Research Article

---

### PREVALENCE OF HAEMOPROTOZOA OF ANAS PLATYRHYNCHOS IN BAGHDAD CITY

Arkan Noori Jwad AL-Zurfi\*, Haider M.A.AL-Rubaie

Department of Parasitology, college of Veterinary Medicine, University of Baghdad, Iraq.

\*Corresponding Author: Email: [firmas\\_rashad@yahoo.com](mailto:firmas_rashad@yahoo.com)

(Received: October 05, 2015; Accepted: November 05, 2015)

#### ABSTRACT

This study was conducted to investigate the prevalence of haemoprotozoa among *Anas platyrhynchos* in Baghdad city/Iraq. A total of 60 mallards (*Anas platyrhynchos*) of both sexes (males and females) with body weight ranges from (1-1.6kg) purchased from local markets of Baghdad city were divided into 4 groups (15birds in each month) during a period from 1- December2014 to 31- March 2015. Two types of protozoa were detected: *Plasmodium relictum* and *Leucocytozoon simondi*. The prevalence of the mentioned types was 46.66% (28/60) and 16.66% (10/60) respectively.

Results revealed that there was no significant difference among infection rates due to month and sex of bird. The infection rate of *Plasmodium relictum* ranged from 33.33% in January to 66.66% in March. On the other hand, the infection rate of *Leucocytozoon simondi* ranged from 6.66% in December to (33.33%) in March.

**Keywords:** Haemoprotozoa, *Anas platyrhynchos*, *Leucocytozoon simondi*, *Plasmodium relictum*.

#### INTRODUCTION

The mallard (*Anas platyrhynchos*) is a dabbling duck belonging to the surface-feeding ducks tribe, which is common in Europe, North America and Asia (Nowak et al., 2011). It is usually found in the coasts of the North Sea and the Baltic Sea, although this bird can also reach the Mediterranean sea and the Black sea (Tomiałojć and Stawarczyk, 2003 and Okarma and Tomek, 2008). It resides on sheltered banks of fresh water reservoirs and more common in built-up areas (Tomiałojć and Stawarczyk, 2003), especially in large cities. Its diet is dominated by plants and occasionally feeds on land and aquatic invertebrates (Sikora et al., 2007).

Parasitic diseases come first among other disease that cause reduction in productivity of rural poultry (Adejinmi and Oke, 2011). Haemosporidians (Sporozoa: Haemosporida) are a group of endoparasitic protists that inhabit a broad range of host species of amphibians, reptiles, birds and mammals and use blood-sucking dipteran insects as vectors. These

protozoans are worldwide distributed and spread through a wide range of habitats and geographical regions. There are three main genera of haemosporidians that infect birds: *Plasmodium*, which is the causal agent of true avian malaria, and *Haemoproteus* and *Leucocytozoon*, which cause other related haemosporidiosis. Based on morphological variation, about 175 species have been described so far within the genera *Plasmodium* and *Haemoproteus*. These parasites have been recorded in about 68 per cent of the avian species that have been examined and infect almost every order of birds, (Valki nas, 2005). Intense interest in hematozoa of the anatidae was first kindled when heavy mortality of ducks was initially recorded (Wickware, 1915). Avian haematozoa, especially haemosporidia, including species of *Haemoproteus*, *Leucocytozoon* and *Plasmodium* are transmitted by blood-sucking dipteran insects (Krizanauskiene et al., 2006), these parasites occur worldwide, irrespective of climatic barriers (Wiersch et al., 2007). In the infected birds, the clinical disease is associated

with fever, depression, anorexia, loss of body weight, dyspnea, hepatomegaly, splenomegaly, ocular haemorrhage, haemolytic anaemia, (Aiello, 1998 and William, 2005). Mortality in bird due the disease may be up to 90 % (Jordan and Pattison, 1998). Severe infections by haemosporidian can lead to death and involves different physiopathological phenomena such as anemia, thrombocytopenia and inflammation (Cannell et al., 2013). Avian haemosporidiosis can be severe or even lethal for domestic birds and for birds in zoos (Ferrell et al., 2007). At the population level, haemoparasites can affect their hosts by reducing fitness parameters such as body condition, reproductive success and survival (Stjernman et al., 2004).

#### MATERIALS AND METHODS

A total of 60 mallards (*Anas platyrhynchos*) of both sexes (males and females) with body weight ranges from (1-1.6kg) purchased from local markets of Baghdad city were divided into 4 groups (15birds in each month) during a period from 1- December2014 to 31- March 2015 at the laboratory of Parasitological Department / Veterinary Medicine College /Baghdad University. The birds were slaughtered. A thin blood smears were made immediately from each bird, air dried, fixed in absolute methyl alcohol, and stained with Giemsa stain at strength 1:10 at pH 7.2 for one hour wash with tape water and then air dried (Cable, 1957). Then, the slides were examined under the microscope at a higher magnification (100X) for the detection and of blood

Protozoa (Soulsby, 1982; Levine, 1985, and Springer, 1997).

#### RESULTS

##### 1. The Prevalence of blood protozoa

Results showed that the prevalence of *Plasmodium relictum* and *Leucocytozoon simondi* in *Anas platyrhynchos* was 46.66% (28/60) and 16.66%(10/60) respectively (Table ,1 and Figures 1,2).

##### 2. Infection rate of blood protozoa according to the months

Results revealed that the differences in infection rate of blood protozoa due to months were not significant (Chi-square= 3.75, P=0.28) in *Plasmodium relictum* and in *Leucocytozoon simondi* (Chi-square= 4.32, P=0.22) (Table 1). The infection rates of *Plasmodium relictum* in December, January, February and March were 40.00, 33.33, 46.66, and 66.66% respectively. The corresponding infection rates of *Leucocytozoon simondi* were 6.66, 13.33, 13.33 and 33.33% respectively.

##### 3. Infection rate of blood protozoa according to the sex

Table 2 illustrate the infection rates of *Plasmodium relictum* and *Leucocytozoon simondi*. Statistical analysis showed that the differences of infection rate between males and females were not significant for the two types of protozoa. 16.66% (10/60) was recorded in Males (47.82% and 21.73%) and females (45.94% and 13.51%) (Table: 2).

**Table (1):** The prevalence of blood protozoa of *Anas platyrhynchos domestics*.

Months	No. of examined birds	No. of infected bird with <i>Plasmodium relictum</i> (%)	No. of infected birds with <i>Leucocytozoon simondi</i> (%)
December	15	6(40)	1(6.66)
January	15	5(33.33)	2(13.33)
February	15	7(46.66)	2(13.33)
March	15	10(66.66)	5(33.33)
Total	60	28 (46.66)	10(16.66)

**Table (2):** Infection rates of blood protozoa of *Anas platyrhynchos domestics* according to sex.

Sex	No. of examined birds	No. of infected birds <i>Plasmodium relictum</i> (%)	No. of infected birds <i>Leucocytozoon simondi</i> (%)
Males	23	11 (47.82)	5 (21.73)
Females	37	17 (45.94)	5 (13.51)
Total	60	28 (46.66)	10 (16.66)

\*P ≥0.05

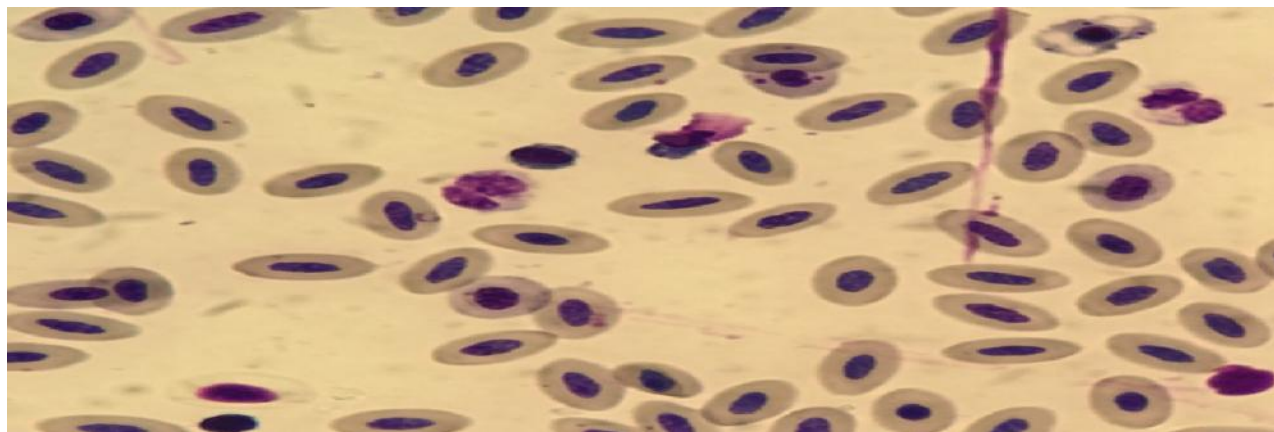


Figure (1): Plasmodium relictum in the red blood cells (Red Arrow ).

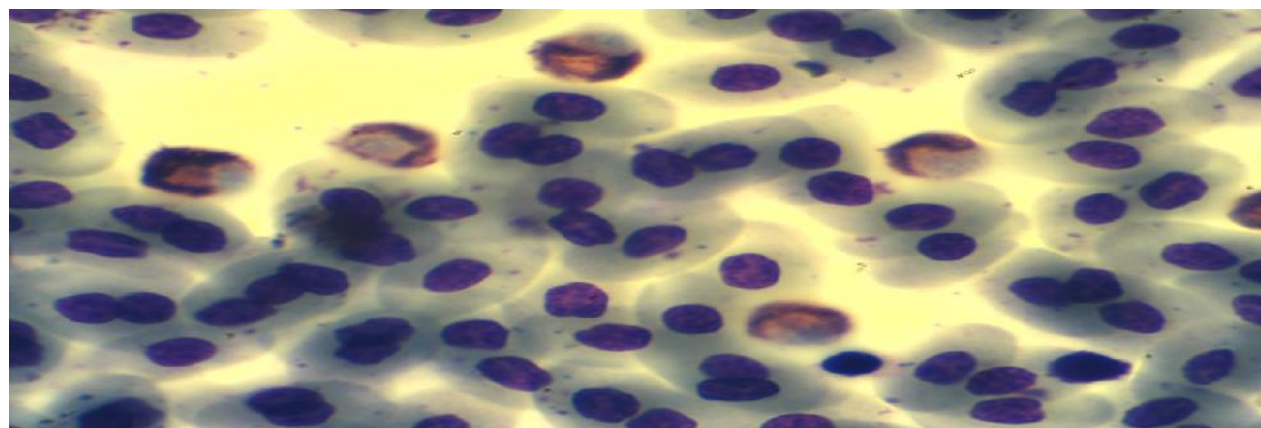


Figure (2): Leucocytozoon simondi in the white blood cells (Red Arrows)

## DISCUSSION

Leucocytozoon is transmitted from one definitive host to the next by certain species of black flies of the family Simuliidae. While not all species of blackflies are natural vectors, numerous species of the Simuliidae have been implicated as probable vectors (O'Roke, 1934; Shewell, 1955; Fallis et al., 1956; and Tarshis, 1965), and can infect 100% of mallards and black ducks in some populations in northeastern North America (Trainer et al., 1962 and Bennett et al., 1974, 1975, 1991). In contrast, Leucocytozoon is rarely re-reported from central North America (Burgess, 1957). Differences in Leucocytozoon prevalence arise because, in the latter area, black fly vectors have less swift water breeding habitat and are often insufficiently numerous to spread the parasite (Herman, 1968). Chernin (1956b), which showed that the seasonal increase in parasitemia, or spring relapse, in *L. simondi* coincides with egg-laying in ducks O'Roke (1931, 1934) found high

prevalences of *L. simondi* (up to 100%) in wild black ducks (*Anas rubripes*) and mallards (*Anas platyrhynchos*) from Douglas Lake and stated that brood sizes were noticeably reduced by *L. simondi*-caused mortality. O'Roke (1934) and Chernin (1956a) found prevalences near 100% in farm-raised Pekin ducks (*Anas platyrhynchos*) from the University of Michigan Biological Station (UMBS) area. The prevalence rates of Plasmodium sp. infections of birds were 27 % in Ghana (Poulsen et al., 2000), 15 % in Zimbabwe (Permin et al., 2002) and 29.5 % in Malawi, The incidence rate of avian malaria infections of seabirds was 87.3 % in Cape Recife, South Africa (Schultz and Whittington, 2005). In Brazil, some studies have investigated the occurrence of parasitism by Plasmodium spp. and Haemoproteus spp. in wild birds in areas with different ecological characteristics and very different conservation (Lacorte et al., 2013, Silveira et al., 2013, Vanstreels et al., 2014). Host-parasite interactions can be locally influenced by abiotic factors such

as climate, season or habitat type, and by biotic effects such as host age or sex (Sol et al., 2003), causing each parasite's prevalence to vary throughout its distribution range. Local changes in the equilibrium of this system, such as climate changes or the introduction of new species, may originate the risk of disease outbreak (Atkinson and van Riper III 1991). Haemosporidian transmission to avian hosts may occur either in discrete seasons or throughout the year, depending on climate, region, parasite life cycle and vector distribution (Waldenström et al., 2002). Some haemosporidians can switch hosts between resident and migrant populations of a single bird species or between different species, sometimes even from different families (Hellgren et al., 2009). The environmental characteristics of each habitat influence vector abundance, which affects transmission and prevalence of parasites (Sol et al., 2000). One of the prominent features of avian malaria is a wide variation among host species in parasite prevalence – that is, in the proportion of individuals infected with haematozoa in a population. Among other factors, prevalence is affected by the immunological capacity of the host to either prevent parasite infection or to clear established infections (Atkinson and van Riper III 1991). Environmental factors play a considerable role in the evolution of Plasmodium and the transmission of malaria (Hume et al., 2003). Shamsuddin and Mohammad (1980) were the first to report on haematozoa of some Iraqi birds. They examined 37 birds species recording 5 species of Haemoproteus, 1 of Plasmodium and records of microfilariae from 6 passerine hosts. Then Mohammad (1990) examined 15 species of them recording 6 species of Haemoproteus, 2 of Leucocytozoon, and records of Trypanosoma and microfilariae from 2 and 4 birds hosts respectively. Recent studies have reported a positive association between avian malaria prevalence and increasing temperatures, thereby potentially widening the distribution of avian malaria (via their vectors) to higher elevations (Freed et al., 2005; Sehgal, 2010; Imura et al., 2012).

#### REFERENCES

- Adejimi, J.O.P. and Oke, M. (2011). Gastro-intestinal parasites of domestic ducks (*Anas platyrhynchos*). *Asian J. Poult. Sci.* 5(1):46-50.
- Aiello, S. E. (1998). *The Merck Veterinary Manual*. 8th ed. National Publishing, Philadelphia.
- Atkinson, C.T, van Riper, III C., (1991). Pathogenicity and epizootiology of avian hematozoa: Plasmodium, Leucocytozoon and Haemoproteus. In: Loye J, Zuk M (eds) *Bird-parasite interactions: ecology, evolution, and behavior*. Oxford University Press, New York : 19-48.
- Bennett, G. F, Smith, A. D., Whitman, W., and Cameron, M. (1975). Hematozoa of the Anatidae of the Atlantic flyway. II. The Maritime provinces of Canada. *J. Wildl. Dis.*, 11:280-289.
- Bennett, G. F, Stotts, V. D., and Bateman, M. C. (1991). Blood parasites of black ducks and other anatids from Labrador and insular Newfoundland. *Can. J. Zool.*, 69:1405-1407.
- Bennett, G. F, W., Blandin, H., Heusmann, W., and Campbell, A. G. (1974). Hematozoa of the Anatidae of the Atlantic Flyway. 1. Massachusetts. *J. Wildl. Dis.* 10:442-451.
- Bennett, G.F. and Campbell, A.G. (1972). Avian haemoproteidae. I. Description of *Haemoproteus fallisi* n. sp. and a review of the haemoproteids of the family Turdidae. *Can. J. Zool.*, 50: 1269-1275.
- Burgess, G. D. (1957). Occurrence of *Leucocytozoon simondi* Mathis and Leger in wild water-fowl in Saskatchewan and Manitoba. *J. Wildl. Manage.*, 21:99-100.
- Cable, R.M. (1957). *An Illustrated Laboratory Manual of Parasitology*. 4th ed., Burges Publishing Co., Minneapolis 15, Minnesota, USA: 114-115.
- Cannell B.L., Krasnec K.V., Campbell K., Jones H.I., Miller R.D. and Stephens, N. (2013). The pathology and pathogenicity of a novel *Haemoproteus* spp. infection in wild Little Penguins (*Eudyptula minor*). *Vet. Parasitol.* 197:74-84.
- Chernin, E. (1956b). The relapse phenomenon in the *Leucocytozoon simondi* infection of the domestic duck. *The American Journal of Hygiene* 56: 101– 118.
- Chernin, E. (1956a). The epizootiology of *Leucocytozoon simondi* infections in domestic ducks in northern Michigan. *The American Journal of Hygiene* 56: 39–57.
- Fallis, A. M., Anderson, R. C., and Bennett, G. F. (1956). Further observations on the transmission and development of *Leucocytozoon simondi*. *Can. J. Zool.* 34:389-404.
- Freed, L.A; Cann, R.L.; Goff, M.L.; Kuntz, W.A and Bodner, G.R. (2005). Increase in avian malaria at upper elevation in Hawai'i. *The Condor*, 107: 753–764.
- Ferrell, S.T.; Snowden, K.; Marlar, A.B.; Garner, M.; Lung, N.P. (2007). Fatal hemoprotozoal infections in multiple avian species in a Zoological Park. *J Zoo Wildl Med* 38 (2):309-316.
- Hellgren O, Pérez-Tris J, Bensch, S. (2009). A jack-of-all-trades and still a master of some: prevalence and host range in avian malaria and related blood parasites. *Ecology* 90 (10):2840-2849.

17. Herman, C. M. (1968). Blood parasites of North American waterfowl. *Trans. North Am. Wildl. Nat. Resour. Conf.*, 33:348-359.
18. Hume, J.C.; Lyons, E.J.; Day, K.P. (2003). "Human migration, mosquitoes and the evolution of *Plasmodium falciparum*". *Trends Parasitol* 19 (3): 144–149.
19. Imura, T., Suzuki, Y., Ejiri, H., Sato, Y., Ishida, K., Sumiyama, D., Murata, K. and Yukawa, M. (2012). Prevalence of avian haematozoa in wild birds in a high-altitude forest in Japan. *Veterinary Parasitology*, 183(3–4): 244–248.
20. Jordan, F. T. W. and Pattison, M. (1998). *Poultry Diseases*. 4th Edition, WB Saunders, London.
21. Krizanauskiene, A., Hellgren, O. Kosarevt, V., Sokolov, L., Bensch, S. and Valkiunas, G. (2006). Variation in host specificity between species of avian hemosporidian parasites: evidence from parasite morphology and cytochrome B gene sequences. *J. Parasitol.*, 92(6): 1319-1324.
22. Lacorte, G.A., Félix, G.M.F., Pinheiro, R.R.B., Chaves, A.V., Almeida-Neto, G., (2013). Leucocytozoon simondi infection of the domestic duck. *The American Journal of Hygiene* 56: 101– 118.
23. Levine, N.D. (1985). Entestinal cryptosporidiosis in pigeon (*Columba livia*). *veterinary protozoology*. Iowa State Univ. press Ames, 1st .ed pp. 365- 367. *Avian Dis.* 41:748-750.
24. Mohammad, M.K. (1990). Blood parasites of some Iraqi wild birds. *Iraqi J. Sci.*, 31 (Supplement):31-39.
25. Nowak, M.; Kavetska, K.; Królaczyk, K.; Stapf, A.; Kornaś, S.; Wajdzik, M. and Basiaga, M. (2011). Comparative study of cestode of geese. *North Am. Veterinarian* 7 : 47–48.
26. Okarma, H., Tomek A., (2008). *Łowiectwo [Hunting]*. Wydaw. Edukacyjno-Narodowe H20, Kraków [in Polish]. Outbreak of Avian Malaria Associated to Multiple Species of *Plasmodium* in Magellanic Penguins Undergoing Rehabilitation in Southern Brazil. *PLoS One* 9:e94994. parasite *Plasmodium tejerai* in South American penguins. *Parasitol. Int.* 41:748-750.
27. O'roke, E. C. (1931). A destructive waterfowl parasite. *Transactions of the American Game Conference* 18: 248–251.
28. O'roke, E. C. (1934). A malaria-like disease of ducks caused by *Leucocytozoon anatis* Wickware. *University of Michigan School of Forestry and Conservation Bulletin No. 4.*, University of Michigan, Ann Arbor, Michigan, 44 pp.
29. Permim, A., Esmann, J. B., Hoj, C. H., Hove, T. and Mukaratkirwa, S. (2002). Ecto-, endo- and haemoparasites in free-range chickens in Goromonzi District in Zimbabwe. *Preventive Veterinary Medicine*, 54: 213 – 224.
30. Poulsen, J., Permin, A., Hindsho, O., Yelifari, L., Nansen, P. and Bloch, P. (2000). Prevalence and distribution of gastro-intestinal helminths and haemoparasites in young scavenging chickens in upper eastern region of Ghana, West Africa. *Preventive Veterinary Medicine*, 45: 237 – 245.
31. Schultz, A. and Whittington, P. (2005). High prevalence of avian malaria infection to avifauna at Cape Recife, Eastern Cape, South Africa. *Ostrich*, 76: 56 - 60.
32. Sehgal, R.N.M. (2010). Deforestation and avian infectious diseases. *The Journal of Experimental Biology*, 213: 955–960.
33. Shamsuddin, M. and Mohammad, M.K. (1980). Haematozoa of some Iraq birds with description of two new species, *Haemoproteus pterocles* and *Leucocytozoon nycticoraxi* (Protozoa: Haemosporina). *Bull. Nat. Hist. Res. Centre*, 7(4): 111-154.
34. Shewell, G. E. (1955). Identity of the black fly that attacks ducklings and goslings in Canada (Dip-tera: Simuliidae). *Can. Entomol.* 87:345-349.
35. Shewell, G. E. (1955). Identity of the black fly that attacks ducklings and goslings in Canada (Dip-tera: Simuliidae). *Can. Entomol.* 87:345-349.
36. Sikora, A., Rohde, Z., Gromadzki, M., Neubauer, G., Chylarecki, P., (2007). *Atlas rozmieszczenia ptaków lęgowych Polski 1985–2004 [The Atlas of breedingbirds in Poland 1985–2004]*. Bogucki Wydaw. Nauk., Poznań [in Polish].
37. Silveira, P., Belo, N.O., Lacorte, G.A., Kolesnikovas, C.K.M., Vanstreels, R.E.T., (2013). L. simondi infections in domestic ducks in northern Michigan. *The Am. J. Hyg.*, 56: 39–57.
38. Sol, D., Jovani, R., Torres, J. (2000). Geographical variation in blood parasites in feral pigeons: the role of vectors. *Ecography* 23 (3):307-314.
39. Sol, D., Jovani, R., Torres, J. (2003). Parasite mediated mortality and host immune response explain age-related differences in blood parasitism in birds. *Oecologia* 135 (4):542-547.
40. Soulsby, E.J.L. (1982). *Helminths, Arthropods and Protozoa of Domesticated Animals*. 7th edn., Baillire Tindall : 35-740.
41. Springer, W.T (1997). Other blood and tissue protozoa. In: *Diseases of Poultry*. 10th edn., Calnek BW, Barnes HJ, Beard HJ, McDougald LR and Saif YM (eds). Iowa State University Press, USA. pp. 900-911.
42. Stjernman, M., Raberg, L., Nilsson, J.A. (2004). Survival costs of reproduction in the blue tit (*Parus caeruleus*): a role for blood parasites? *Proc R Soc B* 271 (1555):2387-2394.
43. Tomiałojć, L., Stawarczyk, T., (2003). *Awifauna Polski. Rozmieszczenie, liczebność i zmiany [Avifauna of Poland. Distribution, abundance and changes]*. *Pro Natura*, Wrocław [in Polish].
44. Tarshis, I. B., and C. M. Herman. 1965. Is *Cnephia invenusta* (Walker) a possible important vector of *Leucocytozoon* in Canada geese? *Bull. Wildl. Dis. Assoc.* 1:10-11.

45. Trainer, D. O., Schildt, C. S., Hunt, R. A., and Jahn, L. R.. (1962). Prevalence of *Leucocytozoon simondi* among some Wisco. \
46. Valki nas, G. (2005). Avian malaria parasites and other haemosporidia. CRC Press, Boca Raton, Florida:946.
47. Vanstreels, R.E.T., Kolesnikovas, C.K.M., Sandri, S., Silveira, P., Belo, N.O., Waldenström, J., Bensch, S., Kiboi, S., Hasselquist, D., Ottosson, U. (2014). Cross-species infection of blood parasites between resident and migratory songbirds in Africa. *Mol Ecol* 11 (8):1545-1554.
48. Wickware,A.B.(1915).is *Leucocytozoon anatis* the cause of a new disease in ducks? *Parasite*.8: 17-21.
49. Wiersch, S.C., Lubjuhn T., Maier, W.A. and Kampen, H. (2007). Haemosporidian infection in passerine birds from Lower Saxony. *J Ornithol*, 148: 17–24.
50. William, R. B. (2005). Avian malaria: clinical and chemical pathology of *Plasmodium gallinaceum* in the domestic fowl, *Gallusgallus*. *Avian Patholo* ., 34: 29 – 47.
51. Waldenström, J.; Bensch, S.; Kiboi ,S.; Hasselquist, D.; Ottosson, U. (2002). Cross-species infection of blood parasites between resident and migratory songbirds in Africa. *Mol Ecol* 11 (8):1545-1554.