

Primary Hyperlipidemia, Acute Pancreatitis and ketoacidosis in an Adolescent with Type 2 Diabetes

Krisztina Lukacs^{1,2}, Laszlo Jozsef Barkai¹, Eva Palik¹, Attila J Szabo², Laszlo Madacsy² and Nora Hosszufalusi¹

¹3rd Department of Medicine, Semmelweis University, 1125 Budapest, Hungary

²1st Department of Pediatrics, Semmelweis University, 1083 Budapest, Hungary

Abstract

A case is presented of a 15-year-old boy with a past medical history of hyperlipidemia and hypertension. He attended the emergency department with a 3-day history of vomiting, acute abdominal pain, and altered mental status. Laboratory data on admission revealed metabolic acidosis (pH: 7.12, BE: -20.8 mmol/L), high blood glucose level (32.1 mmol/L) and significant hyperlipidemia (cholesterol: 16.3 mmol/L, triglycerides: 21.1 mmol/L). Treatment with electrolytes and volume replacement and intravenous insulin successfully resolved the ketoacidosis, but the abdominal pain and hyperlipidemia remained. Abdominal US and CT scan showed severe necrotizing pancreatitis with a pseudocyst. The laboratory studies showed a Frederickson type V pattern hyperlipidemia. HbA_{1c} was 14.3% (133 mmol/mol), indicating the presence of chronic glucose elevation. Based on the lack of islet cell antibodies and the normal fasting serum C-peptide level, type 2 diabetes was diagnosed. His HLA DQB1 genotype is associated with neutral autoimmune diabetes risk. The rare and enigmatic triad of diabetic ketoacidosis, hyperlipidemia and acute pancreatitis has been reported in a few adult and childhood cases. The pathomechanism is not clear and the association among the members of the triad may have four different explanations. All previous reports in children, suggest that ketoacidosis occurring in type 1 diabetes as first symptom can cause hyperlipidemia, and consequent acute pancreatitis. However, to the best of our knowledge, this is the first report of a pediatric patient presenting with primary hyperlipidemia-induced acute necrotizing pancreatitis complicated by diabetic ketoacidosis at the onset of non-autoimmune diabetes.

Keywords: Acute pancreatitis; Childhood; Diabetic ketoacidosis; Primary hyperlipidemia; Type 2 diabetes

Introduction

The triad of diabetic ketoacidosis (DKA), hyperlipidemia (HL) and acute pancreatitis (AP) is a rare association of metabolic disorders. The pathomechanism is not fully understood; the discussion of previous reported cases resulted in many different hypotheses explaining the most likely sequence of events [1]. All previous reports on children suggest that DKA occurring in type 1 diabetes (T1D) as a “first” symptom can cause HL and consequent AP [2-6]. Here, we report another sequence of events for the first time in an adolescent, where hyperlipidemia preceded the onset of diabetic ketoacidosis and led to an acute necrotizing pancreatitis which provoked DKA as the first manifestation of type 2 diabetes (T2D). However, DKA might have made worse the hyperlipidemia and the course of acute pancreatitis in our patient.

Case Report

A 15-year-old boy was admitted to the pediatric emergency department with a 3-day history of vomiting, acute abdominal pain and somnolent mental status. Two years previously he had been diagnosed with hyperlipidemia and hypertension, but had not received any pharmaceutical treatment. During the previous year he complained of repeated episodes of abdominal pain, but he did not visit the family doctor. The family history was notable for obesity and hyperlipidemia in both parents without the presence of diabetes.

On admission, we found a disoriented, dehydrated patient with Kussmaul breathing and acetone smell. Blood pressure was 150/70 mmHg, regular pulses 120/min, tachypnea of 35/min and body temperature 37.4°C. The patient was 194.5 cm tall (+2.58 SDS) and 99.2 kg (+2.66 SDS), body mass index 27.81 kg/m² (+2.08 SDS). He

had acanthosis nigricans in the armpits and no eruptive xanthomas. Periumbilical tenderness with mild involuntary guarding was noted.

The initial laboratory values (Table 1), showed severe metabolic acidosis (arterial pH: 7.12), elevated glucose (32.1 mmol/L), HbA_{1c} (14.3%), lipase (532 U/L), WBC count (24.1 G/L), C-reactive protein (424 mg/L), decreased sodium (118 mmol/L) and potassium (3.1 mmol/L), and normal amylase (36 U/L) levels in the plasma. Serum was milky and turbid with triglycerides 21.1 mmol/L and cholesterol 16.3 mmol/L. Besides the loss of sodium due to DKA, pseudohyponatremia caused by hyperlipidemia and hyperglycemia was also suspected on the background of the low plasma sodium level.

Treatment was started with 20 ml/kg/h 0.9% saline and 0.1 IU/kg/h intravenous insulin infusion. Despite the acid-base balance, blood glucose, and mental status became normalized within 24 hours, the patient's epigastric pain increased. Abdominal ultrasound and computed tomography scan showed acute necrotizing pancreatitis with a cystic-necrotic lesion (112×36×70 mm) in the corpus and tail of the pancreas (Figure 1). The clinical and radiological picture suggested acute necrotizing pancreatitis of Grade E Balthazar CT severity index; and the Ranson's score was 6 with 40% predicted mortality.

***Corresponding author:** Krisztina Lukacs, 3rd Department of Internal Medicine, Semmelweis University, 4 Kutvolgyi Street, 1125 Budapest, Hungary, Tel: (36)-20-825-9048; Fax: (36)-1-395-8857; E-mail: krisztinalukacs@hotmail.com

Received February 01, 2016; **Accepted** February 23, 2016; **Published** February 28, 2016

Citation: Lukacs K, Barkai LJ, Palik E, Szabo AJ, Madacsy L, et al. (2016) Primary Hyperlipidemia, Acute Pancreatitis and ketoacidosis in an Adolescent with Type 2 Diabetes. J Diabetes Metab 7: 651. doi:10.4172/2155-6156.1000651

Copyright: © 2016 Lukacs K, et al. This is an open-access article distributed under the terms of the Creative Commons Attribution License, which permits unrestricted use, distribution, and reproduction in any medium, provided the original author and source are credited.

Parameters	Initial	After 24 hours	After 72 hours	3 rd month
Total cholesterol	16.3	12.4	10.1	4.1
HDL-cholesterol	0.9	0.7	0.9	1.3
LDL-cholesterol	5.7	3.1	1.2	2.1
Triglycerides	21.1	18.7	17.3	1.5
Glucose	32.1	16.3	11.2	8.9
HbA _{1c}	14.3	-	-	7.7
Amylase	36	125	62	65
Lipase	532	685	418	135
pH	7.12	7.26	7.41	-

Total cholesterol (mmol/L), HDL-cholesterol (mmol/L), LDL-cholesterol (mmol/L), Triglycerides (mmol/L), Glucose (mmol/L), HbA_{1c} (%), Amylase (U/L), Lipase (U/L).

Table 1: Sequential laboratory results.

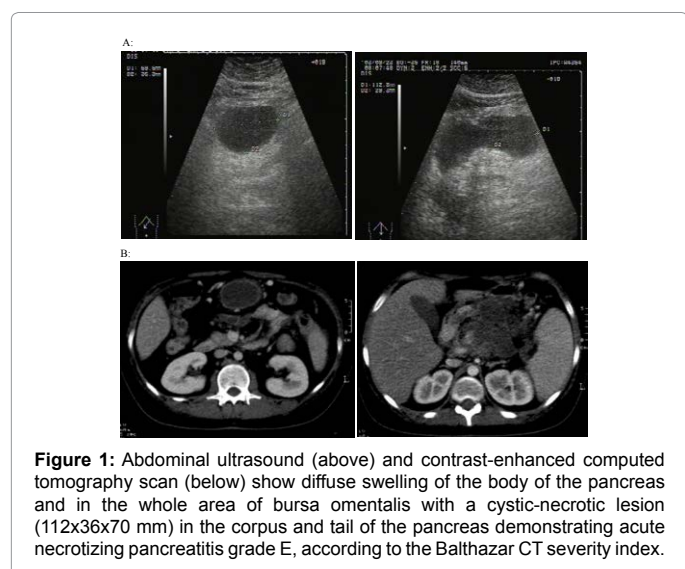


Figure 1: Abdominal ultrasound (above) and contrast-enhanced computed tomography scan (below) show diffuse swelling of the body of the pancreas and in the whole area of bursa omentalis with a cystic-necrotic lesion (112x36x70 mm) in the corpus and tail of the pancreas demonstrating acute necrotizing pancreatitis grade E, according to the Balthazar CT severity index.

Antibiotic treatment using meropenem was initiated on the 2nd day of hospitalization. Nasojejunal nutrition with a low fat, semi-elemental, nutritionally complete, short chain peptide based feed (Nutrison Advanced Peptisorb 1000 ml/day) was commenced and maintained for eight weeks. The hypertriglyceridemia (18.7 vs. 17.3 mmol/L) and hypercholesterolemia (12.4 vs. 10.1 mmol/L) persisted (24- and 72-hour values after admission) (Table 1). Lipid electrophoresis showed a Frederickson type V pattern, therefore fibrate therapy was started.

The patient was discharged with multiple daily insulin injections, metformin and fibrate medication. He had received a 2200-calorie diabetic diet, which restricted fat to 30% of total energy, saturated fat to 7% of calories, cholesterol intake to 200 mg/day. The avoidance of trans fats and eating of foods rich in long-chain omega-3 fatty acids (such as fatty fish, nuts and seeds) was recommended. Because of the physical activity is an integral part of weight management and treatment of T2D a moderate-to-vigorous exercise of at least 60 minutes daily was suggested for him. Three months later, his HbA_{1c} was 7.7%, cholesterol 4.1 mmol/L, and triglycerides 1.5 mmol/L (Table 1). Unfortunately, the long-term follow-up was not succeeding because of his compliance problems.

Islet cell specific autoantibodies (ICA, GADA) were negative; fasting serum C-peptide of 0.93 nmol/L was in the normal range (0.36-1.19 nmol/L). The patient's HLA DQB1 genotype was *0302/*0502, representing neutral autoimmune diabetes risk.

Discussion

The enigmatic triad of AP, HL and DKA has been rarely reported in childhood; we could identify only five cases (2-6). Nair and Pitchumoni considered four possible hypotheses concerning the pathomechanism of this triad in adult patients: 1, DKA causing HL which leads to AP, 2, AP complicated by DKA and HL, 3, HL causing AP complicated by DKA or 4, DKA inducing AP and HL [1]. Although all previous reports in children have demonstrated the first mechanism, the clinical history of our patient rather suggests the third one, which seems to be a rare scenario published only in two adult cases, so far [7,8] (Table 2).

In childhood, AP is a rare entity with a diverse etiology including HL, which is responsible for only 2% of the cases. The risk of AP becomes clinically significant at a fasting triglyceride level of over 1000 mg/dL (11.29 mmol/L), a level at which chylomicrons are present. The suspected pathomechanism: triglycerides and chylomicrons are hydrolyzed by lipase in the pancreatic capillaries and the free fatty acids released activate the trypsinogen and trigger the capillary damage by free radicals [9].

To establish a diagnosis of true primary hyperlipidemia-induced pancreatitis is generally difficult. The strongest clues for primary HL are a family history of hyperlipidemia, along with severe hypertriglyceridemia in the previous medical history and during the episode of AP. A degree of hypertriglyceridemia high enough to predispose to AP can occur in types I, IV, and V HL (Fredrickson's classification). In case of type I and V HL acute pancreatitis can develop spontaneously. However, in adults a more common clinical situation of hypertriglyceridemia-induced acute pancreatitis involves poorly-controlled diabetes mellitus with type IV hyperlipidemia [10]. The phenotype of HL can change during the course of time, namely if a lipoprotein analysis is performed within the first 24 to 48 hours after the onset of AP, it would rather reflect type V or I HL, but if the test is repeated several weeks later, the lipid profile usually changes to type IV, V, or III. Exact diagnosis can only be made if the patient is not taking medication for HL and there is no acute disease affecting lipid levels [11].

It is accepted that DKA often can cause both asymptomatic pancreatic enzyme elevation and acute abdominal pain. However, if the abdominal pain is not resolved with the improving metabolic situation, it raises the suspicion of co-existing AP. DKA is accepted as an independent risk for AP which occurs usually in 10-15% of episodes of DKA among adults [12]. In contrast, although at least 35-40% of children with newly diagnosed T1D are admitted with DKA, AP has been reported much less frequently, in only 2% of the cases [9]. Hypertriglyceridemia is the most common identifiable factor for AP seen in DKA. The hypothesis suggests that a transient but marked HL caused by the insulin deficiency may lead to AP. Namely, severe insulin deficiency leads to an accelerated mobilization of free fatty acids from adipose tissue resulting in an overproduction of very low-density lipoprotein (VLDL) in the liver and a reduced activity of lipoprotein lipase in peripheral tissue that decreases the clearance of VLDL from the plasma. In addition, if hepatic insulin resistance is also present, that can lead to a further enhanced production of VLDL [13]. The course of pancreatitis is usually mild in DKA, this generally means edematous pancreatitis with localized, self-limited symptoms; and at the same time the elevated VLDL-triglyceride and chylomicron levels are restored by the effective treatment of DKA with insulin therapy within 24-72 hours. In contrast, if primary HL is the background, after some prior episodes of mild AP a life-threatening hemorrhagic or necrotizing pancreatitis can develop. Insulin is considered to be the drug of choice in severe

Authors	Age/gender	Diabetes	Ketoacidosis	Hyper-lipidemia	Acute pancreatitis	Treatment
Lutfi et al. [1]	10-yr-old girl	newly diagnosed T1D	pH: 6.87 BE: -30	TC: 12.1 TG: 184.4	L: 3537	intravenous fluids and insulin infusion, plasmapheresis, fibrate therapy
Winter et al. [2]	11-yr-old boy	newly diagnosed T1D G: 16.1	pH: 7.27 BE: -18	TC: 25.1 TG: 245.9	A: 601	intravenous hydration, subcutaneous regular insulin, nasogastric suction
Aboulhosn et al. [3]	18-yr-old female	newly diagnosed T1D G: 13.0	pH: 6.99	TC: 19.5 TG: 19.5	A: 319	intravenous fluids and insulin infusion
Rius Riu et al. [4]	19-yr-old	newly diagnosed T1D	-	TG: elevated	A: elevated	intravenous fluids and insulin infusion
Hahn et al. [5]	20-yr-old female	known T1D G: 15.6	pH: 7.15	TC: 42.4 TG: 172.1	A: 81 L: 108 Ranson's score: 4 CT Balthazar's grade: D	intravenous fluids and insulin infusion
Lukacs et al. (present)	15-yr-old male	newly diagnosed T2D G: 32.1	pH: 7.12 BE: -20.8	TC: 16.3 TG: 21.1	A: 36 L: 532 Ranson's score: 4 CT Balthazar's grade: D	intravenous fluids and insulin infusion, nasogastric suction

T1D, type 1 diabetes; T2D, type 2 diabetes; G, glucose (mmol/L); BE, base excess (mmol/L); TG, triglycerides (mmol/L); TC, total cholesterol (mmol/L); A, amylase (U/L); L, lipase (U/L).

Table 2: Summary of the reported triad of diabetic ketoacidosis, hyperlipidemia and acute pancreatitis in children and adolescents.

hyperlipidemia-induced pancreatitis with concomitant hyperglycemia as well, but plasmapheresis and heparin administration as emergency treatment can also be used. Continuous fibrate therapy is needed in order to prevent the recurrence of pancreatitis [5], however if severe lipid disorders are present or lipid lowering drugs are insufficient, nutraceuticals could also be adopted. The lipid lowering drugs combined with fish oil supplementation or berberine, were found to be more effective in lowering LDL cholesterol and triglyceride levels, than the monotherapy [14].

Although DKA is a common acute complication of T1D, it should not be forgotten that the absolute or relative insulin deficiency can cause ketoacidosis in other forms of diabetes, as well [15]. The epidemiology of diabetes among children and adolescents is changing. Previously T1D accounted for 90-95% of childhood diabetes; now more adolescents are being diagnosed with T2D. HL may develop in these patients at the onset of diabetes as part of the metabolic syndrome, secondary to obesity and an unhealthy lifestyle [16].

It is also known that extreme hypertriglyceridemia can disturb the measurement of different plasma parameters e.g. amylase, sodium or glucose levels. In this situation "normoamylasemia" can lead to delay in the diagnosis of acute pancreatitis [17,18].

Our patient was an obese adolescent, previously diagnosed with hypertriglyceridemia and had a family history of hyperlipidemia. Suspicion of primary HL was confirmed by the high plasma level of triglycerides during AP which did not decrease within 72 hours after the initiation of insulin infusion and became normalized only with administration of fibrate [19]. The lipoprotein analysis showed the Frederickson type V pattern, which has a juvenile form and involves high VLDL in addition to chylomicrons due to increased VLDL production and decreased VLDL clearance [13]. The key role of primary hyperlipidemia may be indicated by the history of recurrent abdominal pain as a symptom of prior episodes of mild AP before the serious necrotic complication. This hypothesis is corroborated by the presence of pseudocyst at the time of AP, since the pseudocyst formation usually requires four or more weeks after the onset of AP. The high HbA_{1c} signified chronic hyperglycemia. The severe acanthosis nigricans, the normal fasting C-peptide level, the absence of any evidence for β -cell autoimmunity were diagnostic for T2D. However, we speculate that the diabetes was worsened by the pancreatic disease, as well.

In conclusion, the presentation of acute necrotizing pancreatitis

in a 'healthy' adolescent is highly unusual, and the triad of AP, DKA and HL becomes even more enigmatic. Although the exact pathogenic steps are uncertain, the clinical history of this patient suggests that his primary hyperlipidemia-induced acute necrotizing pancreatitis led to diabetic ketoacidosis as a first manifestation of type 2 diabetes. This report demonstrates that these morbidities which are relatively common in adults may occur in children, causing considerable diagnostic and therapeutic dilemma.

Acknowledgement

The authors are grateful to Istvan Karadi, Gyula Petranyi, Anna Korner and David Bullimore for critically reviewing the manuscript.

Reference

- Nair S, Pitchumoni CS (1997) Diabetic ketoacidosis, hyperlipidemia, and acute pancreatitis: the enigmatic triangle. *The American journal of gastroenterology* 92: 1560-1561.
- Winter RJ, Herr TJ, Stone NJ, Traisman HS (1980) Diabetic lipemia in childhood diabetic ketoacidosis: a clue to coexisting acute pancreatitis. *Diabetes care* 3: 706-707.
- Rius Riu F, Pizarro Lozano E, Reverter Calatayud JL, Gener Rexach J, Bechini J, (1993) [Acute pancreatitis in newly diagnosed type I diabetes mellitus with diabetic ketoacidosis and hypertriglyceridemia]. *Medicina clinica* 101: 622-624.
- Hahn SJ, Park JH, Lee JH, Lee JK, Kim KA (2010) Severe hypertriglyceridemia in diabetic ketoacidosis accompanied by acute pancreatitis: case report. *Journal of Korean medical science* 25: 1375-1378.
- Lutfi R, Huang J, Wong HR (2012) Plasmapheresis to treat hypertriglyceridemia in a child with diabetic ketoacidosis and pancreatitis. *Pediatrics* 129: e195-e198.
- Aboulhosn K, Arnason T (2013) Acute pancreatitis and severe hypertriglyceridaemia masking unsuspected underlying diabetic ketoacidosis. *BMJ case reports*
- Garnier P, Cailleba A, Lambert M, Moinade S, Maublant C et al. (1980) [Association of hyperlipidemia, acute pancreatitis and diabetic keto-acidosis. A case report (author's transl)]. *La semaine des hopitaux : organe fonde par l'Association d'enseignement medical des hopitaux de Paris* 56: 2035-2037.
- Kunisaki M, Ayukawa K, Oyamada C, Ogawa S (1991) [A case of non-insulin-dependent diabetes mellitus associated with diabetic ketoacidosis after the onset of hyperlipidemia and acute pancreatitis following alcohol abuse]. *Fukuoka igaku zasshi = Hukuoka acta medica* 82: 464-466.
- Benifla M, Weizman Z (2003) Acute pancreatitis in childhood: analysis of literature data. *Journal of clinical gastroenterology* 37: 169-172.
- Tsuang W, Navaneethan U, Ruiz L, Palascak JB, Gelrud A (2009) Hypertriglyceridemic pancreatitis: presentation and management. *The American journal of gastroenterology* 104: 984-991.

11. Yadav D, Pitchumoni CS (2003) Issues in hyperlipidemic pancreatitis. *Journal of clinical gastroenterology* 36: 54-62.
12. Nair S, Yadav D, Pitchumoni CS (2000) Association of diabetic ketoacidosis and acute pancreatitis: observations in 100 consecutive episodes of DKA. *The American journal of gastroenterology* 95: 2795-2800.
13. Wasada T (1997) Type V hyperlipidemia associated with diabetic ketoacidosis. *Internal medicine* 36: 535.
14. Scicchitano P, Cameli M, Maiello M (2014) Nutraceuticals and dyslipidaemia: Beyond the common therapeutics. *Journal of functional foods* 6: 11-32.
15. Wang ZH, Kihl-Selstam E, Eriksson JW (2008) Ketoacidosis occurs in both Type 1 and Type 2 diabetes--a population-based study from Northern Sweden. *Diabetic medicine : a journal of the British Diabetic Association* 25: 867-870.
16. Guttman A, Nakhla M, Henderson M, To T, Daneman D, et al. (2010) Validation of a health administrative data algorithm for assessing the epidemiology of diabetes in Canadian children. *Pediatric diabetes* 11: 122-128.
17. Akbay S, Yel A, Yildirimer U, Can S, Dundar B (2013) Diabetic ketoacidosis presenting with pseudonormoglycemia in a 15-year-old girl with type 1 diabetes mellitus. *Journal of clinical research in pediatric endocrinology* 5: 133-135.
18. Frier BM, Steer CR, Baird JD, Bloomfield S (1980) Misleading plasma electrolytes in diabetic children with severe hyperlipidaemia. *Archives of disease in childhood* 55: 771-775.
19. Andren-Sandberg A, Dervenis C (2004) Pancreatic pseudocysts in the 21st century. Part I: classification, pathophysiology, anatomic considerations and treatment. *JOP : Journal of the pancreas* 5: 8-24.

Citation: Lukacs K, Barkai LJ, Palik E, Szabo AJ, Madacsy L, et al. (2016) Primary Hyperlipidemia, Acute Pancreatitis and ketoacidosis in an Adolescent with Type 2 Diabetes. *J Diabetes Metab* 7: 651. doi:[10.4172/2155-6156.1000651](https://doi.org/10.4172/2155-6156.1000651)

OMICS International: Publication Benefits & Features

Unique features:

- Increased global visibility of articles through worldwide distribution and indexing
- Showcasing recent research output in a timely and updated manner
- Special issues on the current trends of scientific research

Special features:

- 700 Open Access Journals
- 50,000 Editorial team
- Rapid review process
- Quality and quick editorial, review and publication processing
- Indexing at PubMed (partial), Scopus, EBSCO, Index Copernicus, Google Scholar etc.
- Sharing Option: Social Networking Enabled
- Authors, Reviewers and Editors rewarded with online Scientific Credits
- Better discount for your subsequent articles

Submit your manuscript at: <http://www.omicsonline.org/submission>