

Protective Effects of Vitamin C against Methomyl-Induced Injuries on the Testicular Antioxidant Status and Apoptosis-Related Gene Expression in Rat

Tarek M Heikal^{1*}, Abdel-Tawab H Mossa¹ and Wagdy KB Khalil²

¹Environmental Toxicology Research Unit (ETRU), Pesticide Chemistry Department, National Research Centre, Cairo, Egypt

²Cell Biology Department, National Research Center, Dokki, Giza, Egypt

Abstract

The present study is undertaken to evaluate the protective effects of vitamin C (VC) against methomyl-induced oxidative stress and testicular injuries in Wistar rat. Male rats were randomly divided into 4 groups of 6 rats each. The route of application selected for the study was oral gavage for 28 consecutive days. Group 1 was served as a control, whereas group 2 was supplemented with VC (200 mg kg⁻¹ body weight, bw). Group 3 was administered with a dose of methomyl equivalent to 1/10 LD₅₀ (2.034 mg kg⁻¹ bw), whereas group 4 was co-administered VC and methomyl as the same dose of groups 2 and 3, respectively. Sub-acute exposure of rats to methomyl for 28 consecutive days resulted in a significant increase in testicular lipid peroxidation (LPO) and a decrease in glutathione (GSH) level. In addition, the testicular activities of catalase (CAT), superoxide dismutase (SOD) and glutathione-S-transferase (GST) enzymes were significantly declined in response to methomyl exposure. Furthermore, histopathological studies in testis of rats treated with methomyl exhibited incomplete spermatogenic series in seminiferous tubules and necrosis of spermatogoneal cells lining seminiferous tubules. Notably, the co-administration of VC modulated the biochemical parameters and the intensity of histopathological findings. The effect of VC on transcriptional activity of four key stress and apoptosis-related genes (CASP3, CASP9, Tp53 and Bcl2), in response to methomyl exposure in rats, was investigated. Results revealed a significant up-regulation in the level of the expression for the tested genes, however supplementation of VC to methomyl-treated rats modulated the observed significant up-regulation in the level of the expression for those genes, indicative of a protective interfering role in the signaling transduction process of methomyl-mediated toxicity. In conclusion, these data suggested that administration of VC may partially protect against methomyl induced testicular oxidative damage and apoptosis-related genes.

Keywords: Gene expression; Methomyl; Oxidative damage; Rat; Testis; Vitamin C

Introduction

Pesticides are deliberately added to the environment for the purposes of controlling the undesired agricultural pests and insects. In fact, most pesticides are not highly selective, but are generally toxic to many non target species, including humans causing public health hazards [1-4].

Methomyl is an oxime carbamate insecticide and widely used for the control of a large variety of insects on a wide range of crops all over the world. The mechanism of toxicity of carbamates is analogous to that of OPs, in that they inhibit AChE. However, inhibition is transient and rapidly reversible, because there is a rapid reactivation of the carbamylated enzyme in the presence of water [5]. Additionally, carbamylated AChE does not undergo aging [5].

The toxicity of methomyl and other insecticides is ascribed, at least in part, to the generation of reactive oxygen species (ROS), leading to lipid peroxidation (LPO) and oxidative stress [4,6-9]. Studies from our laboratory have exhibited a state of oxidative stress induced in adult rat liver following exposure to methomyl [10].

Cell death by apoptosis is genetically controlled. Apoptosis is a part of normal development and maintenance of testicular homeostasis [11]. During various stages of spermatogenesis, an adequate amount of germ cells are eliminated via the process of apoptosis in order to maintain a precise germ cell population in compliance with the supportive capacity of the Sertoli cells [12]. Since, ROS is considered a potential signal for apoptosis so, the elevated levels of ROS can cause oxidation of the mitochondrial pores thereby disrupting the mitochondrial membrane potential, releasing cytochrome c and activating the mitochondrial-mediated pathway of apoptosis. In addition, ROS have been shown to

induce the expression of Fas receptor and ligand stimulating Fas/FasL-mediated apoptotic signal transduction pathway. Several environmental disruptors are known to inappropriately activate apoptosis in testicular locale by increasing the levels of ROS [13-15].

Caspases are a part of highly conserved protein family that is central to the apoptotic pathway. They are proteases activated after a cell receiving an instructing signal to undergo apoptosis. They can also activate other enzymes that degrade other parts of the cellular machinery by cleaving an inhibitory sequence on these enzymes. CASP3 is an important biomarker of the apoptosis process [16].

Bcl-2 inhibits most types of cell death, implying a common mechanism of lethality. It is localized in intracellular sites of oxygen-free radical generation including mitochondria, endoplasmic reticula, and nuclear membranes [17]. The mechanism by which *Bcl-2* exerts its anti-apoptotic effects is not fully resolved, although it has been speculated that *Bcl-2* acts as either a regulator of an antioxidant pathway that prevents oxidative damage, or as a regulator of intracellular

***Corresponding author:** Tarek M Heikal, Environmental Toxicology Research Unit (ETRU), Pesticide Chemistry Department, National Research Centre, Tahrir Street, P.O. Box 12311, Dokki, Cairo, Egypt, Tel: +2 01002591307; Fax: (202) -33370931; E-mail: tarekhl@yahoo.com

Received November 20, 2014; **Accepted** December 11, 2014; **Published** December 12, 2014

Citation: Heikal TM, Mossa ATH, Khalil WKB (2014) Protective Effects of Vitamin C against Methomyl-Induced Injuries on the Testicular Antioxidant Status and Apoptosis-Related Gene Expression in Rat. J Environ Anal Toxicol 4: 255. doi: 10.4172/2161-0525.1000255

Copyright: © 2014 Heikal TM, et al. This is an open-access article distributed under the terms of the Creative Commons Attribution License, which permits unrestricted use, distribution, and reproduction in any medium, provided the original author and source are credited.

Ca²⁺ compartmentalization [18]. The anti-apoptotic activity of *Bcl-2* correlates with its intracellular ratio to another recently described protein called Bax. High levels of Bax have been shown to favor apoptosis in cells subjected to growth factor deprivation, whereas high levels of *Bcl-2* prolong cell survival under the same conditions [19].

Taking a lead from these reports and our previous studies, we thought to investigate whether treatment with a sub-lethal dose of methomyl would alter the antioxidant status and the levels of apoptosis-related gene expressions (i.e. *Tp53*, *Bcl-2*, *CASP3* and *CASP9*) in adult rat testis as well as the role of VC in attenuating such hazards.

Materials and Methods

Chemicals

Methomyl (Lannate® 90% SP, S-methyl N-[methylcarbamoyloxy] thioacetimidate), was obtained from Kafr El-Zayat Pesticides and Chemicals Company, Egypt and Vitamin C (L-Ascorbic acid) were purchased from Sigma-Aldrich Chemie (Steinheim, Germany). The assay kits used for biochemical measurements of catalase (CAT), superoxide dismutase (SOD), glutathione-S-transferase (GST), glutathione reduced (GSH), lipid peroxidation (LPO) and total protein were purchased from Biodiagnostic Company, Dokki, Giza, Egypt. All other chemicals were of reagent grades and obtained from the local scientific distributors in Egypt.

Animals

Male albino rats of Wistar strain (*Rattus norvegicus*) weighing 180 ± 10 g, obtained from the Animal Breeding House, National Research Centre (NRC), Dokki, Cairo, Egypt, were kept in well-ventilated plastic cages, provided with pellets, water *ad libitum* and subjected to a 12:12 light-to-dark photo period. All animal procedures were approved by the National Research Centre (NRC), Cairo, Egypt Local Ethical Review Committee and were carried out in accordance with the "Guide for the Care and Use of Laboratory Animals".

Experimental design

After acclimatization period for one week under laboratory conditions, rats were randomly divided into 4 groups each containing 6 animals. The route of application selected for the study was daily oral gavage for 28 consecutive days. Rats in Group I were served as a control. Rats in Group II (VC) were given VC in water at a dose of 200 mg/kg b.wt (0.5 ml/rat) based on our previous work [20]. Rats in Group III were administered methomyl in water at a dose of 2.034 mg kg⁻¹ b.wt (1/10 LD₅₀, 0.5 ml/rat) based on estimated LD₅₀ (20.34 mg kg⁻¹ b.wt) in our laboratory [10]. Rats in Group IV (methomyl+VC) were given the same doses of VC as in group II 30 min before the administration of methomyl (2.034 mg kg⁻¹ b.wt.). During the experimental duration, body weights were weekly recorded and the doses of the tested compounds were modulated accordingly.

At the end of the administration, the animals were fasted overnight with water *ad libitum*, anesthetized with pentobarbital sodium (35mg/kg, i.p.) and sacrificed by cervical dislocation on 29th day. Testis were dissected out immediately, washed with ice cold saline and cleaned. Testis tissues from control and experimental groups were washed with ice cold saline, homogenized in 10% (w/v) ice cold phosphate buffer (0.1M pH 7.4) and centrifugation at 10,000 ×g for 30 minutes at 4°C. The supernatants obtained were used for the assays of SOD, CAT, GST, LPO, GSH and total protein.

Oxidative stress evaluation

Lipid peroxidation (LPO) process is determined in supernatant of testicular tissue homogenate by the thiobarbituric acid (TBA) method which estimates the malondialdehyde formation (MDA) according to Esterbauer and Cheeseman [21]. Two hundred fifty microliters of tissue homogenate were added to 1.5 ml of 1% phosphoric acid (pH 2.0) and 1 ml of 0.6% of TBA in air-light tubes and were placed in a boiling water bath for 25 min. After incubation, the sample was cooled to room temperature and MDA-TBA was extracted with 2.5 ml of butanol. Organic phase was separated by centrifugation for 5 min at 2000 ×g and measured at 532 nm. The concentration of MDA was calculated by the absorbance coefficient of MDA-TBA complex (1.56 × 10⁵ M⁻¹ cm⁻¹). Lipid peroxidation is expressed as nmoles MDA/mg protein.

Reduced glutathione (GSH) content of supernatant estimation was performed by the method of Beutler et al. using commercial glutathione reduced kits (Biodiagnostic for diagnostic reagents: Dokki, Giza, Egypt). Determination of GSH is based on the reaction of DTNB [5, 5'-dithiobis-(2-nitrobenzoic acid)] with GSH and yield a yellow colored chromophore with a maximum absorbance at 412 nm [22]. The amount of GSH present in the testicular tissue was calculated as nmoles/g tissue.

Catalase (CAT) converts H₂O₂ into water. In brief, 0.25 g of tissue was homogenated in 1 ml of 50 mM Tris-HCl and centrifuged at 2000 ×g for 15 min. Then 10 µl of supernatant was added to a quartz cuvette containing 980 µl of distilled water, and 10 µl of 0.066 M H₂O₂ (dissolved in sodium phosphate buffer) was added to start the reaction. The testicular CAT activity was measured spectrophotometrically at 240 nm by calculating the rate of degradation of H₂O₂, the substrate of the enzyme [23]. Activity of CAT is expressed as units/mg protein.

The specific activity of testicular superoxide dismutase (SOD) was determined according to the method described by Misra and Fridovich [24]. Ten micro liters of tissue homogenate were added to 970 µl of EDTA-sodium carbonate buffer (0.05 M) at pH 10.2. The reaction was started by adding 20 µl of epinephrine (30 mM) and the activity was measured at 480 nm for 4 min. A unit of SOD is defined as the amount of enzyme that inhibits by 50% the speed of oxidation of epinephrine and the results were expressed as U/mg protein.

Glutathione-S-transferase (GST) activity of testicular was measured spectrophotometrically by the method of Habig et al. using 1-chloro-2,4-dinitrobenzene as electrophilic substrate that binds to GSH with the participation of the enzyme and forms a colored GSH-substrate complex, detected at 340 nm [25]. The activity of GST was expressed in terms of µmol/min/mg protein.

The total protein level of supernatant was determined according to the method described by Lowry et al. using bovine serum albumin (BSA) as a standard [26].

DNA fragmentation

DNA fragmentation was assessed by electrophoresis of extracted genomic DNA from testis tissues as described by Lu et al. with slight modifications. Briefly, cells were washed with PBS containing 10 mM EDTA. The pellet was lysed in 250 µL of lysis buffer (100mM NaCl, 5mM EDTA, 10mM Tris-HCl, pH 8.0, 5% Triton X-100, 0.25% SDS), containing 400 µg/mL DNase-free RNase and incubated at 37°C for 90 minutes followed by 1 hour incubation with proteinase-K (200 µg/mL) at 50°C. DNA was extracted with 200µL of phenol : chloroform: isoamyl

alcohol (25 : 24 : 1) for 1 minute and centrifuged at $13000 \times g$ for 3 minutes. The aqueous phase was further extracted with chloroform and centrifuged [27]. DNA was precipitated from aqueous phase with 3 volumes of chilled alcohol containing 0.3M sodium acetate at 4°C overnight. The precipitate was centrifuged at $13000 \times g$ for 10 minutes. DNA pellet was washed with 80% alcohol, dried, dissolved in 50 μ L TE buffer and electrophoresed in 1.8% agarose gel at 50V, stained with ethidium bromide, and visualized in Biometra Gel Documentation System.

Semi-quantitative RT-PCR

Total RNA (Poly(A)⁺ RNA) was extracted from 50 mg of testis tissues using the standard TRIzol extraction method (Invitrogen, Paisley, UK) and recovered in 100 μ L diethylpyrocarbonate (DEPC)-treated water by passing the solution a few times through a pipette tip.

Total RNA was treated with one unit of RQ1 RNase-free DNase (Invitrogen, Karlsruhe, Germany) to digest DNA residues, re-suspended in DEPC-treated water, and quantified photospectrometrically at 260 nm. Total RNA was assessed for purity from the ratio between quantifications at 260 nm and 280 nm, and was between 1.8 and 2.1. Integrity was verified with the ethidium bromide-stain analysis of 28S and 18S bands using formaldehyde-containing agarose gel electrophoresis. Aliquots were either used immediately for reverse transcription (RT) or stored at -80°C.

To synthesise first-strand cDNA, 5 μ g of complete Poly(A)⁺ RNA was reverse transcribed into cDNA in a total volume of 20 μ L using 1 μ L oligo (poly(deoxythymidine)18) primer (36). The composition of the reaction mixture was 50 mmol L⁻¹ MgCl₂, 10x RT buffer (50 mmol L⁻¹ KCl; 10 mmol L⁻¹ Tris-HCl; pH 8.3), 200 U μ L⁻¹ reverse transcriptase (RNase H free, Fermentas, Leon-Rot, Germany), 10 mmol L⁻¹ of each dNTP, and 50 μ mol L⁻¹ of oligo(dT) primer. RT reaction was carried out at 25°C for 10 min, followed by 1 h at 42°C, and completed with denaturation at 99°C for 5 min. Reaction tubes containing RT preparations were then flash-cooled in an ice chamber until used for DNA amplification through polymerase chain reaction (PCR) [28].

First-strand cDNA was used as a template for semi-quantitative RT-PCR with a pair of specific primers in a 25- μ L reaction volume. The sequences of specific primer and are listed in Table 1. GAPDH and β -Actin were used to normalize mRNA levels of the target genes. The reaction mixture for RT-PCR consisted of 10 mmol L⁻¹ dNTP's, 50 mmol L⁻¹ MgCl₂, 10x PCR buffer (50 mmol L⁻¹ KCl; 20 mmol L⁻¹ Tris-HCl; pH 8.3), 1 U μ L⁻¹ taq polymerase, and autoclaved water. Table 1 lists the specific gene primer sequences and PCR annealing temperature. PCR products derived from GAPDH and β -Actin were then loaded onto 2.0 % agarose gel. Each RT-PCR was repeated for each rat, generating at least ten new cDNA products per group.

Histopathological examination

For light microscopic investigations, specimens from testes were fixed in 10% phosphate buffer formalin, dehydrated in alcohols and embedded in paraffin. Five micron tissue sections were stained with hematoxylin and eosin stain (H&E) for general histopathological examination. Scoring of histopathological changes was done as follow: (-) absent; (+) mild; (++) moderate; (+++) severe, and (+++++) extremely severe [29].

Statistical analysis

All results were presented as means \pm SE. All data were done with the Statistical Package for Social Sciences (SPSS 17.0 for windows). The results were analyzed using one way analysis of variance (ANOVA)

followed by Duncan's test for comparison between different treatment groups. Statistical significance was set at $p < 0.05$.

Results

Effect on oxidative stress markers

The present results revealed that administration of methomyl at a dose of 2.034 mg kg⁻¹ b.wt for 28 days induced testicular oxidative stress as evidenced by a significant decline ($p < 0.05$) in the content of GSH by -44.3% as well as a significant increase ($p < 0.05$) in the level of lipid peroxidation (LPO) by +49%, compared with the control group. Simultaneously in methomyl-treated group, the activities of testicular antioxidant enzymes were reduced significantly ($p < 0.05$) by -23.7, -21.3 and -20.8% for SOD, CAT and GST, respectively compared with the control group (Table 2). However, co-administration of VC to methomyl mitigated the perturbations in the oxidative stress biochemical parameters (Table 2).

Effect on DNA fragmentation

Quantitative DNA fragmentation was determined in male rats exposed to methomyl with or without VC. The DNA damage was examined in testis tissues collected from pesticides-treated rats using gel electrophoresis laddering assay (Figure 1). The results of gel electrophoresis laddering assay revealed that treatment of male rats with VC alone caused similar low DNA damage to that in control group (Figure 1). However, methomyl treated rats expressed more bands of the damaged DNA compared with the control and VC treated rats (Figure 1). In contrary, treatment of rats with VC decreased the damage in the DNA caused by methomyl in the group treated with pesticides combined with VC (Figure 1).

Effect on gene expression

Study the expression alteration of key stress and apoptosis-related genes (CASP3, CASP9, Tp53 and Bcl2) was investigated in rat testis tissues (Figure 2-5, respectively).

The expression level of *CASP3*, *CASP9*, *Tp53* and *Bcl2* genes was low in control group compared with other treated group. The same trend was found in the rats treated with VC alone. Where, the expression level of these genes was similar in VC treated rat with that in control rats (Figure 2-5). On the other hand, the expression level of *CASP3*, *CASP9*, *Tp53* and *Bcl2* genes was significantly higher in methomyl treated rats than in control and VC treated rats (Figure 2-5).

In contrast, treatment of rats with VC decreased significantly the over-expression levels of the *CASP3*, *CASP9* and *Bcl2* genes resulted from methomyl treatment in the group treated with methomyl plus VC (Figure 2-5). Furthermore, VC was also able to decrease the over-expression level of the *Tp53* gene caused by methomyl treatment in the group treated with methomyl plus VC (Figure 4), however, the decline in the expression was not significantly different.

Histopathology

While control animals exhibited normal histological structures of mature seminiferous tubules with complete spermatogenic series, methomyl treatment promoted incomplete spermatogenic series in seminiferous tubules, degenerative changes, necrosis of spermatogoneal cells lining seminiferous tubules and desquamation in the lumen (Figure 6 A-D). However, co-administration of VC to methomyl alleviated the histopathological findings and the severity of such findings in the presence and absence of VC were demonstrated in (Table 3).

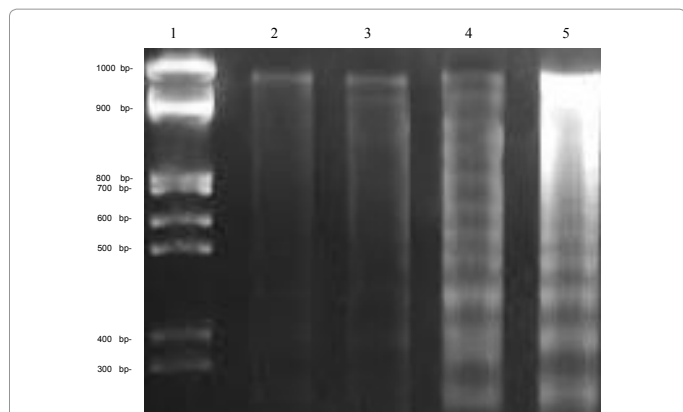


Figure 1: DNA fragmentation detected with agarose gel of DNA extracted from testis tissues of male rats treated with methomyl in the absence and presence of vitamin C analyzed by DNA gel electrophoresis laddering assay. Lane 1 represents DNA ladder. Lane 2 represents control samples. Lane 3 shows DNA fragmentation in testis tissues following vitamin C treatment. Lane 4 shows DNA fragmentation in testis tissues following methomyl and vitamin C treatment. Lane 5 shows DNA fragmentation in testis tissues following methomyl treatment.

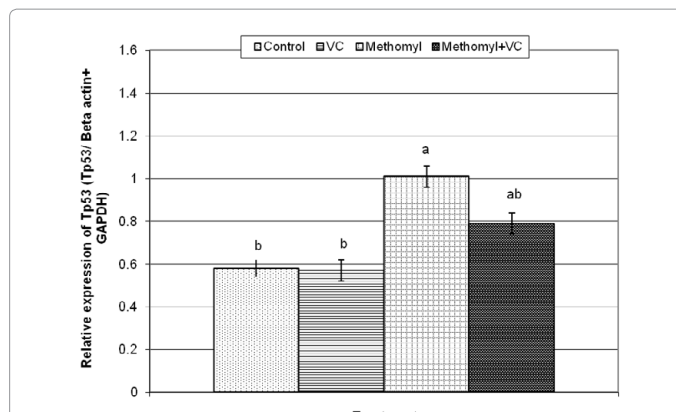


Figure 4: Semi-quantitative RT-PCR confirmation of *Tp53* gene in male rats treated with pesticides with or without vitamin C (VC). Each value is a mean of 6 animals \pm SE. Values are not sharing superscripts letters (a, b, c,) differ significantly at $p < 0.05$.

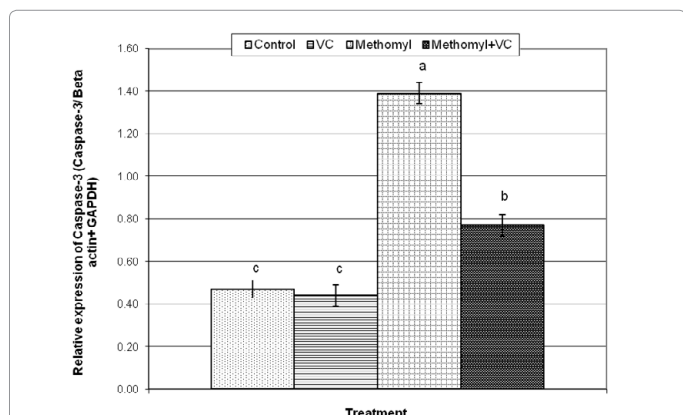


Figure 2: Semi-quantitative RT-PCR confirmation of *Caspase-3* gene in male rats treated with methomyl with or without vitamin C (VC). Values are not sharing superscripts letters (a, b, c,...) differ significantly at $p < 0.05$.

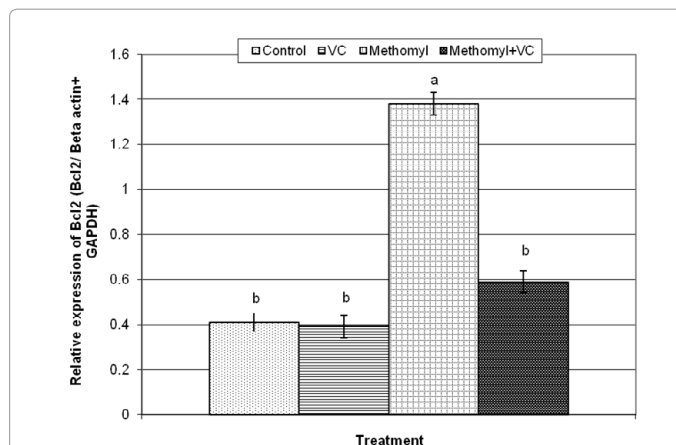


Figure 5: Semi-quantitative RT-PCR confirmation of *Bcl2* gene in male rats treated with pesticides with or without vitamin C (VC). Each value is a mean of 6 animals \pm SE. Values are not sharing superscripts letters (a, b, c,) differ significantly at $p < 0.05$.

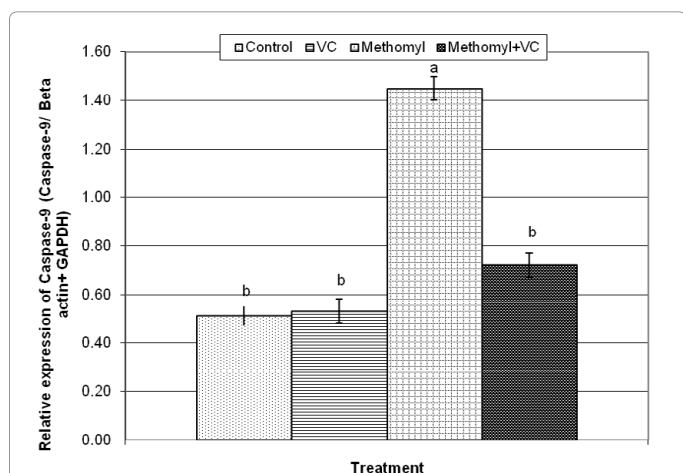


Figure 3: Semi-quantitative RT-PCR confirmation of *Caspase-9* gene in male rats treated with methomyl with or without vitamin C (VC). Each value is a mean of 6 animals \pm SE. Values are not sharing superscripts letters (a, b, c,) differ significantly at $p < 0.05$.

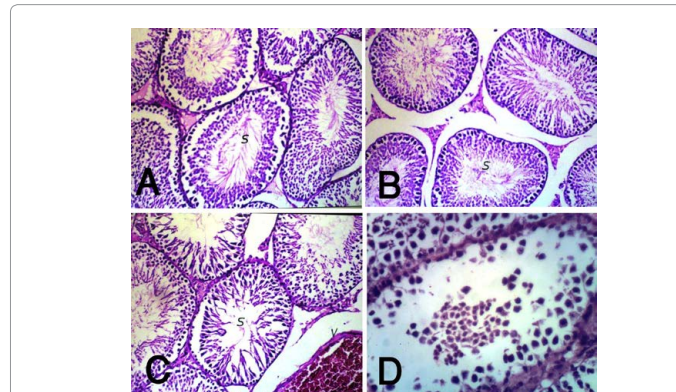


Figure 6: Testes paraffin sections stained by haematoxylin and eosin (H&E) for histopathological changes after 28 days administration of methomyl with and without vitamin C. Control [A] and vitamin C [B] groups showing normal histological structure of mature seminiferous tubules with complete spermatogenic series (s) ($\times 200$), Methomyl-treated group showing severe congestion in blood vessels (V) with incomplete spermatogenic series in some individual seminiferous tubules (s) [C, $\times 200$], degenerative changes and necrosis of spermatogoneal cells lining seminiferous tubules and desquamated in the lumen [D, $\times 400$].

Target genes	Forward (F) and reverse (R) Primers (5'→3')	Annealing T (°C)
Caspase-3	F: CAG AGC TGG ACT GCG GTA TTG A	60 (Aboul-Soud et al., 2011)
	R: AGC ATG GCG CAA AGT GAC TG	
Caspase-9	F: AGC CAG ATG CTG TCC CAT AC	60 (Aboul-Soud et al., 2011)
	R: CAG GAG ACA AAA CCT GGG AA	
Tp53	F: GTC GGC TCC GAC TAT ACC ACT ATC	60 (Aboul-Soud et al., 2011)
	R: CTC TCT TTG CAC TCC CTG GGG G	
Bcl ₂	F: CTC AGT CAT CCA CAG GGC GA	65 (Khalil and Booles, 2011)
	R: AGA GGG GCT ACG AGT GGG AT	
GAPDH	F: GCT GCC TTC TCT TGT GAC AAA GT	60 (Aboul-Soud et al., 2011)
	R: CTC AGC CTT GAC TGT GCC ATT	
β-Actin	F: GTG GGC CGC TCT AGG CAC CAA	65 (Khalil and Booles, 2011)
	R: CTC TTT GAT GTC ACG CAC GAT TTC	

Table 1: Primers used for RT-PCR

Treatments	SOD (U/g tissue)	CAT (U/g tissue)	GST (U/ g tissue)	LPO (nmol/g tissue)	GSH (mmol/ g tissue)
Control	635.1 ± 39.2 ^a	292.4 ± 17.0 ^a	1893.4 ± 75.1 ^a	221.6 ± 12.2 ^a	143.2 ± 6.7 ^a
VC	625.2 ± 32.9 ^{ab}	285.4 ± 14.5 ^a	1873.2 ± 77.3 ^a	232.8 ± 14.8 ^a	136.6 ± 4.3 ^a
Methomyl	484.4 ± 27.5 ^c	230.0 ± 14.7 ^b	1499.8 ± 48.1 ^b	330.2 ± 19.1 ^b	79.8 ± 7.0 ^b
Methomyl +VC	582.2 ± 34.0 ^b	274.0 ± 16.6 ^a	1772.2 ± 75.3 ^c	283.8 ± 12.9 ^c	106.8 ± 7.2 ^c

Each value is a mean of 6 animals ± SE; values are not sharing superscripts letters (a, b, c,) differ significantly at $p < 0.05$; CAT: catalase; GST: glutathione-S-transferase; LPO: lipid peroxidation; GSH: glutathione; VC: vitamin C

Table 2: The effect on the activity of antioxidant enzymes (SOD, CAT and GST) and the levels of lipid peroxidation (LPO) and non enzymatic antioxidant (GSH) in testis of rat exposed to methomyl and vitamin C.

Histopathological alterations	Treatments			
	Control	VC	Methomyl	Methomyl+VC
Incomplete spermatogenesis	-	-	++++	++
Congestion of blood vessels	-	-	+++	+
Degeneration and necrosis of spermatogoneal cells	-	-	++++	++

(-) indicates normal, (+) indicates mild, (++) indicates moderate, (+++) indicates severe, and (+++++) indicates extremely severe. Vitamin C: VC

Table 3: The severity of the reaction in testicular tissue according to the histopathological alterations in different groups

Discussion

The present study was implemented to examine the protective effect of VC on both the antioxidant status and the expression level of selected apoptosis-related genes (*CASP3*, *CASP9*, *Tp53* and *Bcl₂*) during methomyl-mediated oxidative stress and testicular injuries in male rat. It is well documented that many carbamates cause genotoxicity. Genotoxicity of agrochemicals is considered one of the most serious side effects on human beings. If a chemical reacts with nuclear DNA, it may be mutagenic and carcinogenic to the exposed organisms [30,31]. Prolonged exposure to such chemicals may lead to heritable genetic diseases, carcinogenesis, reproductive dysfunction, and birth defects. Although methomyl is degraded rapidly and its metabolic residues have low toxicity, however, long-term exposure to methomyl may induce genetic damage in human beings [32]. Methomyl induced chromosome aberrations, sister-chromatid exchanges, micronuclei and DNA single strand breaks in agricultural workers peripheral blood

[32,33].

The reactive oxygen species (ROS) are continuously generated inside the human body as a consequences of exposure to a lot of exogenous chemicals in our ambient environment including pesticides. Under normal circumstances, the ROS generated are eliminated by enzymatic and non-enzymatic antioxidant systems present in the body. Harmful effects caused by ROS occur as a consequence of an imbalance between the formation and elimination of these species culminates in an oxidative stress [34]. ROS readily attack and induce oxidative damage to various bio-molecules including proteins, lipids, mitochondria, lipoproteins and DNA which alter the pathways of these bio-molecules [35]. Oxidative stress affects many cellular functions by various mechanisms such as alteration in gene expression through activation of transcription [15,36].

The data of the present study confirmed an exacerbation of oxidative injury in testis tissues of methomyl-treated rat group as evidenced by

an elevation in LPO and a reduction in testicular GSH, CAT, SOD and GST. These data are consistent with our previous observation in testis, liver and kidney tissues of rats and mice treated with different insecticides including methomyl [4,8,20,37]. This is supported by our histopathological results. The testicular degenerative changes induced by methomyl in intoxicated rats, as demonstrated in this study, agree with those of Mahgoub and Mednay, who reported variable degrees of degenerative changes and necrosis in the seminiferous tubules up to total cellular destruction after chronic exposure for 30 days of male rats to methomyl [2]. In this context, Pant *et al.* concluded that carbofuran, carbamate insecticide, induced moderate edema, congestion, damage to Sertoli cells and germ cells, along with the accumulation of cellular debris in the lumen of a few seminiferous tubules which showed disturbed spermatogenesis [38]. The role of VC as a water soluble antioxidant in biological systems is well known and can be summarized as scavenging free radical [39], restoring vitamin E [40], neutralizing the reactive oxygen metabolites, and reducing DNA damage and hence genetic mutation [20,41]. In the present study, our data remarkably suggest protective effects of co-administration of VC in attenuating the levels of biochemical parameters and histopathological observations.

The toxic effect and testicular damage induced by methomyl in this study could be possibly explained by its direct cytotoxic effect and/or indirectly via the increased level of ROS and apoptosis-mediated genes. Many studies have reported correlation between exposure to OP insecticides and apoptosis-related genes expression in rats [42]. In this respect, we have examined the impact of methomyl treatment in the selected apoptosis-related genes, namely: *Tp53*, *Bcl-2*, *CASP3* and *CASP9*. In our study, the results revealed that subchronic exposure of rat to methomyl for 28 days is associated with a significant up-regulation of the expression of apoptosis-related genes, compared with the control.

Conclusion

These data suggested that administration of VC may partially protect against methomyl induced testicular oxidative damage and apoptosis-related genes. We propose that VC may provide a prolonged remedy against toxins-induced oxidative damage and up-regulation of genes expression without harmful side effects.

References

1. Nafstad I, Berge G, Sannes E, Lyngset A (1983) Teratogenic effects of the organophosphorus compound fenchlorphos in rabbits. *Acta Vet Scand* 24: 295-304.
2. Mahgoub AA, El-Medany AH (2001) Evaluation of chronic exposure of the male rat reproductive system to the insecticide methomyl. *Pharmacol Res* 44: 73-80.
3. Meeker JD, Ryan L, Barr DB, Hauser R (2006) Exposure to nonpersistent insecticides and male reproductive hormones. *Epidemiology* 17: 61-68.
4. Heikal TM, Mossa AH, Ibrahim AW, Abdel-hamid HF (2014) Oxidative Damage and Reproductive Toxicity Associated with Cyromazine and Chlorpyrifos in Male Rats: The Protective Effects of Green Tea Extract. *Res J Environ Toxicol* 8: 53-67.
5. Ecobichon D J (2001) Carbamate insecticides. In *Handbook of Pesticide Toxicology* (Krieger R., ed), Academic Press, USA 1087-1106.
6. Rai DK, Sharma B (2007) Carbofuran-induced oxidative stress in mammalian brain. *Mol Biotechnol* 37: 66-71.
7. Heikal TM, Ghanem HZ, Soliman MS (2011) Protective effect of green tea extracts against dimethoate induced DNA damage and oxidant/antioxidant status in male rats. *Biohealth Sci Bull* 3: 1-11.
8. Heikal TM, Mossa AH, Abdel Rasoul MA, Marei GIKH (2013) The ameliorating effects of green tea extract against cyromazine and chlorpyrifos induced liver toxicity in male rats. *Asian J Pharmaceut Clin Res* 6.
9. Halliwell B, Gutteridge JMC (2002) *Free Radicals in Biology and Medicine*. 3rd ed. Oxford: University Press Inc. 105-245.
10. Mansour SA, Barakat AA, Mahafraash SM, Heikal TM, Said Elmaheey SA (2012) Ameliorative effect of selenium on the hepatotoxicity of methomyl, some common drugs and their combinations. *ScienceJet* 1:18
11. Grunewald S, Paasch U, Said TM, Sharma RK, Glander HJ, et al. (2005) Caspase activation in human spermatozoa in response to physiological and pathological stimuli. *Fertil Steril* 83 Suppl 1: 1106-1112.
12. Chandra J, Samali A, Orrenius S (2000) Triggering and modulation of apoptosis by oxidative stress. *Free Radic Biol Med* 29: 323-333.
13. Lee J, Richburg JH, Shipp EB, Meistrich ML, Boekelheide K (1999) The Fas system, a regulator of testicular germ cell apoptosis, is differentially up-regulated in Sertoli cell versus germ cell injury of the testis. *Endocrinology* 140: 852-858.
14. Kaur P, Kaur G, Bansal MP (2006) Tertiary-butyl hydroperoxide induced oxidative stress and male reproductive activity in mice: role of transcription factor NfκB and testicular antioxidant enzymes. *Reprod Toxicol* 22: 479-484.
15. Saradha B, Vaithinathan S, Mathur PP (2009) Lindane induces testicular apoptosis in adult Wistar rats through the involvement of Fas-FasL and mitochondria-dependent pathways. *Toxicology* 255: 131-139.
16. Chen M, Wang J (2002) Initiator caspases in apoptosis signaling pathways. *Apoptosis* 7: 313-319.
17. Kinouchi S (2003) Changes in Apoptosis-Related Genes (*Bcl-2*, *Bax*) in the Urethras of Old Female Rats Following Estrogen Replacement. *Yonago Acta medica* 46:109-115
18. Hockenbery DM, Oltvai ZN, Yin XM, Milliman CL, Korsmeyer SJ (1993) *Bcl-2* functions in an antioxidant pathway to prevent apoptosis. *Cell* 75: 241-251.
19. Kane DJ, Sarafian TA, Anton R, Hahn H, Gralla EB, et al. (1993) *Bcl-2* inhibition of neural death: decreased generation of reactive oxygen species. *Science* 262: 1274-1277.
20. Heikal TM, Mossa ATH, Nawwar GAM, El-Sherbiny M, Ghanem HZ (2012) Protective Effect of a Synthetic Antioxidant "Acetyl Gallate Derivative" Against Dimethoate Induced DNA Damage and Oxidant/Antioxidant Status in Male Rats. *J Environ Anal Toxicol* 2:155
21. Esterbauer H, Cheeseman KH (1990) Determination of aldehydic lipid peroxidation products: malonaldehyde and 4-hydroxynonenal. *Methods Enzymol* 186: 407-421.
22. BEUTLER E, DURON O, KELLY BM (1963) Improved method for the determination of blood glutathione. *J Lab Clin Med* 61: 882-888.
23. Xu JB, Yuan XF, Lang PZ (1997) The determination of enzymic activity and its inhibition on catalase by ultraviolet spectrophotometry. *Chinese Environ Chem* 16: 73-76
24. Misra HP, Fridovich I (1972) The role of superoxide anion in the autoxidation of epinephrine and a simple assay for superoxide dismutase. *J Biol Chem* 247: 3170-3175.
25. Habig WH, Pabst MJ, Jakoby WB (1974) Glutathione S-transferases. The first enzymatic step in mercapturic acid formation. *J Biol Chem* 249: 7130-7139.
26. LOWRY OH, ROSEBROUGH NJ, FARR AL, RANDALL RJ (1951) Protein measurement with the Folin phenol reagent. *J Biol Chem* 193: 265-275.
27. Lu T, Xu Y, Mericle MT, Mellgren RL (2002) Participation of the conventional calpains in apoptosis. *Biochim Biophys Acta* 1590: 16-26.
28. Ali FK, El-Shafai SA, Samhan FA, Khalil WKB (2008) Effect of water pollution on expression of immune response genes of *Solea aegyptiaca* in Lake Qarun. *Afr J Biotechnol* 7: 1418-1425
29. Bancroft GD, Stevens A, Turner DR (1996) *Theory and practice of technique*. 4th ed. New York: Churchill Livingstone.
30. Clavel J (2007) Progress in the epidemiological understanding of gene-environment interactions in major diseases: cancer. *C R Biol* 330: 306-317.
31. Khalil WK, Booles HF (2011) Protective role of selenium against over-expression of cancer-related apoptotic genes induced by o-cresol in rats. *Arh Hig Rada Toksikol* 62: 121-129.

32. Bonatti S, Bolognesi C, Degan P, Abbondandolo A (1994) Genotoxic effects of the carbamate insecticide methomyl. I. In vitro studies with pure compound and the technical formulation "Lannate 25". *Environ Mol Mutagen* 23: 306-311.
33. Lander BF, Knudsen LE, Gamborg MO, Järventaus H, Norppa H (2000) Chromosome aberrations in pesticide-exposed greenhouse workers. *Scand J Work Environ Health* 26: 436-442.
34. Sun Y (1990) Free radicals, antioxidant enzymes, and carcinogenesis. *Free Radic Biol Med* 8: 583-599.
35. Farber JL (1994) Mechanisms of cell injury by activated oxygen species. *Environ Health Perspect* 102 Suppl 10: 17-24.
36. Venkatesh S, Deecaraman M, Kumar R, Shamsi MB, Dada R (2009) Role of reactive oxygen species in the pathogenesis of mitochondrial DNA (mtDNA) mutations in male infertility. *Indian J Med Res* 129: 127-137.
37. Mossa ATH, Heikal TM, Omara EA (2012) Physiological and histopathological changes in the liver of male rats exposed to paracetamol and diazinon. *Asian Pacific J Tropical Biomed* 12: S1683-S1690.
38. Pant N, Prasad AK, Srivastava SC, Shankar R, Srivastava SP (1995) Effect of oral administration of carbofuran on male reproductive system of rat. *Hum Exp Toxicol* 14: 889-894.
39. Sies H, Cadenas E (1985) Oxidative stress: damage to intact cells and organs. *Philos Trans R Soc Lond B Biol Sci* 311: 617-631.
40. Frei B (1994) Reactive oxygen species and antioxidant vitamins: mechanisms of action. *Am J Med* 97: 5S-13S.
41. Dirican EK, Kalender Y (2012) Dichlorvos-induced testicular toxicity in male rats and the protective role of vitamins C and E. *Exp Toxicol Pathol* 64: 821-830.
42. Aboul-Soud MA, Al-Othman AM, El-Desoky GE, Al-Othman ZA, Yusuf K, et al. (2011) Hepatoprotective effects of vitamin E/selenium against malathion-induced injuries on the antioxidant status and apoptosis-related gene expression in rats. *J Toxicol Sci* 36: 285-296.