

# Pulp Prognosis of Crown-Related Fractures, in Relation to Presence of Luxation Injury and Root Development Stage

Didem Atabek, Alev Alacam, Itir Aydintug, İlknur Baldag

Department of Pedodontics, Faculty of Dentistry, Gazi University, Ankara, Turkey

## Abstract

**Aim:** The aim of this study was to evaluate the prognosis of crown-related fractures with/without luxation injury in relation to the root development stage and referral time for treatment. **Material and Methods:** This retrospective study was carried out on 37 complicated and 69 uncomplicated crown fractured teeth in 75 patients referred to the Department of Pedodontics of Gazi University in Ankara, Turkey. The records of cases were examined for the following: age, sex, teeth number, trauma type, time elapsed following injury, accompanying trauma type, treatment and prognosis. The data were analyzed using the chi-square or binomial tests, and a  $p < 0.05$  was considered statistically significant. **Results:** The dental trauma records of patients with an average age of 10 years, including 75 patients with 37 complicated (34.9%) and 69 uncomplicated crown-fractured teeth (65.1%), were evaluated. The most commonly affected teeth were the maxillary right central incisors (46.2%). Only 16 patients (43.2%) with complicated crown fractures were referred to the clinic within the same day of the injury, whereas the number for uncomplicated crown fractures was 24 patients (34.7%) For uncomplicated crown fractures referred to the clinic after 1 week, increased vitality loss was seen. Depending on the accompanying trauma type and the time elapsed after trauma; the prognosis of the cases (even uncomplicated crown fractures) was affected negatively. **Conclusions:** It was concluded that even simple crown fractures with open apices may end up with inflammation or pulp necrosis because of late referral besides accompanying trauma.

*Key Words:* Crown-fracture, Root, luxation-injury

## Introduction

Traumatic dental injuries (TDIs) occur with great frequency in preschool, school-age children, and young adults [1]. Luxation injuries are the most common TDIs in primary dentition, whereas crown fractures are more commonly reported for the permanent dentition [2]. A crown fracture is defined as a type of traumatic injury in which a portion of tooth enamel is lost following a perpendicular or obliquely directed impact force to the tooth's incisal edge. In literature, the term "uncomplicated" is used to refer to enamel and enamel-dentin fractures of the teeth, whereas "complicated" defines the enamel-dentin-pulp fractures [3]. Whether it is an "uncomplicated" or "complicated" fracture, immediate treatment of a crown-related fractured tooth is the most important factor for preserving pulp vitality [4]. In addition, pulp healing can also be affected by the disruption of blood supply at the apical foramen. The extent of the damage to the blood and nerve supply to the pulp depends on the severity of the luxation injury [5]. There are few published data about pulp survival when crown fractures are accompanied by luxation injuries [5–7]. Moreover, due to the teeth's healing potential, the stage of root development has been found to influence the risk of pulp vitality loss [8]. In combined traumatic injuries, all of these factors should therefore also be taken into consideration when assessing the pulp prognosis.

The aim of the present study was to evaluate the pulp vitality survival following a crown-related fracture with and without an accompanying luxation injury in relation to the stage of root development and referral time for treatment.

## Material and Methods

This retrospective study was carried out on 37 complicated and 68 uncomplicated crown-fractured teeth in 75 patients referred to the Department of Pedodontics of Gazi University

in Ankara. The records of cases were examined for the following: age, sex, teeth number, trauma type, time elapsed following injury, accompanying trauma type, stage of root development, treatment, and the preservation of pulp vitality defined as a "negative" or "positive" prognosis. The treatment strategy was dependent upon the referral time for treatment, the extent of the accompanying luxation injury, pulpal involvement, and the stage of root development. The observation period ranged from a minimum of 6 months to 3 years. Pulp vitality survival was diagnosed if two of the clinical signs were present (I. Grey crown discoloration, II. (-) Electrical pulp test, III. Periapical radiolucency.)

The data were analyzed using the chi-square or binomial tests, and a  $p < 0.05$  was considered statistically significant.

## Results

The demographic distribution of the cases is shown in Table 1. Dental trauma records of 106 crown-fractured permanent teeth of 75 patients (25 girls (33.3 %) and 50 boys (66.67 %) were evaluated. The patients were between 7 and 15 years of age, with a peak in the age interval of 9–10 years. The total number of uncomplicated crown-fractured (UCF) teeth was 68 (64.7 %), whereas the number for complicated crown-fractured (CCF) teeth was 37 (35.2 %). When we evaluated the referral time for treatment, we observed that 51.47% of the UCF teeth was referred to the clinic on the day of injury, whereas the percentage was 45.95% for the CCF teeth.

Considering the root development stage, in the UCF group, 30.88% of the teeth were with open apices, and 69.12% were with closed apices. For the CCF group, while 35.14% of the teeth were with open apices, 64.86% of teeth were with closed apices.

Accompanying luxation injuries were detected with a percentage of 17.6% for the UCF teeth and 18.9% for the CCF

teeth. The preservation of pulp vitality is based on the referral time, root development stage and the presence of luxation injuries.

For UCFs with open apices, which were treated on the day of injury, the pulp vitality was protected whether or not related to luxation injuries. On the other hand, the pulp vitality of the

UCF cases accompanied by luxation injuries were affected negatively when the apices were closed (85.7%) ( $p < 0.05$ ) (Figure 1). In the cases of CCF teeth with open apices, the preservation of the pulp vitality was affected negatively in the presence of luxation injuries ( $p > 0.05$ ) (Figure 2).

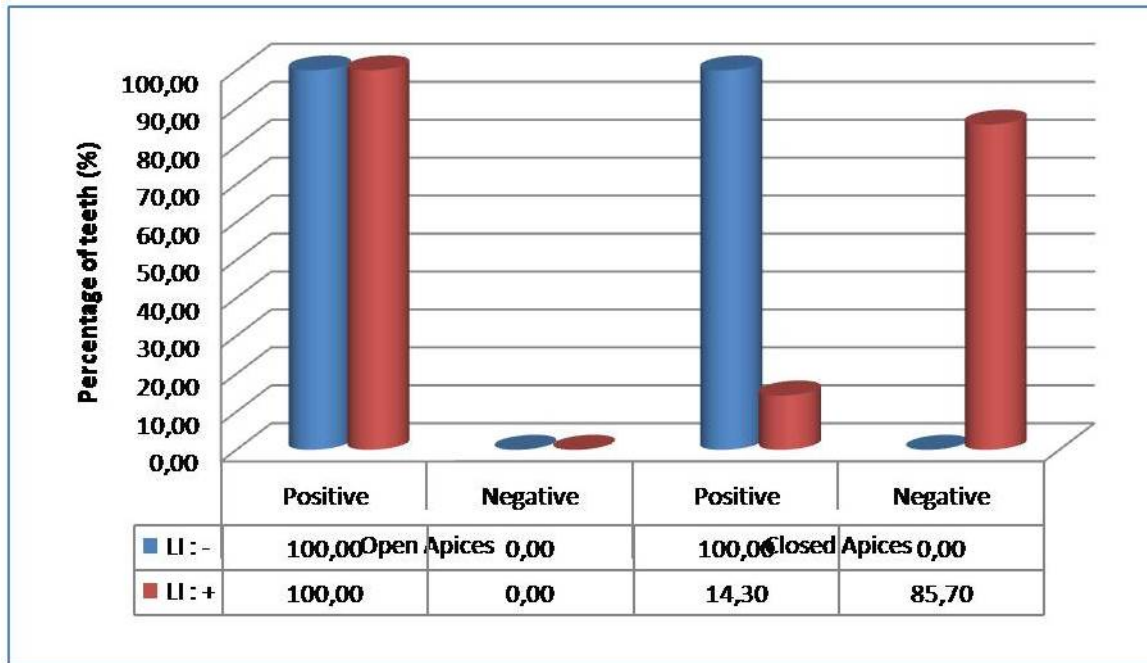


Figure 1. Pulp vitality preservation of UCFs treated on the day of injury. UCFs: Uncomplicated crown fractures; Positive: Positive pulp vitality survival; Negative: Negative pulp vitality survival; LI-: Absence of luxation injury (Blue Charts); LI+: Presence of luxation injury (Red Charts).

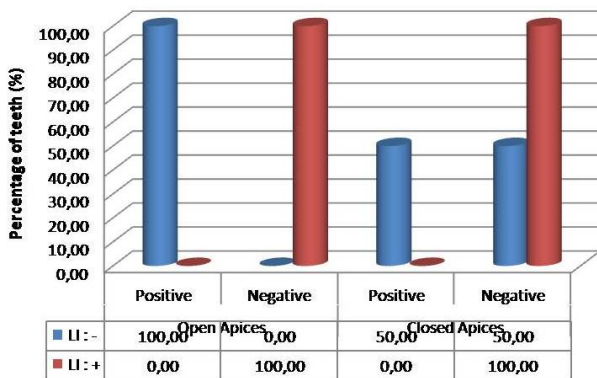


Figure 2. Pulp vitality preservation of CCFs treated on the day of injury. CCFs: Complicated crown fractures; Positive: Positive pulp vitality survival; Negative: Negative pulp vitality survival; LI-: Absence of luxation injury (Blue Charts); LI+: Presence of luxation injury (Red Charts).

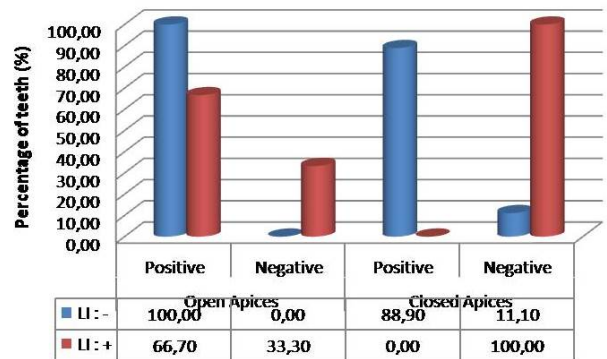
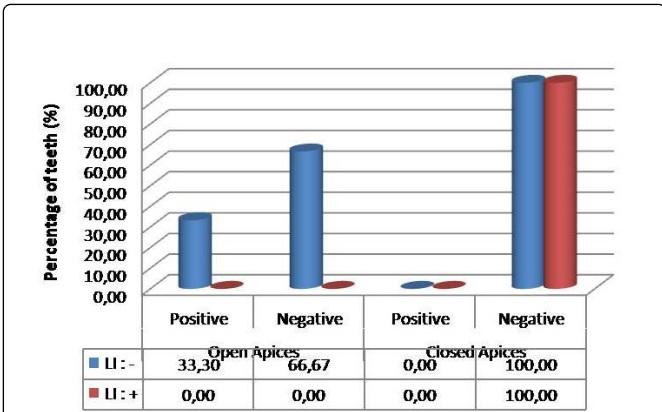


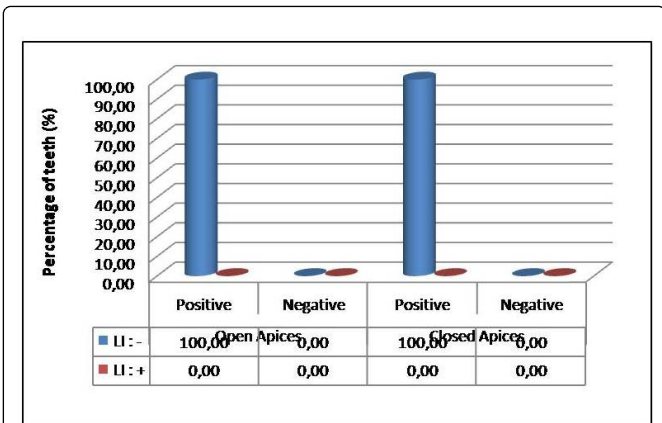
Figure 3. Pulp vitality preservation, UCFs treated within a week. UCFs: Uncomplicated crown fractures; Positive: Positive pulp vitality survival; Negative: Negative pulp vitality survival; LI-: Absence of luxation injury (Blue Charts); LI+: Presence of luxation injury (Red Charts).

For both UCF and CCF teeth with open apices, which were treated within a week, the pulp vitality was preserved mostly in the absence of luxation injuries ( $p > 0.05$ ) (Figures 3 and 4).

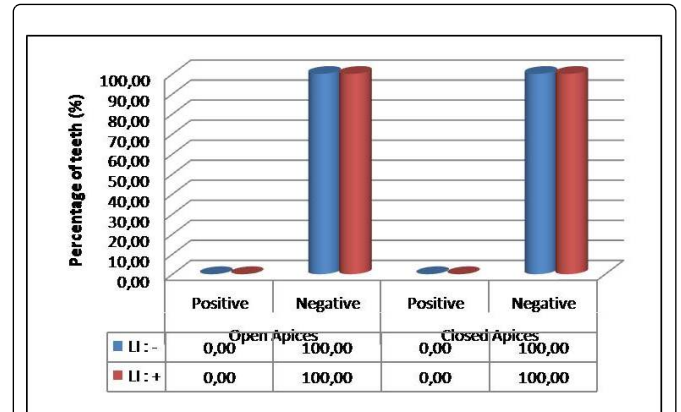


**Figure 4.** Pulp vitality preservation, CCFs treated within a week. CCFs: Complicated crown fractures; Positive: Positive pulp vitality survival; Negative: Negative pulp vitality survival; LI-: Absence of luxation injury (Blue Charts); LI+: Presence of luxation injury (Red Charts).

In the cases of UCFs with both open and closed apices, which were treated within the time interval of 1 week–1 month, the pulp vitality was preserved in the absence of luxation injuries ( $p>0.05$ ) (Figure 5), while for CCFs, the pulp vitality could not be preserved independently of the presence of luxation injuries and the root development stage (Figure 6).



**Figure 5.** Pulp vitality preservation, UCFs treated within a week-1 month. UCFs: Uncomplicated crown fractures; Positive: Positive pulp vitality survival; Negative: Negative pulp vitality survival; LI-: Absence of luxation injury (Blue Charts); LI+: Presence of luxation injury (Red Charts).



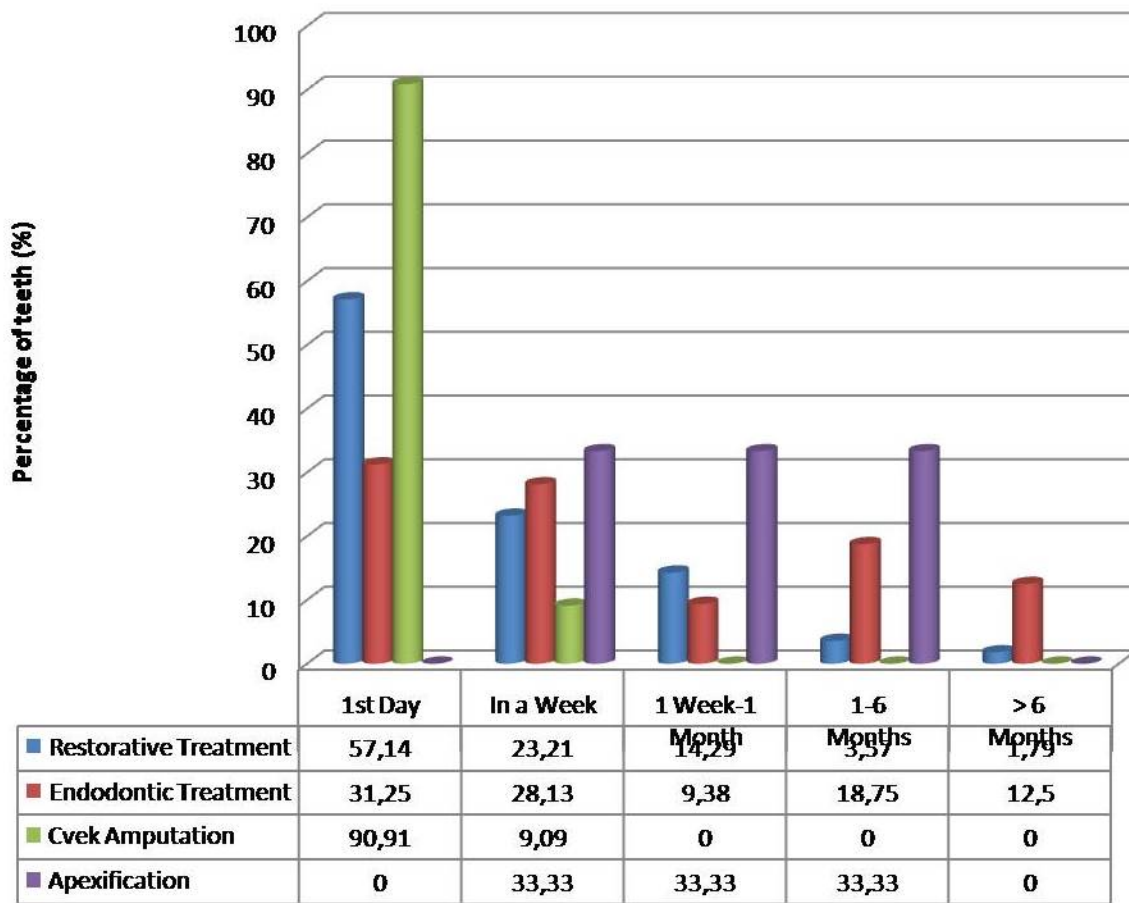
**Figure 6.** Pulp vitality preservation, CCFs treated within a week-1 month. CCFs: Complicated crown fractures; Positive: Positive pulp vitality survival; Negative: Negative pulp vitality survival; LI-: Absence of luxation injury (Blue Charts); LI+: Presence of luxation injury (Red Charts).

In late referrals, increased failure to maintain pulp vitality was observed, and the percentage of apexification processes increased in connection with the age of the patients (Figure 7).

## Discussion

Previous studies have shown that crown fractures account for the highest percentage of all traumatic injuries in permanent dentition [9-11]. In this regard demographic, retrospective, prognostic many studies are available in the literature [12]. On the other hand, very limited information is available on the risk of pulp vitality loss and especially on factors related to this complication following the fracture. The prognosis of pulp vitality survival varies depending on the time elapsed after trauma, and it is known that early intervention can save the tooth. In addition, the extent of accompanying trauma, as revealed by the luxation injury, is significantly related to pulp vitality survival after injury. The effect of non-diagnosed luxation injuries on the prognosis of crown-fractures emphasizes the need for a complete clinical examination at the time of injury. Also, the stage of root development plays an important role in the risk of pulp vitality loss [13–15].

In this study, the importance of the elapsed time after trauma, root development stage at the time of injury, and the extent of the luxation injury and the combined effects on pulp healing were evaluated for an extended period (up to 3 years).



**Figure 7.** Treatment types' distribution according to the referral time after trauma.

The effect of referral time and subsequent risk of pulp necrosis has been evaluated in a few studies [8,9]. Atabek et al. [10] reported the importance of immediate treatment after trauma on the prognosis of pulp vitality survival. In the present study, whether complicated or uncomplicated, with closed or open apices, the pulp vitality of the cases was not affected negatively when treated on the day of injury. On the other hand, when the elapsed time after trauma is prolonged, the risk of pulp vitality loss increases in agreement with the earlier studies that emphasize the increased rate of root canal treatment of even uncomplicated crown fractures [8-11]. Late referral could have two reasons; firstly, the uncomplicated crown fractures and periodontal injuries may have been neglected on the basis that these kinds of cases have fewer visible symptoms and were thus not recognized by the parents. Secondly, the early referral of complicated crown fractures can be explained by the parents' fear of their children's losing entire teeth [10]. Maybe due to parents' lack of information, a need exists to institute preventive educational programs directed at parents about the fact that whether it is complicated or uncomplicated, immediate treatment of the traumatized tooth is the most important factor for preserving pulp vitality.

In addition, the presence of a luxation injury and the stage of root development should be noted as important prognostic factors of traumatic dental injuries. Robertson et al. [8]

revealed that crown fractures with luxation injuries led to a higher frequency of pulp necrosis. This study's results showed that in the cases of crown fractures, whether complicated or uncomplicated, which were treated within a week, the absence of luxation injuries and the presence of open apices were the determinants of a positive prognosis. This can be explained by the findings of Ravn et al. [13] that luxation injuries concomitant to crown fracture have a greater effect on pulp vitality than pulp exposure. In accordance with the study's findings, the immature teeth have considerable capacity for healing after pulp exposure and luxation injury [12].

In the present study for the cases of UCFs, the absence of luxation injuries again was a critical factor for preserving the pulp vitality of either open or closed apices for longer periods (1week–1 month). In the study of Wang et al. [15], the presence of a luxation injury was found to be a risk factor in pulp necrosis in uncomplicated crown fractures. The frequency of pulp necrosis was higher in UCFs and concomitant luxation (with either closed or open apices) than in those without luxation injuries treated after 24 hours [15].

According to the results of present study, pulp survival was more likely to occur in non-luxated teeth, in accordance with Andreasen's study [16]. Luxation injuries imply more serious injury that may have impacts both on hard tissue and on periodontal tissue, especially in teeth with closed apices. The risk of pulp necrosis in teeth with closed apices was more than

double that of teeth with open apices [2,15-19]. Due to the presence of wide-open apices, the pulp revascularization is facilitated; thereby, the spread of inflammation is prevented, as in the present study [20].

Besides the fact that early intervention saves the tooth, a detailed diagnosis of the root development stage and the presence of luxation injuries can guide the prognosis of pulp survival, clinicians' expectations, and patients' expectations. Although current guidelines can be used in traumatic dental injuries, more standard guidelines are needed to evaluate the combined traumatic injuries, not individually.

## Conclusion

The significant deleterious effect of luxation injuries concomitant to crown-related fractures on pulp survival was established. In addition, the root development stage at the time of injury appeared to also be related to pulp survival in the case of crown-related fractures accompanied by luxation injuries. Whether it is an "uncomplicated" or "complicated" crown fracture, the need for complete clinical and radiographic examination at the time of injury is emphasized for realistic expectations.

## References

1. Diangelis AJ, Andreasen JO, Ebeleseder KA, Kenny DJ, Trope M, et al. International Association of Dental Traumatology. International Association of Dental Traumatology guidelines for the management of traumatic dental injuries: Fractures and luxations of permanent teeth. *Dental Traumatology*. 2012; **28**: 2-12.
2. Andreasen JO, Andreasen FM, Andersson L. Textbook and color atlas of traumatic injuries to the teeth. (4th edn) Oxford, *Wiley-Blackwell*; 2007, United Kingdom.
3. G ng r HC. Management of crown-related fractures in children: an update review. *Dental Traumatology*. 2014; **30**: 88-99.
4. Krastl G, Filippi A, Zitzmann NU, Walter C, Weiger R. Current aspects of restoring traumatically fractured teeth. *European Journal of Esthetic Dentistry*. 2011; **6**: 124-141.
5. Lauridsen E, Hermann NV, Gerds TA, Ahrensburg SS, Kreiborg S, et al. Combination injuries 1. The risk of pulp necrosis in permanent teeth with concussion injuries and concomitant crown fractures. *Dental Traumatology*. 2012; **28**: 364-370.
6. Lauridsen E, Hermann NV, Gerds TA, Ahrensburg SS, Kreiborg S, et al. Combination injuries 2. The risk of pulp necrosis in permanent teeth with subluxation injuries and concomitant crown fractures. *Dental Traumatology*. 2012; **28**: 371-378.
7. Lauridsen E, Hermann NV, Gerds TA, Ahrensburg SS, Kreiborg S, et al. Combination injuries 3. The risk of pulp necrosis in permanent teeth with extrusion or lateral luxation and concomitant crown fractures without pulp exposure. *Dental Traumatology*. 2012; **28**: 379-385.
8. Ravn JJ. Follow-up study of permanent incisors with enamel-dentin fractures after acute trauma. *Scandinavian Journal of Dental Research*. 1981; **89**: 355-365.
9. Robertson A, Andreasen FM, Andreasen JO, Nor n JG. Long-term prognosis of crown-fractured permanent incisors. The effect of stage of root development and associated luxation injury. *International Journal of Paediatric Dentistry*. 2000; **10**: 191-199.
10. Feldens CA, Kramer PF, Feldens EG. Exploring the profile of articles on traumatic dental injuries in pediatric dental journals. *Dental Traumatology*. 2013; **29**: 172-177.
11. Atabek D, Ala am A, Aydintu  I, Konako lu G. A retrospective study of traumatic dental injuries. *Dental Traumatology*. 2014; **30**: 154-161.
12. Olsburgh S, Jacoby T, Krejci I. Crown fractures in the permanent dentition: pulpal and restorative considerations. *Dental Traumatology*. 2002; **18**: 103-115.
13. Glendor U. Aetiology and risk factors related to traumatic dental injuries-a review of the literature. *Dental Traumatology*. 2009; **25**: 19-31.
14. Ravn JJ. Follow-up study of permanent incisors with enamel-dentin fractures after acute trauma. *Scandinavian Journal of Dental Research*. 1981; **89**: 355-365.
15. Witherspoon DE. Vital pulp therapy with new materials: new directions and treatment perspectives--permanent teeth. *Pediatric Dentistry*. 2008; **30**: 220-224.
16. Wang C, Qin M, Guan Y. Analysis of pulp prognosis in 603 permanent teeth with uncomplicated crown fracture with or without luxation. *Dental Traumatology*. 2014; **30**: 333-337.
17. Andreasen JO, Andreasen FM. Textbook and color atlas of traumatic injuries to the teeth, (3rd edn.) Copenhagen: *Munksgaard Publishers*; 1993.
18. Robertson A. A retrospective evaluation of patients with uncomplicated crown fractures and luxation injuries. *Endodontics and Dental Traumatology*. 1998; **14**: 245-256.
19. Andreasen FM, Pedersen BV. Prognosis of luxated permanent teeth the development of pulp necrosis. *Endodontics and Dental Traumatology*. 1985; **1**: 207-220.
20. Andreasen FM, Andreasen JO. Diagnosis of luxation injuries: the importance of standardized clinical, radiographic and photographic techniques in clinical investigations. *Endodontics and Dental Traumatology*. 1985; **1**: 160-169.