

Radiographic Examination to Detect Radiolucency Lesion

Samer Shahrour*

Al-Ba'ath University, Syria

*Corresponding author: Dr. Samer Shahrour, Consultant Oral & Maxillofacial Surgeon, Al-Ba'ath University, Syria, Tel: +963933317123, E-mail: samersh@gmail.com

Received date: September 21, 2015, Accepted date: September 29, 2015, Published date: October 03, 2015

Copyright: © 2015 Shahrour S. This is an open-access article distributed under the terms of the Creative Commons Attribution License, which permits unrestricted use, distribution, and reproduction in any medium, provided the original author and source are credited.

Clinical Image

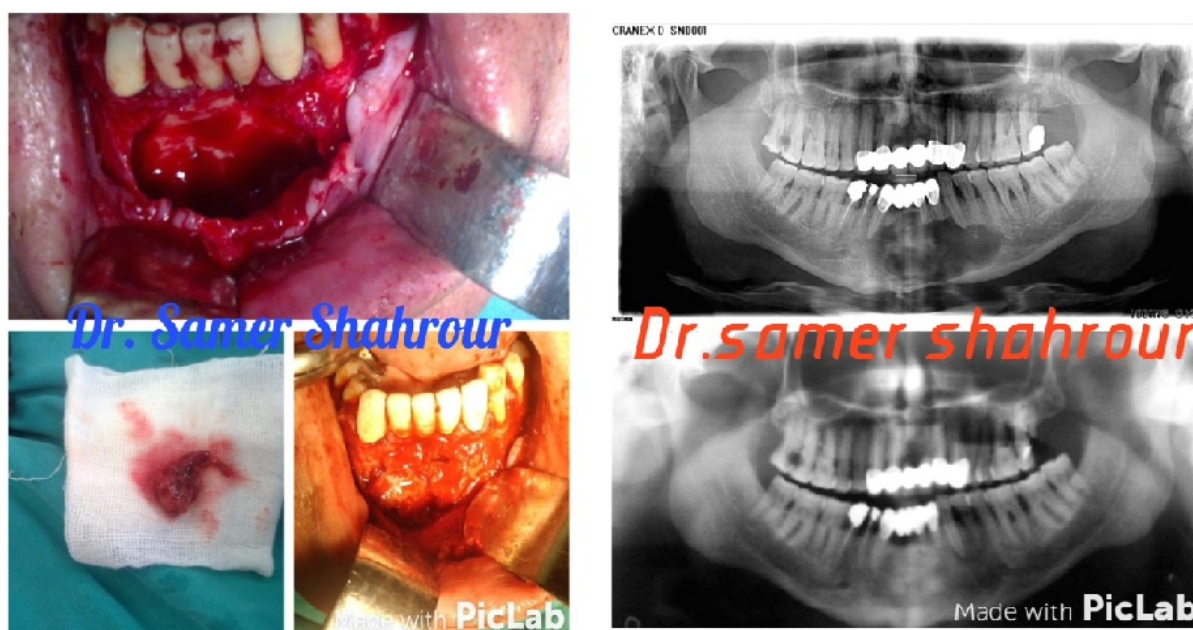


Figure 1: A healthy 52-year-old man was referred from his dentist for numbness in his lower lip, radiographic examination reveals a huge radiolucency lesion from 35 to 43. Surgical intervention was performed under general anesthesia via an intra-oral approach. The lesion was enucleated and an auto bone graft was harvested. Biopsy was sent, the report "Odontogenic cyst".