

## Recurrent Bilateral Orbital Infiltration as Primary Manifestation of Rosai Dorfman Disease

Pustina B<sup>1\*</sup>, Saliu N<sup>1</sup>, Rroji A<sup>2</sup>, Kaloshi G<sup>2</sup> and Petrela M<sup>2</sup>

<sup>1</sup>Department of Ophthalmology, University Clinical Center of Kosovo, Prishtina, Kosovo, Albania

<sup>2</sup>Department of Neurosurgery, University Hospital Center "Mother Theresa", Tirana, Albania

### Abstract

Rosai Dorfman disease also known as histiocytosis with massive lymphadenopathy is a very rare idiopathic disease. It is characterized by over production and accumulation of non-Langerhans sinus histiocyte most often in lymph nodes, but may occur in other areas leading to organ damage. Based on the research it can be caused by an infectious agent, immunodeficiency or autoimmunity and genetic causes. Extranodal manifestation is uncommon; however extranodal sites include liver, kidney, respiratory organs, orbit and eyeball. We present a case report of a 44-year-old female with recurrent bilateral orbital infiltration as first location of Rosai Dorfman disease.

**Keywords:** Extranodal rosai dorfman; Genetic; Immunodeficiency; Histiocytosis with massive lymphadenopathy; Orbit; Kidney

### Introduction

Rosai Dorfman disease is an uncommon histiocytic disorder first described by Rosai and Dorfman in 1969 as sinus histiocytosis with massive lymphadenopathy [1]. The disease is usually chronic with spontaneous remission and is refractory to treatment [2]. Rosai-Dorfman does not usually threaten life or organ function. It is believed that 5% to 10% of patients have progressive disease that may damage tissue. However, for most patients, the disease is self-limited, and the outcome is good. Diagnosis of Rosai Dorfman disease is by histopathologic tests and special tests result show histiocytes positive staining for CD68 and S-100 in Rosai Dorfman disease. CD1A is negative. Langerhans cell histiocytosis, Reticulohistiocytoma and Juvenile xanthogranuloma are listed in differential diagnosis [3,4]. Based on the literature there are no large studies performed and many of the patients do not require treatment.

### Differential diagnosis of Rosai-Dorfman disease

There are other diseases that can be manifested with histiocytosis and should not be misdiagnose with Rosai Dorfman disease. Juvenile xanthogranuloma, reticulohistiocytoma and langerhans cell histiocytosis are some of them [1]. In Rosai Dorfman disease CD68 and S100 are positive, and CD1A is negative. In order to set proper diagnosis, we have to exclude these immunohistochemical studies in other diseases. Characteristic "ground cell" cytoplasm are seen in reticulohistiocytoma and "touton" giant cells with lipidisation of hystiocytes in juvenile xanthogranuloma. These other diseases should not display emperipolesis [4]. Rosai Dorfman disease in kidneys is very rare and as differential diagnosis we should exclude malignant fibrous hystiocytomas, leukemia, lymphoma, tuberculosis or renal carcinoma [5,6].

### Case Report

A 45-year-old female was referred to our clinic with signs of pansinusitis, pain in the right orbit and diplopic vision when she turned the eyes to the right position. In the CT of the head orbital lesion was noticed (Figure 1). After the surgery was performed a capsulated non-hemorrhagic lesion with hard consistence was removed. Surgery resolved above symptoms and no complication was observed. After 4 months regression of the clinical signs with pain appeared in the left eye. She also had proptosis and blurred vision. MRI findings showed lesion in left orbit and left cavernous sinusitis, also frontal lesion. It was suspected for lymphoma in differential diagnosis. Laboratory

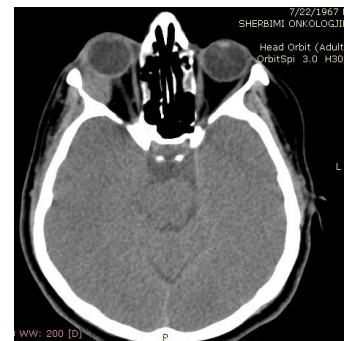


Figure 1: CT scan showing an isodense lesion at lateral part of right orbit.

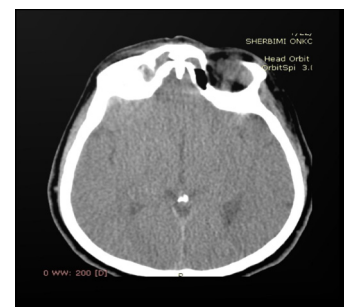


Figure 2: CT scan after the left orbital tumor removed.

examinations revealed: RBC  $3.65 \times 10^6/\text{mm}^3$  HGB 10.6 g/dL, HCT 34.5. The second surgery was performed in left orbit (Figure 2). Capsulated, hard mass was removed. Second biopsy was done and in the conclusion, it resulted with non-specific granular inflammation.

**\*Corresponding author:** Dr. Belinda Pustina, Department of Ophthalmology, University Clinical Center of Kosovo, Prishtina, Kosovo, Albania, Tel: +381-38-500600; E-mail: [belindapustina@gmail.com](mailto:belindapustina@gmail.com)

Received July 09, 2017; Accepted July 19, 2017; Published July 24, 2017

**Citation:** Pustina B, Saliu N, Rroji A, Kaloshi G, Petrela M (2017) Recurrent Bilateral Orbital Infiltration as Primary Manifestation of Rosai Dorfman Disease. J Mol Genet Med 11: 276 doi:[10.4172/1747-0862.1000276](https://doi.org/10.4172/1747-0862.1000276)

**Copyright:** © 2017 Pustina B, et al. This is an open-access article distributed under the terms of the Creative Commons Attribution License, which permits unrestricted use, distribution, and reproduction in any medium, provided the original author and source are credited

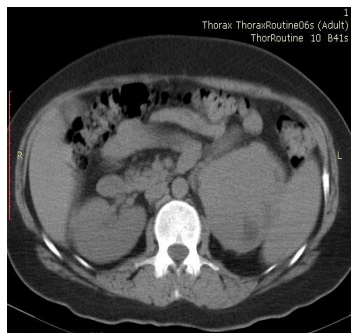


Figure 3: Extra-orbital lesion in left kidney.

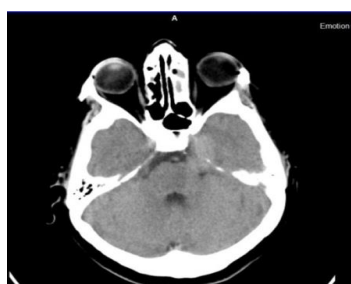

Figure 4: Orbits after surgery and medical treatment.

Immunohistochemistry (IHC) was positive for CD 68+, S 100+, CD 38+ in plasmatic cells, CD 45, CD 5, CD 3 stained mature lymphocytes and negative for HMB 45-.

## Discussion

The diagnosis was extranodular Rosai Dorfman Disease. After

two years proptosis in both eyes was noticed with the recurrence of the disease in both orbits. Total removal of the tumor was done by surgery in both orbits. This time patient had symptoms of pain in kidney and laboratory examination revealed high urea [Urea=52.2 g/24 hours]. Immediately the kidney CT was performed and it resulted with infiltrative renal mass in the left kidney (Figure 3). She was treated with corticosteroids and oral methotrexate. The follow up CT resulted negative for recurrence and total disappearing of the lesion from the orbits and head (Figure 4).

## Conclusion

Extranodal orbital Rosai Dorfman disease is a very rare condition. Furthermore, bilateral orbital infiltration as first sign of the disease as in our case is even rarer. For that reason, this case should raise the awareness among ophthalmologists and it should be considered in differential diagnosis for orbital tumors.

## References

1. Rosai J, Dorfman RF (1969) Sinus histiocytosis with massive lymphadenopathy: A newly recognized benign clinicopathological entity. *Arch Pathol* 87: 63-70.
2. Wu SY, Ma L, Tsai YJ (2004) Partial removal of orbital tumor in Rosai-Dorfman disease. *Jpn J Ophthalmol* 48: 154-157.
3. Brenn T, Calonje E, Granter SR, Leonard N, Grayson W, et al. (2002) Cutaneous Rosai-Dorfman disease is a distinct clinical entity. *Am J Dermatopathol* 24: 385-391.
4. Kuo TT, Chen TC, Lee LY, Lu PH (2009) IgG4-positive plasma cells in cutaneous Rosai-Dorfman disease: An additional immunohistochemical feature and possible relationship to IgG4-related sclerosing disease. *J Cutan Pathol* 36: 1069-1073.
5. Weiss SW, Goldblum JR, Enzinger FM (2001) *Enzinger and Weiss soft tissue tumors*. (4th edn). XIV. Mosby, St. Louis, M. Missouri, USA.
6. Galindo R, Sanchez H (2004) Extra nodal Rosai-Dorfman disease in children. *J Pediatr Hematol Oncol* 26: 19-24.