

## Relationship of Fragmented Wide QRS Complexes with Coronary Atherosclerosis in Patients with Left Bundle Branch Block

Nermin Bayar<sup>1\*</sup>, Goksel Cagirci<sup>1</sup>, Serkan Cay<sup>2</sup>, Zehra Erkal<sup>1</sup>, Isa Oner Yuksel<sup>1</sup>, Erkan Koklu<sup>1</sup>, Gorkem Kus<sup>1</sup> and Sakir Arslan<sup>1</sup>

<sup>1</sup>Antalya Education and Research Hospital, Antalya, Turkey

<sup>2</sup>Yuksekk Ihtisas Education and Research Hospital, Ankara, Turkey

\*Corresponding author: Nermin Bayar, Antalya Education and Research Hospital, Asset Mah. Kazim Karabekir Cad Cold, Antalya, Turkey, Tel: +90 242 2494400; E-mail: [dr.nermin@mynet.com](mailto:dr.nermin@mynet.com)

Rec date: Feb 28, 2014, Acc date: May 05, 2014, Pub date: May 15, 2014

Copyright: © 2014 Bayar N, et al. This is an open-access article distributed under the terms of the Creative Commons Attribution License, which permits unrestricted use, distribution, and reproduction in any medium, provided the original author and source are credited.

### Abstract

**Objective:** The non-invasive tests used in the diagnosis of Coronary Artery Disease (CAD) in patients with Left Bundle Branch Block (LBBB) are of limited use. The aim of this study is to investigate the relationship between the presence of Fragmented wide QRS [f-wQRS] and coronary atherosclerosis in patients with LBBB.

**Methods:** This retrospective study included 75 patients who were admitted to our clinic with exertional chest pain and LBBB on electrocardiography and for whom it was decided to obtain coronary angiography as a result of clinical evaluation or positive scintigraphic results. The presence of f-wQRS was investigated in patients' electrocardiography prior to coronary angiography. Gensini score was calculated by examining the patients' coronary angiography records. Patient who had 75% and more stenosis in at least one coronary artery was defined as an obstructive CAD.

**Results:** Thirty-nine patients had obstructive CAD. Gensini score was higher in the group with obstructive CAD [34.0 and 6.3, respectively,  $p < 0.001$ ]. Significant difference was found between the patients with obstructive CAD and patients without obstructive CAD for the presence of f-wQRS [82.1% and 8.3%, respectively,  $p < 0.001$ ]. Gensini score was found to be higher in patients with f-wQRS compared to without f-wQRS [34.0 and 7.0,  $p < 0.001$ , respectively].

**Conclusion:** In our study, the presence of f-wQRS in patients with LBBB was associated with the presence and severity of obstructive CAD. In this patient group, searching for f-wQRS on surface electrocardiography can be considered as a new risk factor associated with CAD due to its easy evaluation, being an inexpensive and non-invasive method.

**Keywords:** Bundle branch block; Coronary disease; Electrocardiography

QRS [f-wQRS] on surface ECG and the presence and extent of obstructive CAD in patients with LBBB.

### Abbreviations:

CAD: Coronary Artery Disease; LBBB: Left Bundle Branch Block; RBBB: Right Bundle Branch Block; F-Wqrs: Fragmented Wide QRS Complex; MI: Myocardial Infarction; MPS: Myocardial Perfusion Scintigraphy

### Introduction

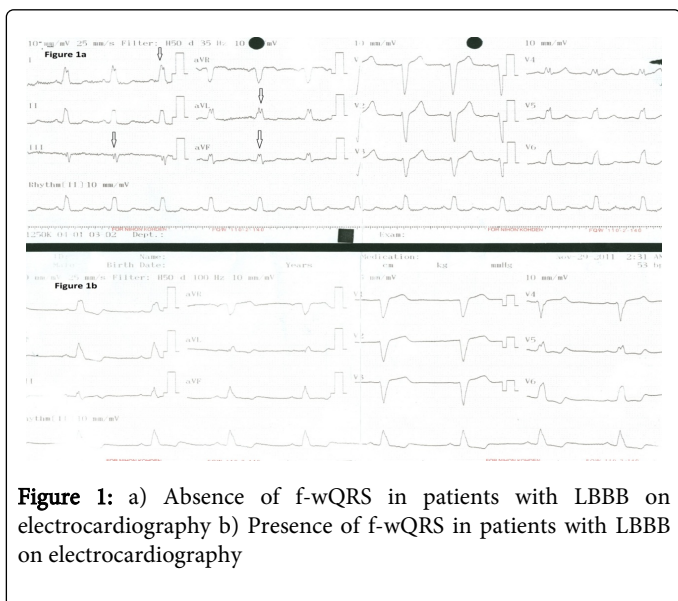
The probability of developing Coronary Artery Disease (CAD) is high in patients with Left Bundle Branch Block (LBBB) [1,2]. However, investigating CAD in patients with LBBB presents some difficulties. An exercise electrocardiography, which is a non-diagnostic test, is not recommended for these patients; myocardial perfusion scintigraphy is also of limited use due to its high cost, its absence in some centres and because of the false-negative results that are often encountered. Recent studies have reported that the presence of fragmented QRS complex on surface Electrocardiography (ECG) is related to ischemia, scarring or fibrosis [3-7]. This study was designed to evaluate the relationship between the presence of Fragmented wide

### Methods

This retrospective study included 75 patients who were admitted to our clinic with exertional chest pain and LBBB on electrocardiography and for whom it was decided to obtain coronary angiography as a result of clinical evaluation or positive scintigraphic results between January 2010 and June 2013. Patients with documented myocardial infarction or with acute coronary syndrome were excluded. Transthoracic echocardiography recordings were examined before coronary angiography and patients with moderate-to-severe valve disease and/or structural heart disease were excluded. Patient files were reviewed and patients with diagnosis of collagen vascular disease were excluded owing to association with f-wQRS.

The presence of f-wQRS was investigated in patients' 12 lead surface ECG [Nihon Kohden-Cardiofax S ECG-1250 K, filter range 0.5 Hz to 150 Hz, AC filter 60 Hz, 25 mm/s, 10 mm/mV] prior to coronary angiography. In the presence of wide QRS, the diagnosis of fragmented QRS was reached when the QRS complex was 120 ms and higher in duration, and in the presence of more than two notches in the R or the

S wave on at least two adjacent inferior [D2, D3, aVF], lateral [D1,aVL,V6] or anterior [V1-V5] derivations (Figure 1a and b).



**Figure 1:** a) Absence of f-wQRS in patients with LBBB on electrocardiography b) Presence of f-wQRS in patients with LBBB on electrocardiography

All patients' coronary angiography records were examined. Seventy five percent and more stenosis in at least one coronary artery was defined as an obstructive CAD. Gensini scores were also calculated to assess the severity of CAD [8-10]. The association between the presence of f-wQRS and Gensini score was evaluated in groups with and without obstructive CAD. Gensini score of 20 or over was recognized as severe CAD. The relationship between f-wQRS and vascular lesions was also analysed.

### Statistical Analysis

Data were analysed with the SPSS software version 15.0 for Windows [SPSS Inc., Chicago, IL, USA]. Categorical variables were presented as frequency and percentage. The  $\chi^2$  test and Fisher's exact test were used to compare categorical variables. The Kolmogorov-Smirnov test was used to assess the distribution of continuous variables. Student's t-test was used for variables with normal distribution and the values were presented as mean  $\pm$  SD. Continuous variables without normal distribution were analysed using Mann-Whitney U test and obtained values were presented as median [50th] values and interquartile ranges [25th and 75th]. Multivariate logistic regression analysis was used to evaluate the independent associates of the risk of CAD and severe CAD. Parameters with a p-value of less than 0.1 in univariate analysis were included in the model. The odds ratios [or] and 95% Confidence Intervals (CI) were calculated. A two-tailed p-value of <0.05 was considered statistically significant.

### Results

We evaluated 75 patients with LBBB on electrocardiography. In our study, there was no significant difference among gender, diabetes mellitus, hypertension, smoking and left ventricular ejection fraction in patients with obstructive CAD and without obstructive CAD. Mean Gensini score was higher in group with obstructive CAD [34.0(20.5 – 42.0) and 6.3(4.0 – 8.5), respectively,  $p < 0.001$ ]. There was a significant difference of age between groups with obstructive CAD and without CAD [ $p = 0.001$ ] (Table 1).

Variables	Obstructive CAD + (n=39)	Obstructive CAD - (n=36)	P value
Age, years	67.0 $\pm$ 10.4	56.1 $\pm$ 17.2	0.001
Male gender, n (%)	22 (56.4%)	15 (41.7%)	0.251
DM, n (%)	16 (41.0%)	10 (27.8%)	0.332
HT, n (%)	24 (61.5%)	15 (41.7%)	0.108
Smoking, n (%)	15 (38.5%)	9 (25.0%)	0.228
HL, n (%)	12 (30.8%)	8 (22.2%)	0.444
Gensini score	34.0 (20.5 – 42.0)	6.3 (4.0 – 8.5)	<0.001
LV EF, %	55.0 (48.0 – 58.0)	56.3 (41.3 – 60.0)	0.805

**Table 1:** Demographic characteristics of patients

Normal distribution mean  $\pm$  SD, not show a normal distribution median (25 vs. 75 percentile) DM: Diabetes mellitus; HT: Hypertension; HL: Hyperlipidemia; LVEF: Left ventricular ejection fraction

Significant difference was found between the groups with obstructive CAD and without obstructive CAD for the presence of f-wQRS [82.1% and 8.3%, respectively,  $p < 0.001$ ]. The presence of f-wQRS in patients with LBBB for documenting obstructive CAD was found to have 82.1% sensitivity and 91.7% specificity. F-wQRS was observed 74.4% in inferior leads, 38.5% in lateral leads, 2.6% in anterior leads in patients with obstructive CAD. Furthermore, more frequent f-wQRS was observed in the inferior and lateral leads in these patients compared to non-obstructive CAD (Table 2).

Variables	Obstructive CAD+ (n=39)	Obstructive CAD- (n=36)	P value
Presence of f-wQRS, n (%)	32 (82.1%)	3 (8.3%)	<0.001
Localization of f-wQRS			
Inferior leads, n (%)	29 (74.4%)	1 (2.8%)	<0.001
Lateral leads, n (%)	15 (38.5%)	2 (5.6%)	0.001
Anterior leads, n (%)	1 (2.6%)	0 (0%)	1.000

**Table 2:** The relationship between the presence of obstructive CAD and the presence and localization of f-wQRS

	Presence of f-wQRS (n=35)	Absence of f-wQRS (n=40)	P value
Gensini score, mean	34 (16.0 – 42.0)	7 (4.3 – 11.0)	<0.001

**Table 3:** The Relationship between Gensini score and presence of fQRS

Patients with obstructive CAD had 38.5% single vessel, 46.2% two vessels, 15.3% three vessels disease. Of these patients, 79.5% Left Anterior Descending Artery (LAD), 51.3% Circumflex Artery (CX), 48.7% Right Coronary Artery (RCA) lesions were detected. No significant association was found between the localization of f-wQRS

and coronary lesion localization. Gensini score was found to be higher in patients with f-wQRS compared to without f-wQRS [34.0 and 7.0, respectively,  $p < 0.001$ ] (Table 3).

Age and the presence of f-wQRS were predictors of obstructive CAD in univariate regression analysis [OR=1.07; 95% CI: 1.02-1.13,  $p = 0.004$  and OR=50.29; 95% CI: 11.95-211.66,  $p < 0.001$ , respectively]. In multivariate regression analysis, only the presence of f-wQRS [OR=44.31; 95% CI: 9.87-199.03,  $p < 0.001$ ] was found to be independently associated with obstructive CAD.

## Discussion

This study demonstrated the relationship between the presence of f-wQRS in patients with LBBB on surface ECG and the presence and severity of CAD. This finding of f-wQRS in patients with LBBB may be thought to be an additional risk factor for CAD.

The relationship between CAD and LBBB has been evaluated in epidemiologic studies. Framingham study reported that CAD was more frequent in patients with LBBB and that the presence of LBBB in CAD patients was an independent predictor of mortality [1,2,11,12]. For this reason, it is very important to investigate the presence of CAD in LBBB patients; however, the use of non-invasive tests for the evaluation of CAD in LBBB cases is limited.

The non-invasive procedures for the investigation of CAD in LBBB cases include evaluation of the clinical risk factors, Myocardial Perfusion Scintigraphy [MPS], cardiopulmonary exercise test, stress echocardiography and metabolic tests. The male gender, decreased ejection fraction [ $< 55\%$ ] and advanced age have been reported as clinical risk factors for the development of CAD in LBBB cases [13]. Exercise ECG, a non-invasive test that is often used in the investigation of CAD, has limited diagnostic value in LBBB patients. The ACC/AHA Guide recommends the use of pharmacological stress test and MPS for the investigation of ischemia in LBBB cases [14]. However, due to the heterogenous effect of LBBB on myocardial structure, functions and perfusion in such patients, defects in MPS, anteroseptal and septal perfusion can also be observed in the absence of CAD [15,16]. Krishnan et al. reported that the sensitivity of MPS in LBBB patients was 96% [for LAD: 84%, for CX: 50%, for RCA: 100%], and that the specificity of MPS in LBBB patients for LAD was 39%, for CX: 95%, and for RCA: 68% [17].

A recent study has asserted that in patients with chest pain and LBBB undergoing cardiopulmonary exercise test, new functional parameters such as the time needed to reach the anaerobic threshold could be a predictor for CAD [18]. Vasconcelos et al. reported that on exercise stress echocardiography of LBBB cases, degeneration in the septal wall thickening was a sign of ischemia and an independent predictor of mortality in those with CAD [19].

The non-invasive tests used in the investigation of CAD in cases of LBBB are unavailable in some centers and are generally expensive or time-consuming. This situation has led to the search for a new CAD predictor that would be easier to evaluate. In these patients, the ECG findings related to CAD display differences. It has been reported that in the presence of LBBB, the Sgarbossa criteria should be used for the diagnosis of ST segment elevation MI [20]. Again, in these patients, the findings of past Myocardial Infarction (MI) display differences. In patients with LBBB, while Q wave or T wave inversion on the aVF lead demonstrates past inferior MI with 86% sensitivity and 91% specificity,

there is no ECG finding that demonstrates past anterior or lateral MI [21].

Das et al. have reported that in cases with known or suspected CAD, the presence of f-wQRS on surface ECG with 12 derivations indicating myocardial scarring, which is normally evaluated with single photon emission computed tomography, has mid-sensitivity [62.2%] and high specificity [94%]. In their study which included patients with LBBB and RBBB, the survival time in patients with fragmented LBBB was determined to be significantly shorter than that in patients with non-fragmented LBBB, RBBB and fragmented RBBB [22]. Our study showed that in LBBB cases with no history of MI, there was a relationship between fragmented wide QRS and CAD with clinically significant stenosis on coronary angiography. The fragmented wide QRS in the CAD group was attributed to the patch-like fibrosis caused by ischemia or scar tissue caused by silent infarction. In our study, the presence of f-wQRS in patients with LBBB for documenting severe CAD was found to have 82.1% sensitivity and 91.7% specificity. This finding suggests that the presence of f-wQRS in this patient group may be non-invasive criteria for the investigation of CAD.

The mechanism of fragmented QRS formation is not fully known. However, conditions that cause non-homogenous depolarization in the myocardium such as scarring, fibrosis and ischemia have been implied as related factors [3-7]. As well as coronary ischemia, cardiac infiltrative diseases such as amyloidosis and beta-thalassemia and the conditions which causes increased left ventricular mass such as hypertension and severe aortic stenosis can lead to f-wQRS formation [23-25]. In a histopathological study, it has been demonstrated that coronary ischemia can also cause patch-like fibrosis without infarction [26]. Kadi et al. have reported that in patients with chronic total occlusion with no history of MI, the presence of fragmented QRS on the surface ECG is related to insufficient development of coronary collateral artery [27]. Apart from determining the presence of fragmented QRS, it is also important to determine the number of derivations displaying fragmented QRS and in which derivations the fragmented QRS is present. It has been reported that more myocardial tissue is under risk in ST segment elevation MI cases with fragmented QRS, and the decrease in the number of derivations with fragmented QRS after primary percutaneous coronary intervention is related to a higher resolution in the ST segment [28]. With regard to these findings, it is considered that fragmented QRS could also be present due to ischemia without infarction. In our study, the presence of f-wQRS in patients with left bundle branch block was associated with the presence and severity of obstructive CAD. It is also important that presence of f-wQRS was associated with high Gensini score which is used to assess the severity and extent of CAD.

## Study Limitations

In our study, CAD was evaluated only with angiography. Since the study did not include the follow-up of the cases, the effect of fragmented wide QRS on the prognosis could not be evaluated. This study was retrospective study and included small number of patients.

## Conclusion

In our study, presence of the f-wQRS on surface ECG in patients with left bundle branch block was associated with high Gensini score. Seeking for f-wQRS on surface ECG should be considered as an easy,

inexpensive and non-invasive method in patients' non-invasive evaluation for CAD.

## References

1. Rotman M, Triebwasser JH (1975) A clinical and follow-up study of right and left bundle branch block. *Circulation* 51: 477-484.
2. Schneider JF, Thomas HE Jr, Kreger BE, McNamara PM, Kannel WB (1979) Newly acquired left bundle-branch block: the Framingham study. *Ann Intern Med* 90: 303-310.
3. Flowers NC, Horan LG, Thomas JR, Tolleson WJ (1969) The anatomic basis for high-frequency components in the electrocardiogram. *Circulation* 39: 531-539.
4. Lesh MD, Spear JF, Simson MB (1988) A computer model of the electrogram: what causes fractionation? *J Electrocardiol* 21 Suppl: S69-73.
5. Friedman PL, Fenoglio JJ, Wit AL (1975) Time course for reversal of electrophysiological and ultrastructural abnormalities in subendocardial Purkinje fibers surviving extensive myocardial infarction in dogs. *Circ Res* 36: 127-144.
6. Wiener I, Mindich B, Pitchon R (1984) Fragmented endocardial electrical activity in patients with ventricular tachycardia: a new guide to surgical therapy. *Am Heart J* 107: 86-90.
7. Basaran Y, Tigen K, Karaahmet T, Isiklar I, Çevik C, et al. (2011) Fragmented QRS complexes are associated with cardiac fibrosis and significant intraventricular systolic dyssynchrony in nonischemic dilated cardiomyopathy patients with a narrow QRS interval. *Echocardiography* 28: 62-68.
8. Gensini GG (1983) A more meaningful scoring system for determining the severity of coronary heart disease. *Am J Cardiol* 51: 606.
9. Kim IY, Hwang IH, Lee KN, Lee DW, Lee SB, et al. (2013) Decreased renal function is an independent predictor of severity of coronary artery disease: an application of Gensini score. *J Korean Med Sci* 28: 1615-1621.
10. Cheraghi S, Shajiee S, Boroumand MA1, Pourgholi L, Ziaee S, et al. (2013) Association between R353Q polymorphism for coagulative factor VII and severity of coronary artery disease in Iranian population. *Cardiol J* 20: 533-538.
11. Hesse B, Diaz LA, Snader CE, Blackstone EH, Lauer MS (2001) Complete bundle branch block as an independent predictor of all-cause mortality: report of 7,073 patients referred for nuclear exercise testing. *Am J Med* 110: 253-259.
12. Miller WL, Ballman KV, Hodge DO, Rodeheffer RJ, Hammill SC (2005) Risk factor implications of incidentally discovered uncomplicated bundle branch block. *Mayo Clin Proc* 80: 1585-1590.
13. Jeevanantham V, Manne K, Sengodan M, Haley JM, Hsi DH (2009) Predictors of coronary artery disease in patients with left bundle branch block who undergo myocardial perfusion imaging. *Cardiol J* 16: 321-326.
14. Gibbons RJ, Abrams J, Chatterjee K, Daley J, Deedwania PC, et al. (2003) ACC/AHA 2002 guideline update for the management of patients with chronic stable angina: Summary article: a report of the American College of Cardiology/American Heart Association Task Force on Practice Guidelines. *Circulation* 107:149-158.
15. De Puey EG, Berman DS, Garcia EV (1995) Artifacts in perfusion imaging Cardiac SPECT Imaging. Raven Press, New York,USA:191-193.
16. Larcos G, Gibbons RJ, Brown ML (1991) Diagnostic accuracy of exercise thallium-201 single-photon emission computed tomography in patients with left bundle branch block. *Am J Cardiol* 68: 756-760.
17. Krishnan R, Lu J, Zhu YY, Dae MW, Botvinick EH (1993) Myocardial perfusion scintigraphy in left bundle branch block: a perspective on the issue from image analysis in a clinical context. *Am Heart J* 126: 578-586.
18. Dominguez-Rodriguez A, Abreu-Gonzalez P, Gomez MA, Garcia-Baute Mdel C, Arroyo-Ucar E, et al. (2012) Assessing coronary artery disease in patients with anginal chest pain and left bundle branch block: an emerging role for a new parameter of cardiopulmonary exercise testing. *Crit Pathw Cardiol* 11: 214-217.
19. Vasconcelos Fde L, Santos BF, Santana Nde O, Faro GB, Rocha Rde O, et al. (2011) Prognostic value of exercise stress echocardiography in patients with left bundle branch block. *Arq Bras Cardiol* 97: 478-484.
20. Sgarbossa EB, Pinski SL, Barbagelata A, Underwood DA, Gates KB, et al. (1996) Electrocardiographic diagnosis of evolving acute myocardial infarction in the presence of left bundle-branch block. GUSTO-1 (Global Utilization of Streptokinase and Tissue Plasminogen Activator for Occluded Coronary Arteries) Investigators *N Engl J Med* 334: 481-487.
21. Laham CL, Hammill SC, Gibbons RJ (1997) New criteria for the diagnosis of healed inferior wall myocardial infarction in patients with left bundle branch block. *Am J Cardiol* 79: 19-22.
22. Das MK, Suradi H, Maskoun W, Michael MA, Shen C, et al. (2008) Fragmented wide QRS on a 12-lead ECG: a sign of myocardial scar and poor prognosis. *Circ Arrhythm Electrophysiol* 1: 258-268.
23. Buyukkaya E, Karakas MF, Kurt M, Bilen P, Yalcan F, et al. (2012) The relation of fragmented QRS with tissue Doppler derived parameters in patients with b-thalassaemia major. *Clin Invest Med* 35: E334.
24. Kadi H, Kevser A, Ozturk A, Koc F, Ceyhan K (2013) Fragmented QRS complexes are associated with increased left ventricular mass in patients with essential hypertension. *Ann Noninvasive Electrocardiol* 18: 547-554.
25. Perlini S, Salinaro F, Cappelli F, Perfetto F, Bergesio F, et al. (2013) Prognostic value of fragmented QRS in cardiac AL amyloidosis. *Int J Cardiol* 167: 2156-2161.
26. Weinberg SL, Reynolds RW, Rosenman RH, Katz LN (1950) Electrocardiographic changes associated with patchy myocardial fibrosis in the absence of confluent myocardial infarction; an anatomic correlative study. *Am Heart J* 40: 745-759.
27. KadÄ H, Ceyhan K, KoÅ§ F, Celik A, Onalan O (2011) Relation between fragmented QRS and collateral circulation in patients with chronic total occlusion without prior myocardial infarction. *Anadolu Kardiyol Derg* 11: 300-304.
28. Kocaman SA, Çetin M, Kiris T, Erdogan T, Çanga A, et al. (2012) The importance of fragmented QRS complexes in prediction of myocardial infarction and reperfusion parameters in patients undergoing primary percutaneous coronary intervention. *Turk kardiyol Dern Ars* 40: 213-222.