

Repair of Pulmonary Air Leakage with Polyglycolic Acid Sheet in Children with Pulmonary Hydatid Cyst

Volkan Sarper Erikci*, Demet Payza and Münevver Hoşgör

Department of Pediatric Surgery, Dr. Behcet Uz Children's Hospital, Turkey

*Corresponding author: Volkan Sarper Erikci, Associate Professor, Department of Pediatric Surgery, Dr. Behcet Uz Children's Hospital, Süvari cad, Babadan apt. No: 34 D. 6, 35100, Bornova, İzmir, Turkey, Tel: 0 542 4372747/0 232 4116036; Fax: 0 232 4892315; E-mail: verikci@yahoo.com

Received date: Nov 02, 2016; Accepted date: Nov 08, 2016; Published date: Nov 10, 2016

Copyright: © 2016 Erikci VS, et al. This is an open-access article distributed under the terms of the Creative Commons Attribution License, which permits unrestricted use, distribution and reproduction in any medium, provided the original author and source are credited.

Abstract

Four patients with the diagnosis of isolated pulmonary hydatid cyst were treated surgically using polyglycolic acid (PGA) sheet. The usage of PGA sheet in these patients is presented and discussed under the light of relevant literature.

Keywords: Pulmonary; Children; Hydatid cyst; Polyglycolic acid sheet

Introduction

Echinococcosis is an important health problem and prevalent in many areas of the world. During the surgical management of pulmonary hydatid cysts, prolonged air leakage constitutes a major problem.

Materials and Methods

This is a retrospective study of 4 children diagnosed with the diagnosis of isolated pulmonary hydatid disease who were treated surgically using PGA sheet between 1/April/2016 and 31/July/2016. Age, sex of the patients, cyst laterality and location, size of the cyst, and days of tube thoracostomy were studied. In addition to the clinical features, chest radiography and computerised tomography (CT) were used in the diagnostic work-up and possible involvement of other viscera by the disease was excluded by the above mentioned imaging modalities. Serological tests including IHA (indirect hemagglutination test) were used complementary to radiology in suspected cases.

Results

Clinical presentations of the patients consisted of chest pain and persistent cough during night time. Hemoptysis or the pathognomonic symptoms, hydatoptysis, were not present in any patients. In addition to the clinical features, chest radiography and CT were used in the diagnostic work-up (Figures 1 and 2). All the patients received benzimidazole compounds (Albendazole/mebendazole) with a dosage of 10 mg/kg for a period of 10-14 days before surgical intervention. During standard posterolateral thoracotomy, cyst fluid was aspirated and scoloidal solution (20% NaCl) was instilled into the cyst. After opening the cyst wall, endocyst and daughter cysts were retrieved carefully. Huge bronchial communications were sutured directly and pneumostasis were completed using PGA mesh (Neoveil, Gunze, Osaka, Japan) and each corner of the PGA sheet was sutured with polyglycolic acid (Vicryl®) (Figure 3). A chest tube was placed within the hemithorax at the end of the surgical procedure. Air leakage was not observed in any of the patients after surgery and the chest tubes

were removed when the pleural drainage diminished. Details of the patients were presented in the Table 1.

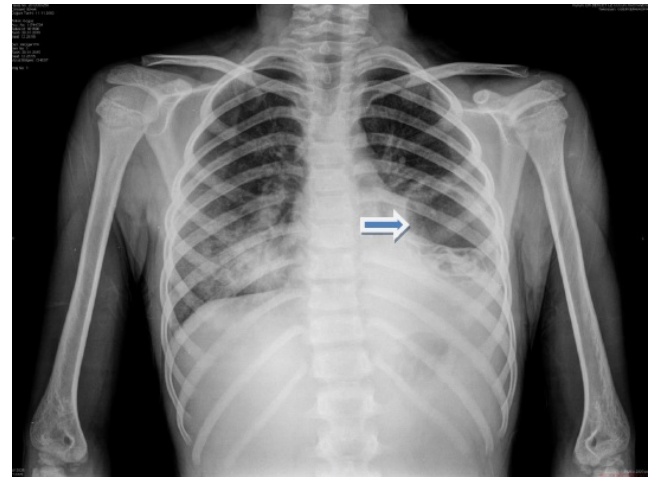


Figure 1: X-ray view of a patient with isolated pulmonary hydatid disease.

Discussion

Hydatid disease, caused by the larval stage of *Echinococcus granulosus*, is an important health problem and prevalent in many areas of the world. Although the liver and the lungs are the organs mainly involved by the disease, children are more prone to pulmonary involvement affecting the lung upto in 64% of cases [1-3]. During the surgical management of pulmonary hydatid cysts, prolonged air leakage is a major problem. As the major complications of pulmonary hydatid cyst, during the surgical management of bronchial and/or lung fistulas, direct suturing often aggravates the air leakage at the suture points. PGA has been used to achieve pneumostasis after pulmonary hydatid cyst evacuation [4]. After suture ligation of the huge bronchial communications, PGA is applied to the air leakage surface in the endocyst and the pulmonary fistula is covered with PGA sheet and is

thus more likely to burst as a result of incidentally high alveolar air pressure.

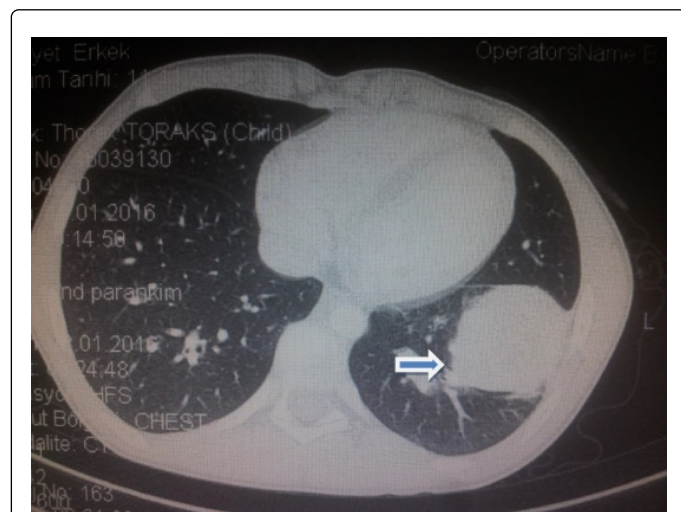


Figure 2: CT view of a patient with pulmonary hydatid disease.

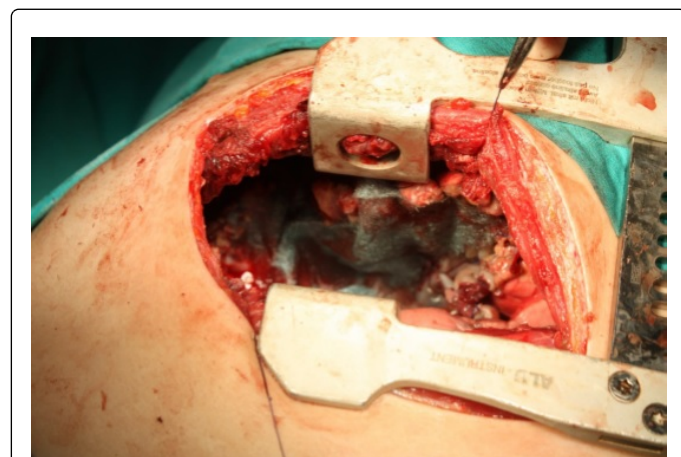


Figure 3: Operative view of a patient with pulmonary hydatid disease. Note partial cyst wall excision was performed and PGA sheet inserted into the cyst cavity.

Patient	Age (year)	Gender	Cyst laterality and location	Cyst size (cm)	Days of tube thoracostomy
Case 1	4	Male	Left lung lower lobe	7 x 8	7
Case 2	8	Female	Right lung middle lobe	6 x 7	8
Case 3	5	Male	Right lung lower lobe	5 x 6	8
Case 4	15	Male	Left lung upper lobe	10 x 11	7

Table 1: Details of the patients with isolated pulmonary hydatid disease.

Clinical studies of PGA sheets for artificial suture reinforcement were previously reported [4]. Polyglycolic acid non-woven fabrics are composed of PGA homopolymer at 103 molecular weight. PGA is hydrolysable and completely absorbed in the body after three months. Meanwhile its strength begins to decrease by half at three weeks. It is postulated that in the early stage after introduction, PGA sheet serves as a frame to reinforce the fibrin clot membrane, and in later stages, the PGA fibers represent a cradle for collagen fiber synthesis [5].

PGA sheets are now widely used for repairing air leaks in general thoracic surgery without any significant adverse effects [6]. This material has also been used in other organ surgery to prevent bile leakage after hepatic resection, to prevent CSF leakage after spinal surgery [7,8]. During thoracic surgical intervention, it is useful in terms of prevention of air leakage, hemostasis, reinforcement of the suture points and ease of use [9]. But fibrotic reaction and pleural adhesion around the applied PGA material has also been reported [6]. So this issue should be taken into consideration during the management of pulmonary hydatid cyst.

Conclusion

In conclusion, the management of pulmonary hydatid cysts, surgical intervention combined with PGA usage seems useful. This technique may contribute to shorten hospitalization, and it seems that it may result in reduction of post-thoracotomy alveolar leakage.

References

1. Tuncozgun B, Elbeyli L (2004) Pediyatrik akciğer hidatik kistlerinin cerrahi tedavisi. In: Yuksel M, Kaptanoglu M (eds) *Pediyatrik Gogus Cerrahisi* (in Turkish). Turgut Yayıncılık, Istanbul, Turkey. pp: 319-334.
2. Mutaf O, Arikan A, Yazici M, Erdener A, Özok G (1994) Pulmonary hydatidosis in children. *Eur J Pediatr Surg* 4: 70-73.
3. Tsakayannis E, Pappis C, Moussatos G (1970) Late results of conservative surgical procedures in hydatid disease of the lung in children. *Surgery* 68: 379-382.
4. Nakamura T, Shimizu Y, Mizuno H, Hitomi S, Kitano M, et al. (1992) Clinical study of bioabsorbable PGA sheets for suture reinforcement and use as artificial pleura. *Japan J Thorac Cardiovasc Surg* 40: 1828-1831.
5. Hida K, Yamaguchi S, Seki T, Yano S, Akino M, et al. (2006) Nonsuture dural repair using polyglycolic acid mesh and fibrin glue: clinical application to spinal surgery. *Surgical Neurology* 65: 136-142.
6. Yano T, Haro A, Shikada Y, Okamoto T, Maruyama R, et al. (2012) A unique method for repairing intraoperative pulmonary air leakage with both polyglycolic acid sheets and fibrin glue. *World J Surg* 36: 463-467.
7. Hayashibe A, Sakamoto K, Shinbo M, Makimoto S, Nakamoto T (2006) New method for prevention of bile leakage after hepatic resection. *J Surg Oncol* 94: 57-60.
8. Sugawara T, Itoh Y, Hirano Y, Higashiyama N, Shimada Y, et al. (2005) Novel dural closure technique using polyglactin acid sheet prevents cerebrospinal fluid leakage after spinal surgery. *Neurosurgery* 57: 290-294.
9. Nakamura T, Shimizu Y, Watanabe S, Hitomi S, Kitano M, et al. (1990) New bioabsorbable pledgets and non-woven fabrics made from polyglactide (PGA) for pulmonary surgery: clinical experience. *Thorac Cardiovasc Surg* 38: 81-85.