

## Results of Correction of Late Onset Blount Disease Deformity by Distraction Osteogenesis

Riad Mansour Megahed\*

Department of Orthopedic Surgery, Faculty of Medicine, Zagazig University, Egypt

\*Corresponding author: Riad Mansour Megahed, Department of Orthopedic Surgery, Faculty of Medicine, Zagazig University, Egypt, Tel: 00-201005645077; E-mail: [Riadmansour203@yahoo.com](mailto:Riadmansour203@yahoo.com)

Received date: March 03, 2016; Accepted date: September 19, 2016; Published date: September 26, 2016

Copyright: © 2016 Megahed RM. This is an open-access article distributed under the terms of the Creative Commons Attribution License, which permits unrestricted use, distribution and reproduction in any medium, provided the original author and source are credited.

### Abstract

**Background:** Blount disease (tibia vara) is a developmental condition. Two clinically distinct forms of Blount disease early-onset and late-onset have been described, with the classifications based on whether the limb deformity develops before or after the age of four years.

**Aim of the work:** Evaluation of the results of management of tibia vara due to late onset Blount disease by gradual correction with distraction osteogenesis.

**Materials and Methods:** This prospective study was conducted on twenty limbs in fourteen cases had late onset Blount disease in Zagazig University hospitals, Sharqia between 2011 and 2015. Gradual correction with distraction osteogenesis using the Ilizarov device was done for all of the patients.

**Results:** Results of treatment was evaluated using clinical and radiological parameters based on a modification of the criteria of Schoenecker et al. and graded them as 70% good, 30% fair and no poor results. Radiographic evaluation was done according to the Paley et al. restoration of the mechanical axis of the lower limb to normal parameters.

**Conclusion:** Gradual correction of the deformity in cases of late onset Blount disease by distraction osteogenesis using the circular fixator appears to be a safe and reliable means of treating multiplanar deformities, allowing the depressed medial tibial plateau, procurvatum and internal tibial torsion to be addressed in addition to proximal tibia varus deformity. Also allow correction of limb-length discrepancy, even in obese patients.

**Keywords:** Distraction osteogenesis; Late onset blount disease; Tibia vara; Ilizarov

### Introduction

Blount disease is a developmental condition characterized by disordered endochondral ossification of the medial part of the proximal tibial physis resulting in multiplanar deformities of the lower limb [1]. In 1937, Blount identified two forms of this disorder (infantile form and adolescent form) and coined the term "Osteochondrosis Deformans Tibiae" [2].

Thompson and Carter further classified late-onset Blount disease as a juvenile type (onset at the age of four to ten years) and an adolescent type (onset after the age of ten years) [3].

The etiology of Blount disease remains unknown. Spontaneous deceleration of growth occurs at the posteromedial proximal tibial physis, resulting in varus/flexion/internal rotational deformity, medial and posterior "sloping" of the proximal tibial epiphysis and, in unilateral cases, variable relative tibial shortening [4].

Treatment methods for limb deformity consist of acute correction by osteotomy or gradual correction using distraction osteogenesis. Gradual correction may offer several advantages over acute correction. Open osteotomies are technically difficult procedures, with a high

morbidity rate. The shortcomings of these techniques are despite careful preoperative biotrigonometric planning, three-dimensional intraoperative correction is often inexact. Closing wedges may exacerbate an existing length discrepancy. Opening wedges are less stable, often requiring bone grafting, and may lose correction if fixation is inadequate. Dome osteotomies are difficult to contour, and control of torsion is less predictable. Osteotomies combined with internal fixation preclude postoperative alignment alteration. In addition, several authors reported significant complications, including nerve palsies, compartment syndromes, and wound breakdown and complications, especially in obese patients, after open osteotomies. Gradual deformity correction of tibia vara, using circular (Ilizarov technique) devices, has been advocated to reduce the complications, including peroneal nerve palsy, compartment syndrome, residual deformity, limb-length inequality, delayed union, and failure of fixation, associated with acute corrective proximal tibial osteotomy. Circular external fixators provide angular correction in multiple planes, allowing procurvatum, internal tibial torsion, and length inequality to be corrected concomitantly with the hallmark proximal tibial varus. The progressive correction afforded by distraction osteogenesis minimizes the surgical exposure required for the osteotomy and may avoid deleterious traction on the regional neurovascular structures [5,6].

The objectives of this research are to determine the results of management and to assess the accuracy of deformity correction in twenty limbs that had late onset Blount disease by gradual correction with distraction osteogenesis.

## Patients and Methods

Ethical permission for this study was obtained from the Zagazig University hospitals and informed consent was obtained from all patients and their guardians before participation in the study. During a 4-years period, twenty tibiae in fourteen cases with late onset Blount disease had been managed by Ilizarov ring fixator in Orthopaedic Surgery Department, Zagazig University Hospitals. Eligibility criteria required individuals who had confirmed late onset Blount disease with deformity in the affected limb more than 15° tibio-femoral angle. Patients who had other etiologies as a cause of their varus deformity, either congenital/developmental/metabolic anomalies or prior trauma (i.e., fracture) affecting the growth of the affected extremity were excluded from the study.

Cases in this study were nine males and five females with a mean age of 12 years and 6 months (range 6 years and 1 month to 16 years). Based on the onset of limb deformity (after 4 years old) the cases were diagnosed as late onset Blount disease. Six cases had bilateral Blount disease were corrected with time interval between each limb at least six months after removal of the frame to allow full weight bearing and regain of muscle power, the other eight cases had unilateral deformity or the other limb had tibio-femoral angle less than 15°.

In this study, cases of late onset disease requiring tibial osteotomy was corrected with the same strategy with gradual correction by distraction osteogenesis based on the osteotomy rule II concept and fixation using Ilizarov external fixator.

## Preoperative planning

History of onset of deformity and progression of the deformity was taken from the patients and his parents. We performed general and local examinations which included: range of knee movement; the stability of the knees; lateral thrust when walking; leg-length discrepancy using blocks; and rotational deformity. All patients had a full-length weight-bearing antero-posterior (with both patellae facing forward) views of both lower extremities and Lateral radiographs of the affected limb segments. Deformity was assessed based on principles outlined by Paley et al. [7]. Moreover, the values suggestive of Blount disease as outlined by Pandya et al. [8] were utilized: TFA (19°–28° of varus), MPTA (68°–75°), and PPTA (64°–71°). Normal values for these measurements are as follows: TFA (1.3° of varus; range 1° of valgus to 4° of varus), MPTA (87°; range 85–89°), and PPTA (80°; range 77–84°).

Patients had frontal plane analyses consisting of Mechanical Axis Deviation (MAD), Tibio-Femoral Angle (TFA), Medial Proximal Tibial Angle (MPTA), and analyses of sagittal plane deformity by measuring Posterior Proximal Tibial Angle (PPTA). We drew the location of the Center of Rotation of Angulation (CORA), and determined whether it is feasible to perform the correction at that site. The tibial osteotomy is typically made in the meta-diaphysis, distal to the tibial apophysis and insertion of the patellar tendon.

## Operating-room setup and operative technique

The surgical technique involves use of a radiolucent table, intraoperative fluoroscopy with free draping of the entire lower

extremity. The preassembled frame consisted of three full rings but in obese patient may add 5/8 ring to the proximal ring. The proximal ring was placed parallel to the tibial articular surface in all planes. In all patients a base frame was applied about 5 cm distal to the tibial tuberosity, formed of two rings connected together by 3 or 4 connecting rods, fixed using a wire and half pin at each level and attached by a hinge to the distal two rings which were placed perpendicular to the tibial axis.

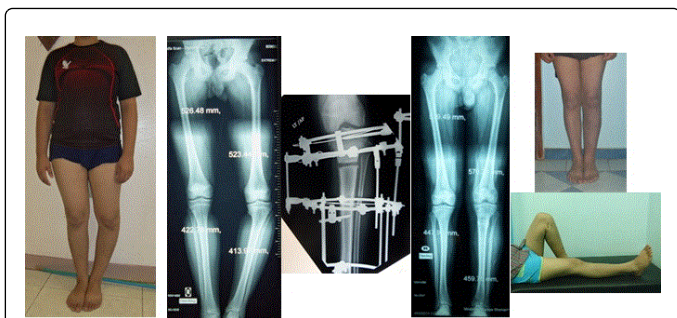
A fibular osteotomy was performed in all patients at the junction of the proximal and middle thirds of the fibula. The pre-constructed frame was appropriately centered and mounted on the leg. With use of the fluoroscopic antero-posterior projection, a smooth 1.8 mm Ilizarov wire was advanced across the proximal tibial epiphysis from lateral to medial, perpendicular to the proximal tibial mechanical axis. Typically, a reference wire and two appropriately sized half pins are attached to the proximal ring and three half pins are mounted off the distal ring in different planes. The wires were tensioned to 90 to 130 kg using a dynamometer, depending on the age of the patient. Tibial osteotomy then was done in the proximal tibial metaphysis through a 2 to 3 cm medial incision. Percutaneous technique with multiple drill-holes osteotomy to minimize thermal necrosis was safely performed through small incisions with preservation of the periosteal sleeve. The tibial osteotomy was not completed at this stage, and following fixation of the frame to the tibia the rods are temporarily disengaged from one of the rings, and the osteotomy completed. The wound is closed with simple sutures, and the pin sites are dressed with gauze and sterile dressings. An elastic bandage is used to pull the forefoot into a neutral position.

## Postoperative care

Patients were admitted to the hospital for two to four days with the mean hospital stay was 3.5 days. The patients received intravenous antibiotics for forty eight hours and are then switched to oral antibiotics. The dressings are removed on the third postoperative day.

Post-operatively, Gradual correction of the varus deformity was started one week post-operatively and took 3-5 weeks depending on the degree of the pre-operative deformity. Varus correction was initiated 5 days after surgery at a rate of four 0.25 mm distractions per day at the medial side of the tibia with a synchronous lateral translation of the distal tibial segment on the proximal one. This translation occurs as a result of the intrinsic dynamic behavior of the construct that guide gradual correction. This happens as a result of the position of the hinge of the apparatus proximal to the level of the tibial osteotomy. Gradual correction was continued until neutral alignment of the limb was achieved. Shortening, if present, was also corrected gradually. Rotational deformity was corrected gradually after the distraction period by using derotation connections which allow turning of the rings in opposite directions with respect to each other (Figure 1).

Daily pin care consisting of a mixture of half-normal saline and half hydrogen peroxide applied to the pin sites with sterile cotton swabs. Pins and wires are covered with dressings at the skin. At the end, the frame was locked and a further 10–12 weeks were allowed for consolidation, guided by regular radiological follow-up before frame removal. If a lengthening was performed, a further 4–6 weeks were needed for every additional centimeter.



**Figure 1:** (A) Pre-operative Clinical photos of case No.1, (B) long standing X-ray for both lower limbs, (C) one month postoperative X-ray of case No.1, (D) Long standing X-ray one and half years post operative and (E) clinical photos and functional outcome of case No.1.

Fixators were removed when the patients were walking without pain or the use of an assistive device and when callus is seen on three cortices around the osteotomy site. We prefer to remove the frames in the operating room. At the time of frame removal, osseous union and maturation of the regenerated bone may be evaluated with a stress test under c-arm fluoroscopy. Once the fixator is removed, the patients were managed with a short leg cast depending on clinical needs. They were allowed partial weight-bearing for two weeks and then progress to full weight-bearing thereafter.

Radiographic parameter	Pre-operative mean ± SD	Post-operative mean ± SD	T value	P value	Significance
Tibio-femoral angle (TFA)	28 ± 7.2	6.6 ± 4.6	7.167	<0.001	HS
Femoral condyle-tibial shaft angle	59.1 ± 5.9	83.1 ± 5.8	-8.783	<0.001	HS
Mechanical Axis Deviation (MAD)	35.9 ± 10	-0.7 ± 3.1	13.081	<0.001	HS
Medial proximal tibial angle (MPTA)	68.3 ± 9.3	87.6 ± 1.3	-6.441	<0.001	HS
Posterior proximal tibial angle (PPTA)	77 ± 8.2	82.1 ± 4.4	-3.723	0.005	S

**Table 1:** Paired t test for comparison between pre and post scores as regard radiographic parameters. (HS) Highly Significant (S) Significant (NS) Not Significant.

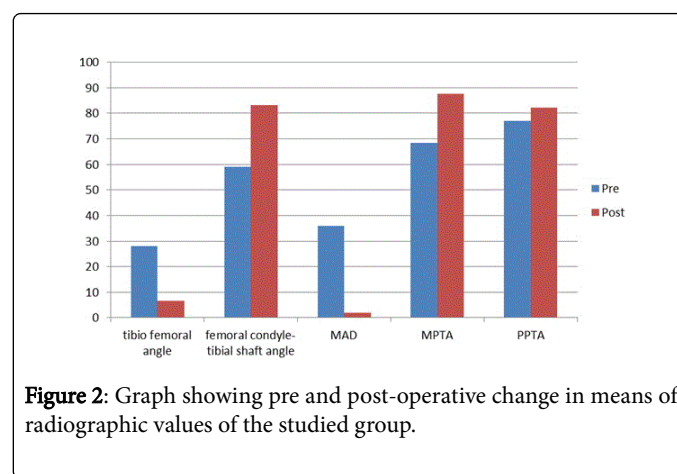
### Statistical analysis

Data collected throughout history, clinical and radiological evaluation, peri-operative data, intra-operative data complications and

outcome measures coded, entered and analyzed using Microsoft Excel software. Data were then imported into Statistical Package for the Social Sciences (SPSS version 20.0) software for analysis. The results were expressed as means ± SD (Figure 2). The data obtained from the used double score system were analyzed statistically using paired T test. P values less than 0.05 were considered significant (Table 1).

### Results

In this study fourteen patients (20 tibiae) underwent correction of Blount disease by Ilizarov method. All patients had regular thorough follow up for a period ranging from 12 to 48 months with a mean period of 24.7 months. The mean of total time that the fixator was on the patients prior to removal was 15.8 weeks (SD ± 2.3) range from 12 to 20 weeks. The mean operative time was 120.6 min (SD ± 21.2).



**Figure 2:** Graph showing pre and post-operative change in means of radiographic values of the studied group.

### Clinical results

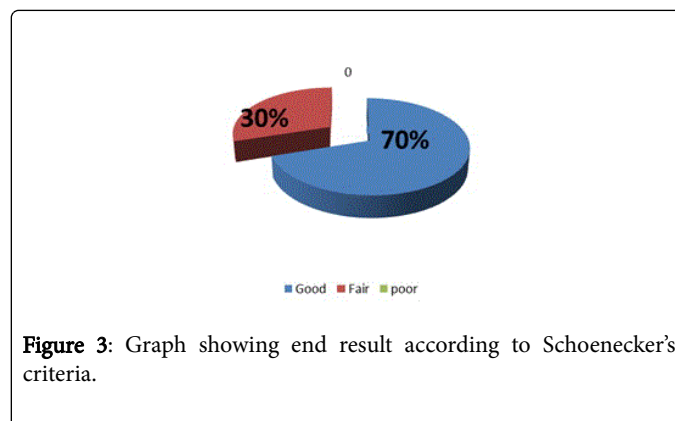
Mean preoperative leg length discrepancy (shortening) was 11 mm with SD ± 11.6. The mean post operative leg length discrepancy (over lengthening) was 5.7 mm SD ± 7.8 (P=0.001) so the leg length discrepancy significantly improved post operative. All the patients before the correction had frequent knee pain with 8 limbs (40%) had temporary restriction of mobility. After correction of the deformity three limbs (15%) had occasional knee pain (P=0.001). All the patients before the correction had instability of the affected knee. Six limbs had lateral thrust during walking. After correction three cases had mild instability during clinical knee examination. The mean preoperative Range of Motion (ROM) was 133° SD ± 15.1 changed to 132.7 ± SD 13.7 postoperative at final follow up. Active motion of the joints was allowed the day after surgery, not at the end of the treatment period. Greater than 5° loss of motion occurred in only three patients. Although the ROM of the knee increased in five limbs, it is not possible to conclude whether this increase was attributable to correction of the deformity or attributable to early active movements. Mean preoperative to postoperative changes of the tibial torsion from -23.5° (range 5°-45°) with SD ± 12 internal tibial torsion significantly improved to 6.2° (range 0°-10°) with SD ± 3external tibial rotation (Table 2).

Patient No.	Sex	Age	Side	Langenskind Classific	Tibial torsion (Degrees)		Range of motion (Degrees)		Leg Length discrepancy (mm)		Instability		Pain		Fixator time (week)	Follow up (month)
					Pre	Post	Pre	Post	Pre	Post	Pre	Post				
1	M	16	Lt	IV	-10	10+	130	140	-13	0	#	No	#	NO	16	39
2	M	14.6	Lt	IV	-30	5+	130	130	-16	10+	##	No	##	#	16	36
			Rt	IV	-25	5+	150	145			##	No	#	NO	14	
3	F	12	Lt	IV	-25	7+	135	130	-14	5+	###	Partial lateral	##	NO	14	30
			RT	IV	-20	7+	140	130			##	No	#	NO	14	
4	M	11	Rt	III	-15	4+	145	140	0	20+	#	No	##	NO	17	16
5	M	15.6	Rt	IV	-20	6+	150	140	-10	0	###	No	##	NO	18	24
			Lt	IV	-15	10+	135	120			##	No	#	NO	12	
6	M	15.8	Lt	IV	-35	8+	120	135	-22	5+	###	Partial lateral	#	NO	20	12
7	F	10.9	Lt	IV	-5	0	100	100	-5	0	#	No	#	#	12	48
8	F	6.1	Lt	III	-20	5+	140	150	-14	5+	###	No	##	No	14	24
9	M	11.9	Lt	IV	-30	7+	150	120	-16	0	###	NO	#	NO	15	12
10	M	13.8	Lt	IV	-45	10+	135	135	-14	10+	###	Partial lateral	##	#	16	23
			RT	IV	-35	4+	145	140			##	No	#	NO	20	
11	F	10	Lt	III	-5	0	130	130	-10	0	#	No	#	NO	16	25
12	M	14	Rt	IV	-30	6+	130	150	-5	10+	##	No	##	NO	17	13
			Lt	IV	-20	10+	120	135			#	No	#	NO	18	
13	F	13	Rt	IV	-10	8+	100	100	-15	5+	##	No	##	NO	15	20
14	M	12	Lt	IV	-45	5+	150	145	0	10+	##	No	#	NO	16	24
			Rt	III	-30	7+	135	140			#	No	#	NO	16	

**Table 2:** Clinical demographic changes in deformity and motion of the studied cases.

### Radiological results

Mean preoperative to postoperative changes as regard tibio-femoral angle from 28° (range 20°-39°) with SD ± 7.2 in varus significantly improved to 6.6° (range 0°-12°) with SD ± 3 in valgus. Mean preoperative to postoperative changes of femoral condyle-tibial shaft angle from 59.1° (range 48°-67°) with SD ± 5.9 improved to 83.1° (range 73°-90°) with SD ± 5.8. Mean preoperative to postoperative changes of Mechanical Axial Deviation (MAD) from -35.9 mm (range 25-57 mm) with SD ± 10 improved to -0.7 mm (range 0-5 mm) with SD ± 3.1. Mean preoperative to postoperative changes of medial proximal tibial angle from 68.3° (range 70-83°) with SD ± 9.3 improved to 87.6° (range 86-89°) with SD ± 1.3. Mean preoperative to postoperative changes of posterior proximal tibial angle from 77° (range 62-85°) with SD ± 8.2 improved to 82.1° (range 75-85°) with SD ± 4.4 (Table 3).



**Figure 3:** Graph showing end result according to Schoenecker's criteria.

The aim of surgery was achieved in this study to restore the radiographic measurements as Paley et al. [7] had outlined by

restoration of the mechanical axis of the lower limb to normal parameters. All patients were satisfied by the end of the follow up. The results of the study were graded as good, fair or poor based on a modification of the criteria of Schoenecker et al. [9].

At a mean 24 months follow-up, we evaluated these results applying the modified criteria of Schoenecker et al. [9].

- Good results were obtained with a patient experiencing no pain and no instability associated with a correct anticipated lengthening

of the leg. The mechanical angle of the leg and the knee deviated less than 5° from theoretical angles (10° of valgus maximum).

- Fair results were obtained with patients experiencing occasional pain, moderate instability and a knee that deviated by 5–10° from theoretical angles.
- Poor results were obtained with patients experiencing painful unstable knees with major axis abnormalities combined with a final leg length discrepancy exceeding 3 cm.

Patient No.	Side	Tibio femoral angle (degree)		MAD (mm)		MPTA (degree)		PPTA (degree)		Femoral condyle shaft (degree)	tibial angle	Schoenecker criteria	Complications		
													Pin infection	Recurrence	Common peroneal nerve injury
1	Lt	-21	0	-25	1	71	86	85	85	60	90	Good	0		
2	Lt	-39	2	-35	-5	56	88	73	81	58	78	Good	2		
	Rt	-25	0	-25	1	73	88	76	81	58	90	Good	2		
3	Lt	-24	0	-40	-5	58	88	80	85	65	73	Good	1	After 2 years	
	RT	-21	5	-38	-4	79	89	83	87	60	80	Good	1		
4	Rt	-25	8	-30	2	70	89	83	87	55	85	Good	2		
5	Rt	-37	5	-46	2	60	87	76	79	60	90	Good	1		
	Lt	-35	8	-40	-5	58	89	73	79	55	73	Good	1		
6	Lt	-33	10	-38	-4	73	89	62	75	57	80	Good	1		
7	Lt	-20	12	-25	0	73	86	85	85	66	90	Fair	1	After 3 years	
8	Lt	-25	10	-28	3	60	88	84	87	48	85	Fair	1		Transient
9	Lt	-21	12	-35	4	83	89	65	76	55	80	Fair	2		
10	Lt	-35	7	-57	-5	79	86	77	81	67	80	Good	0		
	RT	-25	7	-25	-5	73	89	80	85	66	78	Good	0		
11	Lt	-24	12	-28	4	70	88	85	85	65	90	Fair	2		
12	Rt	-39	2	-57	0	56	86	62	75	48	80	Good	2		
	Lt	-33	0	-35	-5	60	86	65	76	55	80	Good	0		
13	Rt	-21	10	-30	2	71	87	84	87	67	85	Good	1		
14	Lt	-37	10	-46	2	60	86	77	81	57	85	Fair	2		
	Rt	-20	12	-30	3	83	88	85	85	60	90	Fair	2		

Table 3: Radiographic demography of the studied cases and complications.

**Overall results**

- **Good:** 14/20: fourteen limbs out of twenty limbs had good results.
- **Fair:** 6/20: Six limbs out of twenty limbs had fair results. Two patients had experienced occasional pain; due to over correction into valgus.
- **Poor:** 0/20: No patient had poor result

- As per Schoenecker’s criteria there were 70% good results in terms of pain and radiographic criteria in our patients, 30% fair. There were no poor results (Figure 3).

**Complications**

Complications from the procedures included peroneal nerve palsy and superficial pin tract infection. Although pin tract infection

developed in 16 cases all healed with local wound care and oral antibiotics. Only one patient developed partial peroneal nerve palsy which resolved completely at removal of the frame (Figure 4). There were no vascular complications, deep infection, delayed unions, or nonunion (Table 4).

## Discussion

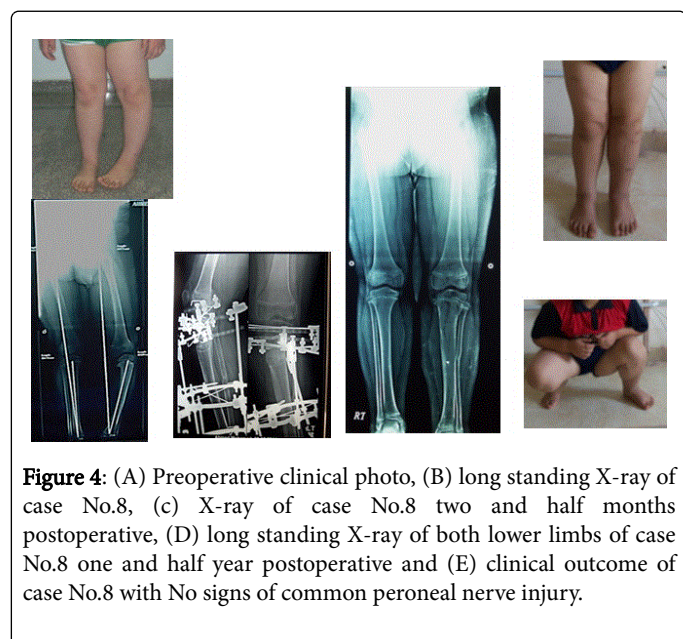
Various methods have been used to correct the deformity in patients with late onset Blount's disease including different osteotomies with numerous fixation techniques [10].

Complication	Number of cases	Percentage
Pin tract infection	16 cases	80%
Partial peroneal nerve palsy	1 case	5%
Recurrence	2 cases	10%

**Table 4:** Table shows the Complications.

In this work twenty limbs in fourteen patients with late onset Blount disease had been managed by gradual distraction osteogenesis by Ilizarov technique.

The mean age at the time of operation for the current study was 12.6 years ranging from (6.1-16 years), onset of the deformity in the cases included in the study was after 4 years old so all of them was diagnosed as late onset form. We noted an increase incidence of late onset Blount disease in males (64.2%) than in females (35.7%) in the studied group. The findings of the current study are consistent with those of Sabharwal [1] that unilateral involvement is common with a late-onset presentation (64.2%).



**Figure 4:** (A) Preoperative clinical photo, (B) long standing X-ray of case No.8, (c) X-ray of case No.8 two and half months postoperative, (D) long standing X-ray of both lower limbs of case No.8 one and half year postoperative and (E) clinical outcome of case No.8 with No signs of common peroneal nerve injury.

The duration of frame fixation in this study was from the time of application to the time of removal averaged  $15.8 \pm 2.3$  weeks compared to Gordon et al. [11] study the mean fixator wear time was approximately 150 days (21.4 weeks) and in Eidelman et al. [12] study they used TSF in adolescent Blount's disease Frames were removed at

an average of 12.8 weeks (range 12–15 weeks). Feldman et al. [13] used the TSF in 19 patient's time of removal averaged 14.6 weeks (range 9–24 weeks). This result match those observed in earlier study done by Feldman et al. [14] as the total time that the external fixator was used was similar for the acute correction group, with a mean of 12.9 weeks (range, 8-22 weeks) and a mean of 14.3 weeks (range, 9-24 weeks) for the gradual correction group.

In this work all patients complained of pain in the involved knee preoperatively and six limbs were observed to have a lateral knee thrust when walking. All patients had clinical improvement. Three patients continued to complain of occasional knee pain in one limb, the etiology of which could not be determined. At the time of the last follow-up the pain did not limit the patient's activities. Three cases had mild instability during clinical knee examination. No patient had clinically important knee laxity to varus or valgus stress at the time of the last follow-up. Loss of motion of knee joint occurred in only three patients. The findings observed in this study mirror those of the previous study of Gordon et al. [11] who examined 15 patients with late-onset tibia vara who were corrected using tibial osteotomy and an Ilizarov circular fixator. At the time of the last follow-up, fourteen patients (eighteen extremities) were asymptomatic and one patient (one extremity) continued to complain of knee pain, the etiology of which could not be determined.

In the current series all the lower limbs before the correction was in internal rotation with mean  $23.5^\circ$  SD  $\pm 12$  internal tibial torsion improved to  $6.2^\circ$  with SD  $\pm 3$  external tibial torsion. These results agree with the findings of other studies, In Alekberov et al. [10] study the preoperative internal torsion angle also improved from  $20.7^\circ$  to  $3.5^\circ$  external torsion postoperatively. Eidelman et al. [12] with TSF studied the mean correction of internal tibial torsion was  $10^\circ$  performed in six patients (eight tibias). In Feldman et al. [13] study six tibias had clinical internal rotation deformity with a preoperative mean of  $17.5^\circ$  to no postoperative clinical evidence of internal rotation.

Mean preoperative leg length discrepancy (shortening) was 11 mm with SD  $\pm 11.6$  in the affected limb significantly improved post operative leg length discrepancy (over lengthening) was 5.7 mm SD  $\pm 7.8$ . Shortening was present in Feldman et al. [14] study in 18 patients, with a preoperative mean of 11 mm (range 3–30 mm) and postoperative correction within 2 mm.

All patients were maintaining full extension of the knee at the final follow-up. The gait pattern was improved significantly in all patients. The mean preoperative ROM was  $133^\circ$  SD  $\pm 15.1$  changed to  $132.7^\circ \pm$  SD  $13.7$  postoperative at final follow up. In study of Hefny et al. [15] the range of flexion changed from an average of  $130$  preoperatively to an average of  $125^\circ$  at the final follow-up.

The radiographic results of this study show that the mean preoperative to postoperative changes as regard tibio-femoral angle from  $28^\circ$  (range  $20^\circ$ – $39^\circ$ ) with SD  $\pm 7.2$  in varus improved to  $6.6^\circ$  (range  $0^\circ$ – $12^\circ$ ) with SD  $\pm 3$  in valgus. The percentage of improvement of anatomical tibio-femoral angle by paired t test was 76.4% with p value  $<0.001$ . In Alekberov et al. [10] study, the mean  $28.6^\circ$  varus tibiofemoral angle preoperatively (range,  $15^\circ$ – $45^\circ$ ) improved to  $7.5^\circ$  valgus (range,  $0^\circ$ – $18^\circ$ ) postoperatively. Coogan et al. [16] corrected a preoperative mean varus malalignment of  $26^\circ$  in the mechanical axis to a mean of  $8^\circ$  and a mean tibial varus deformity of  $18^\circ$  to a postoperative mean deviation of  $2.5^\circ$  from normal anatomical alignment. In study of Eidelman et al. [12] the mean preoperative proximal tibial varus was  $16.2^\circ$  (range  $12^\circ$ – $19^\circ$ ), and was corrected to

normal values in all patients. In Hefny et al. [15] study the average preoperative femoral shaft - tibial shaft angle was 36° of varus (ranging from 20° to 47°). The final femoral shaft - tibial shaft angle improved to an average of valgus 4° (ranging from 12° to 3°).

For the (MAD) the post operative values mean was -0.7 mm SD ± 3.1 was significantly less than preoperative mean -35.9 mm SD ± 10. Statistical analysis by paired t test showed that the percentage of improvement was 94.7%. In study of Gordon et al. [11] their method was able to achieve a mean decrease of 107 mm in the MAD. In Feldman et al. [14] study mean preoperative to postoperative changes of MAD from 53.9 mm (range 31–120 mm) to 1.4 mm (range 0–4 mm). In Eidelman et al. [12] study preoperative MAD was 55.8 mm medial to the center of the knee (range 44–77 mm) and was corrected to a mean of 4.9 mm (range 2–11 mm).

The mean of femoral condyle-tibial shaft angle of the studied group had significantly improved from 59.1° SD ± 5.9 to 83.1° SD ± 5.8. The final femoral condyle - tibial shaft angle in Hefny et al. [15] study improved to an average of 83° (ranging from 78° to 90°).

Mean preoperative medial proximal tibial angle in this study was 68.3° (range 70–83°) with SD ± 9.3 improved to 87.6° (range 86–89 °) with SD ± 1.3 postoperative. Eidelman et al. [12] mean preoperative MPTA was 71.4° (range 67–77°), and was corrected to a mean of 87.1° (range 85–89°). The MPTA increased 17° postoperatively (mean 88.0°) in Gordon et al. [11] study.

In this study the mean preoperative to postoperative changes of posterior proximal tibial angle from 77° (range 62–85°) with SD ± 8.2 improved to 82.1 (range 75–85°) with SD ± 4.4. Feldman et al. [13] mean preoperative to postoperative changes of proximal posterior tibial angle from 71.8° (range 60°–83°) to 80.9° (range 78°–84°).

In this series there was no changes as regard lateral distal femoral angle as mean was 89.3° SD ± 2.5 ranging from 85° in cases of early onset to 92° in cases of late onset so no need to be corrected. In Feldman et al. [13] study the mean lateral distal femoral angle was 88.0° (range 87°–90°).

Complications in this study from the procedures included one limb (5%) with partial peroneal nerve palsy, sixth teen limbs (80%) with superficial pin tract infection and two limbs (10%) with recurrence.

Van Olm and Gillespie [17] reported peroneal nerve palsy in 15% of 100 patients and a compartment syndrome in 6%. Steel et al. [18] found an 18% overall incidence of neurovascular complications.

Price et al. [19] described the use of uniplanar dynamic fixator for 34 osteotomies in 25 patients for correction of tibia vara. They had six tibias with residual varus, two patients with a postoperative neuropraxia, and nine pin-tract infections. Also they noted that under correction and overcorrection were relatively common complications of the Coventry-type osteotomy. This lack of accuracy led to a broad array of final alignments in the closing wedge osteotomy group. Pinkowski and Weiner [20] reported 11% complications, which included one delayed union and three superficial infections. They had no neurovascular complications in the 37 proximal tibial osteotomies performed for deformity correction. Stanitski et al. [21] reported eight patients who had superficial pin-site infections. There was one delayed union, one premature consolidation that required re-osteotomy, two residual limb length inequalities (1.8 and 3.0 cm), and one failure to correct rotation.

We had no wound infections, compartment syndrome, premature consolidation or nonunion. Patients were often kept on antibiotics during the corrective phase and then told to keep a bottle of cephalexin at home. If a pin became painful or had increased drainage, patients were instructed to begin antibiotics again. This may lead to a decreased reporting of pin-tract problems.

Alekberov et al. [10] recorded a recurrence rate in 69 cases to be 8.7% after 6.7 years where Eidelman et al. [12] recorded no recurrence in his work on 8 cases after 3.7 years. The low recurrence rate of these last 2 series may be explained on the bases of that their cases were relatively of older ages at the time of treatment where the mean age of the cases of the former was 10.7 years and 14.6 years for the later, moreover, both authors fixed the osteotomy rigidly by circular fixators. In this work, the overall recurrence rate was 2 out of 20 limbs (10%) which lie near the last two results.

In this study one patient had a transient peroneal nerve palsy (manifested as extensor hallucis longus weakness), which spontaneously resolved two months postoperatively.

Peroneal nerve palsies may be the result of direct damage, aggressive derotation of the torsional deformity, or transient anterior compartment syndrome [22,23].

## Summary and Conclusion

Gradual Correction of late onset Blount's disease by Distraction Osteogenesis offers several advantages over acute correction. The Ilizarov method allows correction of the deformity in any plane, allowing procurvatum and internal tibial torsion to be addressed in addition to proximal tibialvarus. Blount's disease is characterized by varus and internal tibial torsion and genu procurvatum, and it is known that the incomplete correction tends to progressive recurrence so it is mandatory to correct the deformity in three planes.

The stability of the frame also allows early weight bearing and early motion of the adjacent joints. It is known that motion is important clinically for preserving the muscular and articular function and encouraging the patient to have a normal social life. Unlike the problem of the high cost of TSF equipment results overall were good, with minimal morbidity.

## References

1. Sabharwal S (2009) Current Concepts Review Blount Disease. *J Bone Joint Surg Am* 91: 1758-1776.
2. Blount WP (1937) Tibia vara: Osteochondrosisdeformans tibiae. *J Bone Joint Surg Am* 19: 1-29.
3. Thompson GH, Carter J (1990) Late-onset tibia vara (Blount's disease). Current concepts. *Clin Orthop Relat Res* 255: 24-35.
4. Birch JG (2013) Blount Disease. *J Am Acad Orthop Surg* 21: 7.
5. Gilbody J, Thomas G, Ho K (2009) Acute versus gradual correction of idiopathic tibia vara in children: a systematic review. *J Pediatr orthop* 29: 110-114.
6. Smith S, Beckish M, Winters S, Pugh L, Bray E (2000) Treatment of Late-Onset Tibia Vara Using Afghan Percutaneous Osteotomy and Orthofix External Fixation. *J Pediatric Orthopaedics* 20: 606-610.
7. Paley D (2002) Principles of deformity correction. Verlag Berlin Heidelberg: Springer.
8. Pandya NK, Clarke SK, McCarthy JJ, Horn BD, Hosalkar HS (2009) Correction of Blount's disease by a multi-axial external fixation system. *Child Orthop* 3: 291-299.

9. Schoenecker PL, Meade WC, Pierron RL, Sheridan JJ, Capelli AM (1985) Blount's disease: a retrospective review and recommendations for treatment. *J Pediatr Orthop* 5: 181-186.
10. Alekberov C, Shevtsov VI, Karatosun V, Gunal I, Alici E, et al. (2003) Treatment of tibia vara by the Ilizarov method. *Clin Orthop Relat Res* 409: 199-208.
11. Gordon JE, Heidenreich FP, Carpenter CJ, Kelly-Hahn J, Schoenecker PL (2005) Comprehensive treatment of late-onset tibia vara. *J Bone Joint Surg Am* 87: 1561-1570.
12. Eidelman M, Bialik V, Katzman A (2008) The use of the Taylor spatial frame in adolescent Blount's disease: Is fibular osteotomy necessary? *J Child Orthop* 2: 199-204.
13. Feldman DS, Madan SS, Koval KJ, Van Bosse HJ, Bazzi J, et al. (2003) Correction of tibia vara with six-axis deformity analysis and the Taylor Spatial Frame. *J Pediatr Orthop* 23: 387-391.
14. Feldman DS, Madan SS, Ruchelsman DE, Sala DA, Lehman WB, et al. (2006) Accuracy of correction of tibia vara: acute versus gradual correction. *J Pediatr Orthop* 26: 794-798.
15. Hefny H, Shalaby H, El-kawy S, Thakeb M, Elmoatasem E (2006) A New Double Elevating Osteotomy in Management of Severe Neglected Infantile Tibia Vara using the Ilizarov Technique. *J Pediatr Orthop* 26: 233-237.
16. Coogan PG, Fox JA, Fitch RD (1996) Treatment of adolescent Blount disease with the circular external fixation device and distraction osteogenesis. *J Pediatr Orthop* 16: 450-454.
17. Van Olm, Gillespie (1983) Canadian Orthopaedic Association Meeting.
18. Steel HH, Sandrow RE, Sullivan PH (1971) Complications of tibial osteotomy in children for genu varum or valgum. *J Bone Joint Surg* 53: 1629-1635.
19. Price CT, Scott DS, Greenberg DA (1995) Dynamic axial external fixation in the surgical treatment of tibia vara. *J Pediatr Orthop* 15: 236-243.
20. Pinkowski JL, Weiner DS (1995) Complications in proximal tibial osteotomies in children with presentation of technique. *J Pediatr Orthop* 15: 307-312.
21. Stanitski DF, Dahl M, Louie K, Grayhack J (1997) Management of late-onset tibia vara in the obese patient by using circular external fixation. *J Pediatr Orthop* 17: 691-694.
22. Gibson MJ, Barnes MR, Allen MJ, et al. (1986) Weakness of foot dorsiflexion and changes in compartment pressures after tibial osteotomy. *J Bone Joint Surg Br* 68: 471-475.
23. Slawski DP, Schoenecker PL, Rich MM (1994) Peroneal nerve injury as a complication of pediatric tibial osteotomies: A review of 255 osteotomies. *J Pediatr Orthop* 14: 166-117.