

Results of Management in Emergency of the Colic Cancer about 4 Cases in Sub-Saharan Africa

Kambire JL^{1*}, Ouedraogo S¹, Zoungrana SL¹, Zida M² and Traore SS²

¹Ouahigouya's Teaching Hospital Center, Burkina Faso, France

²Yalgado Ouedraogo's Teaching Hospital Center, Burkina Faso, France

*Corresponding author: Kambire JL, Assistant of General Surgery, Ouahigouya's Teaching Hospital Center, Burkina Faso, France, Tel: (226) 70338914; E-mail: jeanluckambire@yahoo.fr

Received date: June 07, 2017; Accepted date: June 21, 2017; Published date: June 28, 2017

Copyright: © 2017 Kambire JL, et al. This is an open-access article distributed under the terms of the Creative Commons Attribution License, which permits unrestricted use, distribution, and reproduction in any medium, provided the original author and source are credited.

Abstract

Introduction: Colon cancer is the most common of the digestive tract. It is the second cause of cancer in women and the third cause in men, it conventionally concerns the patients of more than 60 years; it is pauci symptomatic, but can be revealed during a digestive surgical emergency, posing the problem of its management and its prognosis particularly in poor areas such as sub-Saharan Africa.

Patients and methods: It was cases study of patients operated in emergency in the year 2016 for histologically confirmed colonic tumor.

Results: Four cases of colonic tumors were histologically confirmed; they were 3 men and 1 woman with an average age of 42.5 year-old. The clinical expression was acute generalized peritonitis with 2 cases and acute intestinal occlusion with 2 cases. The follow-up post-operative was simple with 3 cases; a postoperative complication was noted in 1 patient and his death occurred secondarily.

Conclusion: Colon cancer is a redoubtable disease; it is not only limited to the elderly patients; the young person is also a susceptible population suffered colon cancer in poor areas. It is paucisymptomatic and its treatment remains a major preoccupation in sub-Saharan Africa, In view of the financial and geographical inaccessibility to chemotherapy.

Keywords: Colic cancer; Occlusive syndrome; Creatinine levels; Hartmann procedure

Introduction

Colon cancer is the most common of the digestive tract; it is the second cause of cancer in women and the third cause in men it conventionally concerns the patients of more than 60 years [1]. It is pauci symptomatic, but can be revealed during a digestive surgical emergency, posing the problem of its management and its prognosis particularly in poor areas such as sub-Saharan Africa.

Patients and Methods

It was cases study of patients operated in emergency in the year 2016 for histologically confirmed colonic tumor.

Clinical Observation N°1

O. A, is a 34-year-old patient, received at the surgical emergency department for abdominal pain, vomiting, the notion of inability to pass stool and gases evolving for 5 days around in a febrile context. Antecedents of functional colopathy were noted. The clinical examination revealed an occlusive syndrome; the diagnosis of acute intestinal occlusion was also discussed, and the X-ray of the abdomen without preparation showed higher peripheral hydrotheric levels than the broad ones. The biological assessment revealed a white count at

10.000 cells/mm³, a hemoglobin level of 11 g/dl; blood glucose and creatinine levels were normal. The patient was operated on an emergency. The laparotomy found a stenosing tumor of the sigmoid colon; a segmental colectomy was performed according to Hartmann procedure; the surgery was complicated by parietal suppuration and the release of the wall; a secondary suture was realized and the patient has left the hospital after 21 days. The histological examination of the specimen of resection revealed adenocarcinoma invading the meso. The restoration of continuity occurred 70 days later; the post-operative follow-up was complicated by an enterocutaneous fistula; a parenteral nutrition was prescribed, but it could not be honored; the patient died in a cachexia condition.

Clinical Observation N°2

T.S is a 50-year-old patient who is admitted to the surgical emergency department for severe abdominal pain, marked in the right iliac fossa for 6 h. The clinical examination revealed a tumefaction of the right iliac fossa, mate and painful with percussion; the rest of the abdomen was relatively supple and painless. Also, a small bowel volvulus was evoked. The biological assessment revealed a white count at 14.000 cells/mm³, a hemoglobin level of 12.6 g/dl; blood glucose and creatinine levels were normal. The patient was operated on an emergency. The laparotomy has shown an ulcero-necrotic tumor of the cecum. A right hemi-colectomy was performed with ileo-transverse anastomosis. The post-operative follow-up was simple and the patient

has left the hospital after 6 days. Histological examination of the specimen of resection concluded to a histological aspect of mucinous adenocarcinoma of the cecum.

Clinical Observation N°3

P.K is a 46-year-old patient who is admitted to the surgical emergency department for abdominal pain that has evolved for 2 days with the notion of vomiting and stopping materials and gases in a febrile context. The clinical examination revealed a peritoneal syndrome with diffuse abdominal rigidity. Also, the diagnosis of acute generalized peritonitis was evoked. The biological assessment revealed a white count at 16.000 cells/mm³, a hemoglobin level of 10.5 g/dl; blood glucose and creatinine levels were normal. The patient was operated on an emergency. The laparotomy has revealed an ulceronecrotic tumor of the cecum. A right hemicolectomy was performed with ileo-transverse anastomosis. The post-operative follow-up was simple and the patient has left the hospital after 6 days of hospitalization. The histological examination of the piece of resection has revealed a liberkühnian adenocarcinoma.

Clinical Observation N°4

It was a 40-year-old patient admitted in emergency for abdominal pain associated with vomiting evolving for 3 days. On admission, he presented a good general condition, colored conjunctiva and physical examination revealed, a painful swelling of the right side. The sign of Dance was positive. An abdominal ultrasonogram showed in longitudinal section a "sandwich», and in transverse section, a target sign or "doughnut" sign in favor of an intestinal intussusception. The biological assessment revealed a white count at 4,800 cells/mm³, a hemoglobin level of 13.4 g/dl; blood glucose and creatinine levels were normal. The laparotomy revealed an ileo-colic intussusception. A right hemicolectomy was performed followed by end to end ileo-colic anastomosis. The post-operative follow-up was simple and the patient left the hospital after 7 days. The histological examination of the resected specimen concluded to a colic adenocarcinoma of low grade, pT2N0 stage.

Comments

Colorectal cancer is the second cancer in women and the third in men; its prevalence in France is estimated in 2012 to 40,500 cases [1]. In Africa, the data on this disease are fragmented. In the Benamr et al. series [2] between 1975 and 1994, its incidence is estimated at 6.3 cancers/year. In France, it is a cancer of the mature age, almost 85% after 65 years. In our observations, the patients were respectively 34, 46, 50 and 40 years old, with, an average age of 42.5 years and a sex ratio of 3/1. Benamr et al. [2] found an average age of 49 years with extremes of 17 years and 72 years while Ele et al. [3] returned to an average age of 55 years and a sex ratio of 2. Indeed, colon cancer has several risks factors: over 50 years of age, heredity, chronic inflammatory bowel, polyps; the bacterium *Fusobacterium nucleatum* would inhibit the action of immune cells and facilitate carcinogenesis. Similarly, obesity, diabetes, alcohol consumption and tobacco are established risk factors; some alimentary factors and regular physical activity seem to have a protective role [4]. No genetic investigation was made in our observations. It would have enabled us to determine the MSI (Micro Satellite Instability) or MSS (Micro Satellite Stability) phenotype linked to our cancers. This search for microsatellite instability has a therapeutic and prognostic value. Indeed, it is

recognized that colorectal cancers of MSI phenotype have a better prognosis and a lower sensibility to 5-fluorouracil chemotherapy [5].

Clinically, colon cancer can manifest as chronic abdominal pain, transit disorders such as constipation or diarrhea, internal digestive hemorrhage, which may be rectorrhagia or moelenas. General signs such as asthenia, weight loss, and disgust for some foods can be found [4]. In the serie of Benamr et al. [2], abdominal pain was found in 76% of cases, transit disorders in 53%, digestive haemorrhages in 36%, weight loss of more than 5 kg in 70% of cases; Anemia was found in 50% and an abdominal mass in 22% of cases. Complications such as peritonitis or occlusion may be indicative of the disease as the cases of our observations. It was the same in 10% of the serie of Benamr et al. [2]. Complications reached 42% of the Ele et al. [3]. Indeed, 15% of colon cancers are revealed by occlusion and 8% of colon cancers are revealed by peritonitis.

Apart from complications, a colonoscopy with a biopsy should be used to diagnose colon cancer and to plan its management [4,6]. Emergency surgery is an independent mortality factor for this colorectal surgery and occlusion and peritonitis are independent prognostic variables of colon cancer [7]. In our observations, the ulceronecrotic tumor of the right colon, the ulceronecrotic tumor of the cecum and the cecal tumor of the ileo-colic intussusception presented to us in Figure 1, benefited from a right hemicolectomy with an ileo-transverse anastomosis at the same time. The post-operative follow-up was favorable. The histological findings of the pieces of resection resulted respectively in a liberkühnian adenocarcinoma, a mucosecretant adenocarcinoma and a low-grade adenocarcinoma. As for the stenosing tumor of the sigmoid colon shown in Figure 2, it has benefited from a segmental colectomy according to Hartmann's procedure; the histological findings concluded to a mucosecretant adenocarcinoma. Restoration of continuity occurred 70 days after the initial surgery; the chemotherapy was indicated but was not administrated for lack of financial resources.

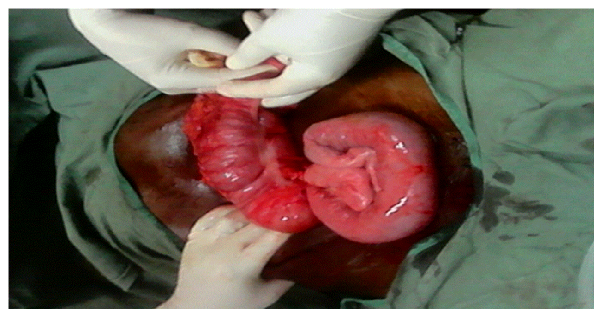


Figure 1: Clinical aspect of ileo-ceco-colic intussusception on cecal tumor.

In fact, the surgical risk is increased in the presence of acute complications, for Berdah [8]; the postoperative mortality of colon cancer in occlusions is 15-30%. Resecability was possible in our observations; On the other hand, it was 84% in the Benamr et al. serie [2]. Operative mortality has been observed 1 time out of 4 in our observations, but varies according to the series, from 1 to 10% [9]; in the serie of Benamr et al. [2], it was 5.51%. However, it reached 22.22% in the serie of Ele [3]; this high mortality in its serie would be explained by the high proportion of occlusive forms (42%).

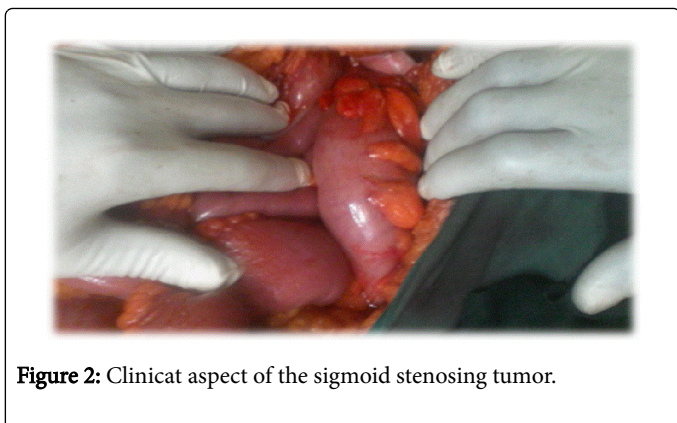


Figure 2: Clinicat aspect of the sigmoid stenosing tumor.

If, until 1980, surgery was the only treatment applicable to colon cancer, since 1990, adjuvant chemotherapy is essential for Dukes' C stages [9], but, it remains inaccessible in some poor areas. Indeed, in such regions of sub-Saharan Africa, this chemotherapy is geographically and financially inaccessible, which darkens the prognosis of colon cancer. According to the literature, survival at 5 years is in the range of 50-60% [9]. This prognosis can be improved by early diagnosis and appropriate management.

Conclusion

Colon cancer is a dreadful disease; it is not only limited to the elderly patients; the young people is also a susceptible population suffered colon cancer in poor areas. It is paucisymptomatic and its treatment remains a major preoccupation in sub-Saharan Africa, in view of the financial and geographical inaccessibility to chemotherapy. So, priority must be given to the prevention through education of populations to adopt a healthy lifestyle, and surveillance of subjects over 40 years of age, in order to reduce the burden of colon cancer.

Conflicts of Interest

The authors do not declare any conflict of interest.

Contribution of Authors

All the authors mentioned contributed to the writing of this manuscript.

References

1. Ferlay J, Faucher ES, Tiérentout JL, Coebergh JWW, Comber H, et al. (2013) Cancer incidence and mortality patterns in Europe : Estimates for 40 countries in 2012. *EJC* 49: 1374-1403.
2. Benamr S, Mohammadine E, Niamane R, Abbassi A, Essadel A, et al. (1996) Results of surgical treatment of colon cancer: *Médecine du Maghreb* 60: 27-33.
3. Ele N, Okiemy G, Lebeau R, Nkoua mbon JB, Mbombi pandi RI, et al. (2006) Cancer of the left colon at the CHU of Brazzaville. *Medical Mali* 21: 1-4.
4. Chevaux B (2014) Cancer colique: Mise au point Forum. *Med Suisse* 14: 289-294.
5. Buecher B, Pauw A, Fresneaux P, Rouleau E (2011) Instability of the microsatellitesand cancers colorectal microsatellite instability in colorectal Cancer. *Cancer Dig* 3: 200-204.
6. Winawer S, Fletcher R, Rex D, Bond J, Burt R, et al. (2003) Colorectal cancer screening and surveillance: clinical guidelines and rationale-Update based on new evidence. *Gastroenterology* 124: 544-560.
7. Tekkis PP, Kinsman R, Thompson MR, Stamatakis JD (2004) The association of coloproctology of great britain and irland study of large bowel obstruction caused by colo-rectal Cancer. *Ann Surg* 240: 76-81.
8. Berdah S (2013) Surgical treatment of colon cancer in occlusion. *PostU pp*: 49-54.
9. Boyle P, Ferlay J (2005) Cancer incidence and mortality in Europe. *Ann Oncol* 16: 481-488.