

Retreatment of a Mandibular Molar with Chronic Apical Abscess and Internal Root Resorption with the GentleWave® Procedure: A 16-Month Clinical Case Report

Randy W Garland*

Garland Endodontics, Encinitas, California, USA

*Corresponding author: Randy W Garland, Garland Endodontics, Encinitas, California, 92024, USA, Tel: +760-944-0048; Fax: +760-944-1432; E-mail: dr.rwgarland@gmail.com

Received date: February 08, 2017; Accepted date: February 23, 2017; Published date: March 01, 2017

Copyright: © 2017 Garland RW. This is an open-access article distributed under the terms of the Creative Commons Attribution License, which permits unrestricted use, distribution, and reproduction in any medium, provided the original author and source are credited.

Abstract

Introduction: Internal root resorption is a progressive loss of dentin in teeth with inflamed and possibly partially necrotic pulp tissue. If diagnosed at early stages, the process is halted by endodontic treatment. While endodontic treatment is the preferred treatment modality for internal root resorption, current standard endodontic techniques pose a challenge for cleaning, disinfection and obturation of these irregular and inaccessible areas, especially within the apical third.

Background: In the present clinical case report, a 57-year-old female patient presented on emergency basis with pain and swelling of the lower left side of her jaw. Extensive internal root resorption and a large periradicular lesion of the mesial root were identified during radiographic assessment of the mandibular left first molar which had in part undergone endodontic therapy but without apparent treatment of the mesial root.

Methods: Endodontic access was performed and purulent drainage was evident. After removal of the previous obturation material, the subject tooth underwent cleaning and disinfection of the root canal system using the GentleWave® Procedure. Obturation was completed with the absence of any clinically significant voids.

Results: At the 16-month reevaluation the patient was asymptomatic, radiographic analysis showed complete healing of the periradicular lesion and extensive healing of the alveolar bone. The case reported provides evidence for the use of the GentleWave Procedure in internal apical root resorption cases, even when inaccessible and irregular areas provide a challenge for standard techniques.

Keywords: GentleWave; Internal root resorption; Apical resorption; Chronic apical abscess; Healing

Introduction

Internal root resorption is a defect of the internal aspect of the root following loss of the odontoblastic layer, most commonly believed to be a result of chronic inflammation and bacterial invasion of the pulp [1]. During internal resorption, bacteria might reach the pulp through various routes such as lateral canals, carious cavities, cracks and dentinal tubules [2]. Continuous bacterial stimulation causes chronic inflammation of the pulp, transforming the normal pulp tissue into granulomatous tissue where osteoclasts or macrophages appear, resulting in dentinal resorption [3,4]. Pain or discomfort may be the chief complaint especially if the granulation tissue gets exposed to oral fluids. However, internal root resorption usually remains clinically asymptomatic and may be detected coincidentally during a routine radiographic evaluation, in which the lesion appears as radiolucent enlargement of the pulpal space [1,4]. Because of its asymptomatic nature, internal root resorption might go unnoticed until the lesion has caused a perforation or symptoms of acute or chronic apical periodontitis [5]. Management of internal root resorption may include an endodontic procedure to clean and obturate the root canals, if diagnosed at an early stage, or surgical intervention to remove the root

or a portion of it, if diagnosed at an advanced stage [6-8]. When treated endodontically, root canals with internal resorption present a different set of challenges for efficient cleaning of the affected area of the root. The challenges are posed by excess enlargement of the resorbed root canals and the irregular anatomies created by this resorption, hindering access of irrigation fluids and instruments to the canal surfaces [2,9,10].

Case Report

A 57-year-old female patient presented for emergency treatment reporting pain and swelling of the lower left side of her jaw after an airplane flight. The patient's medical history included Hepatitis C and long-term use of Harvoni® (Gilead Sciences, Foster City, CA) for the treatment of Hepatitis C. The rest of her medical history was not contradictory to any dental procedure. Radiographic examination revealed previous root canal therapy with only the distal canal of the left first mandibular molar (#19) obturated and extensive internal root resorption on the apical one-half of the mesial root with a large radiolucent periapical area (Figure 1). Clinical examination revealed slight sensitivity to percussion, mild painful response to palpation and mild swelling. The patient presented with a limited mouth opening, and a child size mouth prop was required during the procedure. Based on the clinical and radiographic findings, the patient was diagnosed

with chronic apical abscess (CAA). The clinical condition and the case difficulty due to internal root resorption and limited mouth opening was explained to the patient, endodontic treatment was proposed and accepted. Due to the emergent need of the patient and time constraints, the procedure was completed over two visits.

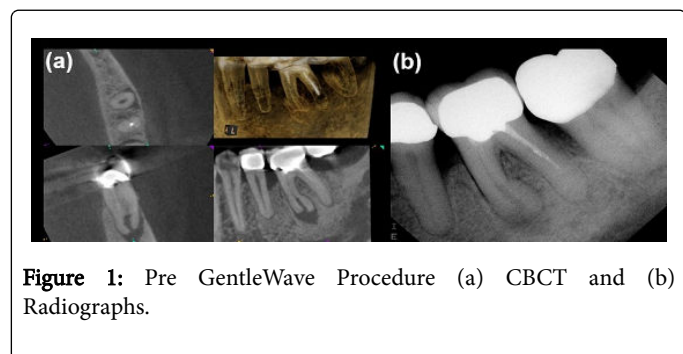


Figure 1: Pre GentleWave Procedure (a) CBCT and (b) Radiographs.

Procedure

Standard anesthesia (3% carbocaine plain, 4% septocaine with 1:100,000 epinephrine) was administered. Using dental dam isolation and dental operating microscope, the tooth was conservatively accessed wherein purulent drainage presented from the mesiolingual canal. At the first appointment, the distal canal was instrumented short of the working length utilizing ProTaper® retreatment files (Dentsply, Tulsa Dental Specialties, Tulsa, OK) and the mesiolingual and mesiobuccal canals using Edge X3 (EdgeEndo®, Albuquerque, NM) in conjunction with full strength sodium hypochlorite (8.25%). Calcium hydroxide (Multi-Cal™, Pulpdent®, Watertown, MA) was placed and a temporary filling material was utilized for restoration until final treatment. At the second appointment, the same standard anesthesia was administered. Using dental dam isolation and dental operating microscope, the tooth was re-accessed. Final apical enlargement was completed to full working length with a file size of #20.07. Cleaning and disinfection were performed using the GentleWave® Procedure (Sonendo, Laguna Hills, CA) (Figure 2) [11-13]. Canals were subsequently dried with absorbent paper points. Obturation was completed using a warm vertical technique with gutta percha and AH Plus® sealer (Dentsply, Tulsa Dental Specialties, Tulsa, OK) for the distal canal and a bioceramic paste on the mesiolingual and mesiobuccal canals due to the internal root resorption. The access cavity was then sealed with composite filling material and the patient was sent to the referring general dentist for final restoration. The patient did not report any intra- or post-op pain or discomfort, and was not prescribed any new analgesics.

Results

Two days post-procedure, the patient was contacted and reported no post GentleWave Procedure pain or discomfort.

Figure 1 exhibits the initial cone beam computed tomography (CBCT) and radiographs before the GentleWave Procedure. As demonstrated in the figure, the mesial root of the mandibular first molar has extensive internal root resorption and a large radiolucent area associated with the periapical lesion. Figure 1b depicts the root canal system prior to GentleWave Procedure with a partially completed endodontic procedure and obturated distal canal. The patient returned for clinical examination at 4-months post GentleWave Procedure. The subject tooth was clinically asymptomatic with normal mobility, soft

tissue and periradicular testing. The patient reported no pain or discomfort related to the subject tooth since the GentleWave Procedure. Radiographic examination was not completed at this time.

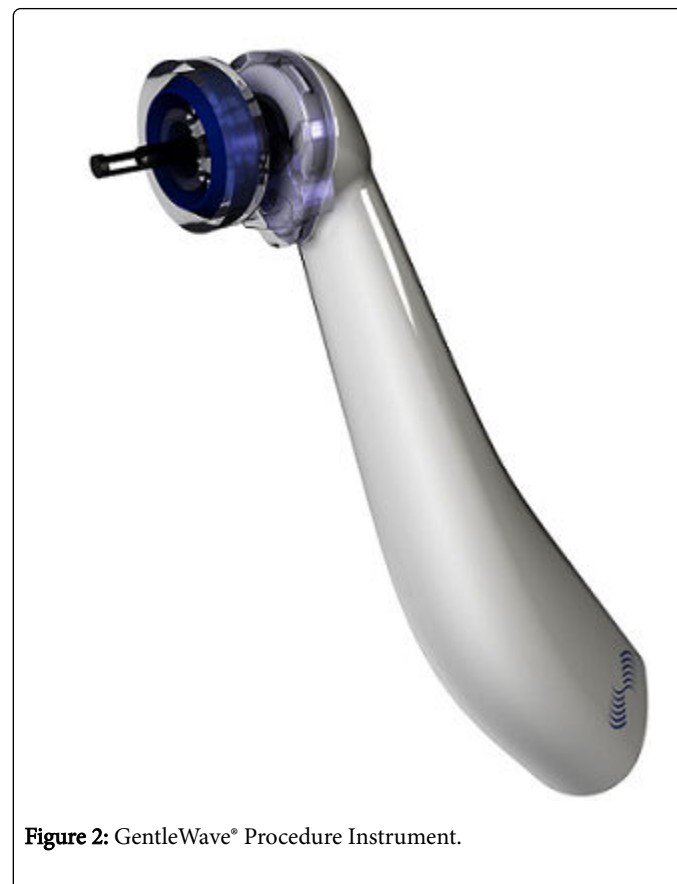

Figure 2: GentleWave® Procedure Instrument.

At 16 month post GentleWave Procedure reevaluation, the subject tooth remained asymptomatic to clinical examinations. Periradicular tests revealed no painful response to percussion and palpation testing. The subject tooth was negative for mobility, swelling, soft tissue lesions and furcation involvement. The patient continued to report no pain or discomfort related to the subject tooth since the procedure was completed. Radiographic evaluation (Figure 3) displays complete healing of the periradicular lesion and extensive healing of the alveolar bone.

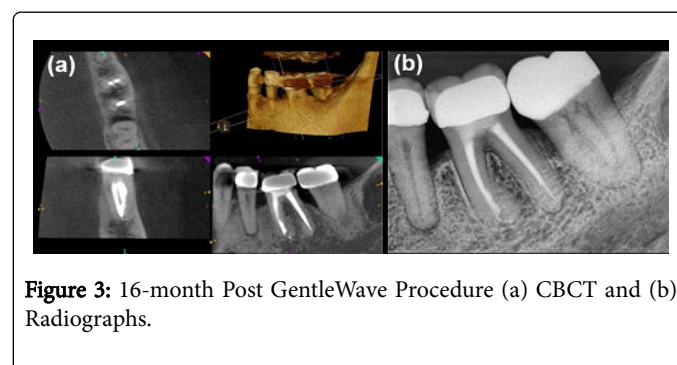


Figure 3: 16-month Post GentleWave Procedure (a) CBCT and (b) Radiographs.

Discussion

Internal root resorption, while being a progressive loss of dentin in teeth with inflamed and possibly partially necrotic pulp tissue, may not necessarily be treated successfully via standard endodontic methods [14]. While endodontic treatment is the preferred treatment modality for internal root resorption, there are other treatment options for internal root resorption which may depend on a variety of factors such as etiology, progression of disease, and location of the defect [2,15]. Management options for internal root resorption may include: no therapy, conservative endodontics, surgical endodontics, combined therapy, or extraction [15,16]. Early detection is key to non-surgical endodontic therapy because, if detected early, the resorption process can be halted [2,15]. The difficulty in standard endodontics facilitating cessation is the need for efficient debridement and disinfection [2,7,17]. Thus, the choice of which endodontic treatment modality to use for an internal apical resorption case is crucial to long-term success. Studies comparing the GentleWave System to standard rotary instruments and needle irrigation have indicated superior root canal debridement and disinfection [11,18]. This is necessary for apical internal resorption cases, especially cases in which the diagnosis has become as tenuous as in this case report with an acute phase of chronic apical abscess. In addition, studies have shown greater depth penetration of sodium hypochlorite, especially in the apical region, as well as minimal dentin erosion when using the GentleWave System [19,20]. This may be key to a successful outcome and preservation of tooth structure which is coveted in resorption cases. With these possible benefits to apical internal resorption cases and the long-term success of the GentleWave System shown in recent publications, the GentleWave Procedure was the preferred endodontic modality of treatment chosen for this case [12,13].

Internal root resorption presents a unique challenge for endodontic treatment because the affected root canals have undergone destruction of dentin and any aggressive instrumentation during the endodontic procedure could further undermine the already precarious tooth integrity and structure [2]. Furthermore, given the introduction of enlarged and restricted areas in the canal internal anatomy of internal root resorption cases, standard irrigation and instrumentation techniques might not be as efficient for canal debridement [2,9,10]. With the novel Multisonic Ultracleaning technology the internal root resorption case presented has revealed evidence of the entire root canal system being cleaned and disinfected with minimal dentin removal. The ability to fully clean and disinfect the root canal system with the GentleWave Procedure has been instrumental in facilitating not only the healing of the periradicular lesion but also that of alveolar bone regrowth. It should be noted that in the present case, even though the apical resorption was at an advanced stage leading to a relatively large apical foramen (Figure 1), no apical extrusion was evident during the GentleWave Procedure. This finding is supported by Charara et al. wherein the study indicates the GentleWave Procedure has a slight negative pressure, even with large apical openings, constituting no apical extrusion [14]. This case report supports evidence for the treatment of internal root resorption cases with inaccessible, enlarged or irregular root canal configurations by utilization of the GentleWave Procedure.

References

1. Altundasar E, Demir B (2009) Management of a Perforating Internal Resorptive Defect with Mineral Trioxide Aggregate: A Case Report. *J Endod* 35: 1441-1444.
2. Patel S, Ricucci D, Durak C, Tay F (2010) Internal Root Resorption: A Review. *J Endod* 36: 1107-1121.
3. Araujo LCG, Lins CV, Lima GA, Travassos RMC, Lins CCSA (2009) Study of Prevalence of Internal Resorption in Periapical Radiography of Anterior Permanent Teeth. *Int J Morphol* 27: 227-230.
4. Meire M, DeMoor R (2008) Mineral Trioxide Aggregate Repair of a Perforating Internal Resorption in a Mandibular Molar. *J Endod* 34: 220-223.
5. Frank AL, Weine FS (1973) Nonsurgical Therapy for the Perforative Defect of Internal Resorption. *J Am Dent Assoc*. 87: 863-868.
6. Asgary S, Eghbal MJ, Mehrdad L, Kheirieh S, Nosrat A (2014) Surgical Management of a Failed Internal Root Resorption Treatment: A Histological and Clinical Report. *Restor Dent Endod* 39: 137-142.
7. Nilsson E, Bonte E, Bayet F, Lasfargues JJ (2013) Management of Internal Root Resorption on Permanent Teeth. *Int J Dent* 2013: 929486.
8. Umashetty G, Hoshing U, Patil S, Ajgaonkar N (2015) Management of Inflammatory Internal Root Resorption with Biodentine and Thermoplasticised Gutta-Percha. *Case Rep Dent*: 452609.
9. Nair PN (2006) On the Causes of Persistent Apical Periodontitis: A Review. *Int Endod J* 39: 249-281.
10. Ricucci D, Langeland K (1998) Apical Limit of Root Canal Instrumentation and Obturation, Part 2. A Histological Study. *Int Endod J* 31: 394-409.
11. Molina B, Glickman G, Vandrangi P, Khakpour M (2015) Evaluation of Root Canal Debridement of Human Molars Using the GentleWave System. *J Endod* 41: 1701-1705.
12. Sigurdsson A, Garland RW, Le KT, Woo SM (2016) 12-month Healing Rates After Endodontic Therapy Using the Novel GentleWave System: A Prospective Multicenter Clinical Study. *J Endod* 42: 1040-1048.
13. Sigurdsson A, Le KT, Woo SM, Rassoulian SA, McLachlan K, et al. (2016) Six-month Healing Success Rates After Endodontic Treatment Using the Novel GentleWave™ System: The PURE Prospective Multi-center Clinical Study. *J Clin Exp Dent* 8: e290-e298.
14. Charara K, Friedman S, Sherman A, Kishen A, Malkhassian G, et al. (2016) Assessment of Apical Extrusion during Root Canal Irrigation with the Novel GentleWave System in a Simulated Apical Environment. *J Endod* 42: 135-139.
15. Bellamy C, Malkhassian G (2015) Root Resorption: An Overview and Case Report of Endodontic Management. *J Oral Health*.
16. Heithersay GS (1985) Clinical Endodontic and Surgical Management of Tooth and Associated Bone Resorption. *Int Endod J*, 18: 72-92.
17. Sak M, Radecka M, Karpinski TM, Wędrychowicz-Welman A, Szkaradkiewicz AK (2016) Tooth Root Resorption: Etiopathogenesis and Classification. *Micromedicine* 4: 21-31.
18. Vandrangi P, Basrani B (2015) Multisonic Ultracleaning in Molars with the GentleWave System. *J Oral Heal*: 72-86.
19. Vandrangi P (2016) Evaluating Penetration Depth of Treatment Fluids into Dentinal Tubules Using the GentleWave System. *Dentistry*. 6:366.
20. Wang Z, Maezono H, Shen Y, Haapasalo M (2016) Evaluation of Root Canal Dentin Erosion after Different Irrigation Methods Using Energy-dispersive X-ray Spectroscopy. *J Endod*. 42: 1834-1839.