

## Ropivacaine, versus Ropivacaine Plus Fentanyl for Carotid Endarterectomy

Hala Mostafa Goma\* and Ahmed Abd El Aziz Aref

Department of Medicine, Cairo University, Egypt

### Abstract

Carotid disease accounts for around 30% of all strokes. Regional anesthesia may have the advantage that early diagnosis of any neurological complications during surgery, also less cardiac, stroke 50%, less operating room stay, few shunts are needed, and lower cost.

**Patients and Methods:** After the sharing of regional anesthesia decision between patient, surgeon, and anesthesiologist, 20 patients were enrolled in this study. The patients were divided in 2 groups (n=10), group 1 (20 ml Ropivacaine 0.5% alone) and group 2 (20 ml Ropivacaine +2 µ/ml fentanyl). Following parameters were measured, onset, duration of the block, pain score, post operative stay time, postoperative nausea, vomiting, itching and patient satisfaction.

**Results:** Post operative stay minutes was 30.1 (2.22) in ropivacaine alone group and 13.7(3.4) in ropivacaine plus fentanyl group, P was 0.000. Post operative Nausea and vomiting 6 (30%) in Ropivacaine alone and 14 (70%) in ropivacaine plus fentanyl group, P was 0.011, postoperative pain was 80% in ropivacaine group and 0% in Ropivacaine with fentanyl group, postoperative itching was 40% in ropivacaine alone and 70% in fentanyl group. Patients' satisfaction was 90% in the fentanyl plus ropivacaine group.

**Discussion:** combination of fentanyl and Ropivacaine may be a great profit during deep cervical blockade, decreasing risk of hypertension and hyperglycemia in response to pain, so it reduces the risk of cardiac and neurological morbidity, decreasing hospital stay and cost. More studies are needed contain more number of patients with different ASA.

**Conclusions:** Ropivacaine plus fentanyl gave more intra and post operative analgesia, and for longer duration than ropivacaine alone. The usage of ropivacaine reduces the risk of motor fibers blockade of phrenic nerve, and neck muscles.

**Keywords:** Carotid endarterectomy; Ropivacaine; Fentanyl

### Introduction

Carotid artery disease is the result of atherosclerosis, if the obstruction of common carotid and the bifurcation of the common carotid artery or internal carotid artery occurred. The embolic phenomenon is the main cause of this obstruction. The role of collateral blood flow (circle of Willis and extracranial anastomosis channels) is very important. During endarterectomy the degree of ischemia and postoperative complications depends on the degree of dependency of cerebral circulation on the ipsi lateral internal carotid artery, and the efficiency of the collateral circulation. There is five folds increase in the incidence of perioperative stroke, with the presence of good cerebral blood flow during the surgery [1]. Regional anesthesia for carotid artery needs sharing of surgeon, anesthesiologist, and the patient. Regional anesthesia may have the advantage that early diagnosis of any neurological complications during surgery, also less cardiac, stroke 50%, less operating room stay, few shunts are needed, and lower cost [2,3]. Ropivacaine is a long-acting, enantiomerically pure (S-enantiomer) amide local anesthetic with a high pK and low lipid solubility which blocks nerve fibers involved in pain transmission (A $\delta$  and C fibers) to a greater degree than those controlling motor function (A $\beta$  fiber). The drug was less cardio toxic than equal concentrations of racemic bupivacaine [4]. Many studies demonstrated that addition of fentanyl increase the analgesic effect, and more short onset of action of ropivacaine in epidural analgesia and anesthesia [5]. Aim of the study is to compare deep cervical block when ropivacaine used alone and when combined with fentanyl in carotid endarterectomy.

### Patients and Methods

After the sharing of regional anesthesia decision between patient, surgeon, and anesthesiologist, 20 patients were enrolled in this study.

The patients were divided in 2 groups (n=10), group 1 (ropivacaine alone) and group 2 (ropivacaine plus fentanyl). Exclusion criteria were confusion or drowsiness, blood pressure more than 160/100, ejection fraction less than 25%, prothrombin concentration less than 60% uncontrolled diabetes.

Preoperative investigations include, Hb, serum sodium and potassium, urea and creatinine, liver function test, ECG, echocardiography.

All medication for cardiac, hypertension, diabetes should be taken preoperatively, fasting 9 hours, IV line, no premedication was given.

In operating room full monitoring was used, ECG, non invasive

**\*Corresponding author:** Hala Mostafa Goma, Assistant professor of anesthesia, Department of Medicine, Cairo University, Egypt, Tel: 20235676105; E-mail: [ahmeda1995@yahoo.com](mailto:ahmeda1995@yahoo.com)

**Received** May 03, 2014; **Accepted** May 06, 2014; **Published** May 08, 2014

**Citation:** Goma HM, Aref AAEA (2014) Ropivacaine, versus Ropivacaine Plus Fentanyl for Carotid Endarterectomy. J Anesth Clin Res 5: 404. doi:10.4172/2155-6148.1000404

**Copyright:** © 2014 Goma HM, et al. This is an open-access article distributed under the terms of the Creative Commons Attribution License, which permits unrestricted use, distribution, and reproduction in any medium, provided the original author and source are credited.

blood pressure, pulse oximeter, oxygen by nasal canula. No premedication.

The patient is in the supine or semi-sitting position with the head facing away from the side to be blocked. A deep cervical plexus block is essentially a paravertebral block of the C2, C3, and C4 spinal nerves as they emerge from the foramina of the respective vertebrae. Blockade of the deep cervical plexus also results in the blockade of the superficial cervical plexus. To estimate the line of needle insertion that overlies the transverse processes, the mastoid process (MP) and Chassaignac's tubercle of C6 transverse process are identified and marked. The transverse process of C6 is usually easily palpated behind the clavicular head of the sternocleidomastoid muscle at the level just below the cricoids cartilage. Next, a line is drawn connecting the mastoid process (MP) to Chassaignac's tubercle of C6 transverse process. The palpating hand is best positioned just behind the posterior border of the sternomastoid muscle. Once this line is drawn, the insertion sites over the C2, C3, and C4 are as follows: the C2, C3, and C4 are located on the MP-C6 line some 2-cm, 4-cm, and 6-cm caudal from the mastoid process, respectively. The needle is advanced slowly until the transverse process is contacted. At this point, the needle is withdrawn 1-2 mm, firmly stabilized, and 4 mL of local anesthetic is injected, after a negative aspiration test for blood. Total injected dose is 20 ml of Ropivacaine 0.5% alone in group 1 and 20 ml of Ropivacaine plus 2 µ/ml of fentanyl in group 2.

Following parameters were measured, onset ,duration of the block, pain score, post operative stay time ,postoperative nausea, vomiting, itching and patient satisfaction. Statistical methods were by using SPSS PROGRAM Version 15, Chi-square test and, Mann Whitney tests for post operative times (Table 1).

## Results

	Group 1 (ropivacaine alone)	Group 2 (ropivacaine plus fentanyl)	P value
Age (yr)	57.2 (6.8)	56.6 (6.7)	0.876
Sex (m/f)	8/2 (80%)	8/2 (80%)	1.000

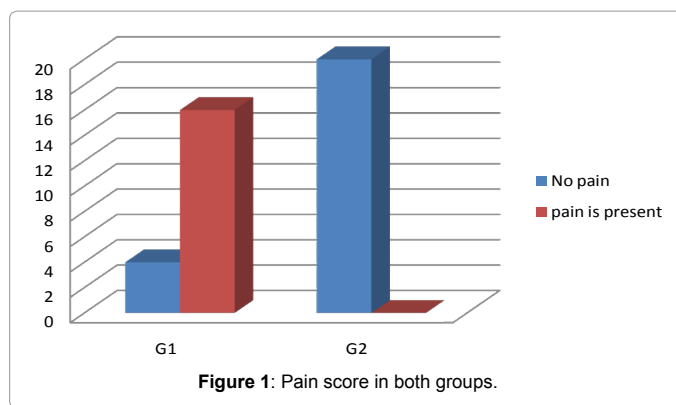
**Table 1:** Shows the demographic data of both groups, there was insignificant difference between 2 groups. P ≤ 0.05 considered significant.

	Group 1 (ropivacaine alone)	Group 2 (ropivacaine plus fentanyl)	P value
Post operative stay minutes	30.1 (2.22) 28-35 (29)	13.7(3.4) 10-25 (14)	0.000
Post operative Nausea and vomiting (%)	6 (30%)	14 (70%)	0.011
Postoperative Pain (%)	16 (80%)	0 (0%)	0.000
Postoperative itching (%)	8 (40%)	14 (70%)	0.000
Patient satisfaction (%)	8 (40%)	18 (90%)	0.001

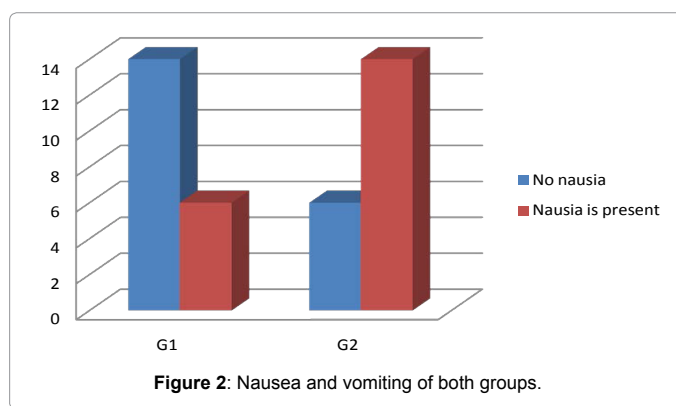
**Table 2:** Post operative pain, nausea, vomiting, itching, and patient's satisfaction. P ≤ 0.05 considered significant.

	Group 1 (ropivacaine alone)	Group 2 (ropivacaine plus fentanyl)	P value
Onset of the block (min)	17.4 (2.0) 15-22 (17)	10.2 (1.4) 8-12 (10)	0.001
Duration of the block (hours)	6.5 (0.5) 6-7 (6)	9.5 (0.5) 9-10 (9)	0.000
Pain score	1.2 (1.2) 0-3 (1)	0.8 (0.8) 0-2 (1)	0.000

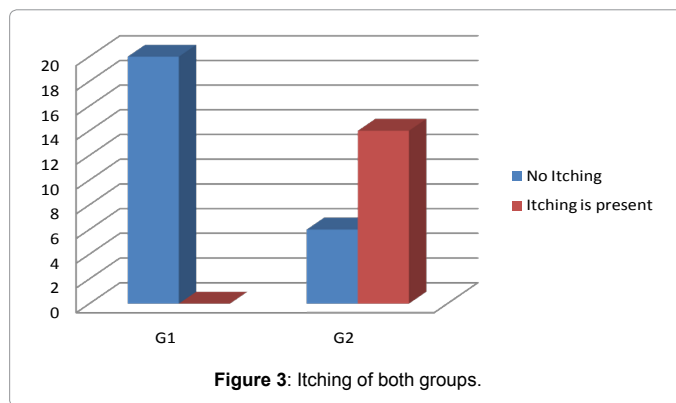
**Table 3:** Onset of the block, duration of the block, pain score.



**Figure 1:** Pain score in both groups.



**Figure 2:** Nausea and vomiting of both groups.



**Figure 3:** Itching of both groups.

Table 2, shows that there were significant difference in post operative stay time, it was higher in group1 (ropivacaine alone). Also post operative nausea and vomiting was 70% in fentanyl group and 30% in group 1. Itching was 70% in group 2(fentanyl group) which is significantly high, while it was (0%) in group 1. patients satisfaction was 90% in group 2, and 40% in group 1.

Table 3 showed that the onset of the block was significantly shorter in fentanyl group, the duration of the block was significantly longer in group 2 (ropivacaine plus fentanyl), and pain score is significantly lower in group 2.

Figures 1, 2, 3 show pain score, nausea and vomiting and itching between two groups.

## Discussion

Carotid disease accounts for around 30% of all strokes. Carotid

artery surgery is essentially a preventative operation as it is performed to decrease the risk of the patient developing a stroke. General anesthesia offers advantages of a secure airway and control of arterial carbon dioxide concentration and permits the use of cerebral protection including mild hypothermia. The disadvantages include more difficult hemodynamic control and the problem of monitoring cerebral perfusion [6]. Some studies suggest that, regional anesthesia results in a reduction in the incidence of shunt placement in centers where shunting is performed electively, less cardiac morbidity [7]. Two series events may occurred intra and post operatively are hypertension, and hyperglycemia. The good intraoperative anesthesia and post operative analgesia are important to prevent these events. Patients have systolic hypertension on a great risk of development neurological deficits more than normotensive patients. Sudden increase in systolic blood pressure can leads to hyper perfusion syndrome and then intra cerebral hemorrhage. Hyperglycemia as result of pain may leads to irreversible damage for the ischemic part of the brain. There is some evidence that this instability is less frequent when regional anesthesia has been used [8,9]. Blockade of the deep cervical plexus also results in the blockade of the superficial cervical plexus. The most common clinical use for this block in our practice includes a carotid endarterectomy [10,11]. So this study was planned to compare ropivacaine when used alone and when fentanyl was added in deep cervical block for carotid endarterectomy, the study found that, the onset of the block was shorter with longer duration of action, and more post operative analgesia, less stay in postoperative ICU or recovery room when fentanyl was added. Ropivacaine has mainly sensory blockade, that decrease risk of phrenic nerve, and neck muscles blockade, that occurred with deep cervical blockade [12]. Many studies found the beneficial effect of addition of fentanyl to ropivacaine during epidural analgesia for normal labor [5]. The combination of fentanyl and Ropivacaine may be a great profit during deep cervical blockade, decreasing risk of hypertension and hyperglycemia in response to pain, so it reduces the risk of cardiac and neurological morbidity, decreasing hospital stay and cost. More studies are needed contain more number of patients with different ASA.

## Conclusions

Ropivacaine plus fentanyl gave more intra and post operative

analgesia, and for longer duration than Ropivacaine alone. The usage of Ropivacaine reduces the risk of motor fibers blockade of phrenic nerve, and neck muscles. More studies included more number of patents with different ASA may be needed.

## References

1. Rothwell PM, Eliasziw M, Gutnikov SA, Fox AJ, Taylor DW, et al. (2003) Analysis of pooled data from the randomised controlled trials of endarterectomy for symptomatic carotid stenosis. *Lancet* 361: 107-116.
2. Vaniyapong T, Chongruksut W, Rerkasem K (2004) Local versus general anaesthesia for carotid endarterectomy. *Cochrane Database Syst Rev* CD000126.
3. Rerkasem K, Rothwell PM (2008) Local versus general anaesthetic for carotid endarterectomy. *Stroke* 36: 169-170.
4. Zink W, Graf BM (2004) Benefit-risk assessment of ropivacaine in the management of postoperative pain. *Drug Saf* 27: 1093-1114.
5. Ferrer Gómez C, Saludes Serra J, Tello Galindo I, Gómez Montemayor E, Bella Romera S, et al. (2000) [0.2% ropivacaine vs. 0.1% ropivacaine plus fentanyl in obstetric epidural analgesia]. *Rev Esp Anestesiol Reanim* 47: 332-336.
6. GALA Trial Collaborative Group1, Lewis SC, Warlow CP, Bodenham AR, Colam B, et al. (2008) General anaesthesia versus local anaesthesia for carotid surgery (GALA): a multicentre, randomised controlled trial. *Lancet* 372: 2132-2142.
7. Bowyer MW, Zierold D, Loftus JP, Egan JC, Inglis KJ, et al. (2000) Carotid endarterectomy: a comparison of regional versus general anesthesia in 500 operations. *Ann Vasc Surg* 14: 145-151.
8. Sternbach Y, Illig KA, Zhang R, Shortell CK, Rhodes JM, et al. (2002) Hemodynamic benefits of regional anesthesia for carotid endarterectomy. *J Vasc Surg* 35: 333-339.
9. Cederholm I (1997) Preliminary risk-benefit analysis of ropivacaine in labour and following surgery. *Drug Saf* 16: 391-402.
10. Benzon HT, Raja SN, Borsook D, Molloy RE, Strichartz G (1999) *Essentials of Pain Medicine and Regional Anesthesia*. Churchill Livingstone, Philadelphia, USA.
11. Brown DL (1992) *Atlas of Regional Anesthesia*. Saunders, Philadelphia, USA.
12. Emery G, Handley G, Davies MJ, Mooney PH (1998) Incidence of phrenic nerve block and hypercapnia in patients undergoing carotid endarterectomy under cervical plexus block. *Anaesth Intensive Care* 26: 377-381.

Citation: Goma HM, Aref AAEA (2014) Ropivacaine, versus Ropivacaine Plus Fentanyl for Carotid Endarterectomy. J Anesth Clin Res 5: 404. doi:10.4172/2155-6148.1000404

## Submit your next manuscript and get advantages of OMICS Group submissions

### Unique features:

- User friendly/feasible website-translation of your paper to 50 world's leading languages
- Audio Version of published paper
- Digital articles to share and explore

### Special features:

- 350 Open Access Journals
- 30,000 editorial team
- 21 days rapid review process
- Quality and quick editorial, review and publication processing
- Indexing at PubMed (partial), Scopus, EBSCO, Index Copernicus and Google Scholar etc
- Sharing Option: Social Networking Enabled
- Authors, Reviewers and Editors rewarded with online Scientific Credits
- Better discount for your subsequent articles

Submit your manuscript at: <http://www.omicsonline.org/submission>