

Scrub Typhus Complicated by Pneumonia and Acute Kidney Injury: Still an Underrecognized Scenario in West Bengal

Saurabh Pandey*, Manoj Kumar Gupta, Nazneen Nahar Begum, Kumkum Sarkar, Debananda Gonjhu and Netai Pramanik

Department of Tropical Medicine, School of Tropical Medicine 108 C R Avenue, Kolkata, India

*Corresponding author: Saurabh Pandey, Department of Tropical Medicine, School of Tropical Medicine 108 C R Avenue, Kolkata, India, Tel: 9038000728; E-mail: saurabh2013@gmail.com

Received date: April 01, 2017; Accepted date: June 30, 2017; Published date: July 07, 2017

Copyright: © 2017 Pandey S, et al. This is an open-access article distributed under the terms of the Creative Commons Attribution License, which permits unrestricted use, distribution, and reproduction in any medium, provided the original author and source are credited.

Abstract

Scrub typhus is an emerging and reemerging disease in India and increasingly important cause of acute febrile illness. It is usually complicated by various organ dysfunctions, and is diagnosed by serology. We are reporting a case of 34 years old man resident of West Bengal presented to us with complaints of fever for 7 days with features of pneumonitis and Acute Kidney Injury (AKI). He received doxycycline after positive serology of IgM Scrub typhus, and responded very well. In tropical region any short duration fever with pneumonia, AKI with leukocytosis scrub typhus should be kept in differential as it is a fairly treatable and significantly under diagnosed condition.

Keywords: Scrub typhus; Pneumonia; Acute kidney injury

Introduction

Scrub typhus is an emerging and reemerging disease with reference to Asia especially India. Scrub typhus is the commonest occurring rickettsia infection in India and increasingly important cause of acute febrile illness. There is a recent introduction of better diagnostic facilities at many centers in the country diagnosis of this disease is becoming possible and many large scale studies have come up.

All across the globe endemic region of scrub is famously described by "tsutsugamushi triangle. Rickettsiosis, of which scrub is the commonest, has been clearly reported from several states in India including Jammu and Kashmir, Himachal Pradesh, Uttarakhand, Bihar, West Bengal, Meghalaya, Rajasthan, Maharashtra, Karnataka, Tamil Nadu and Kerala [1-4]. A review by Laskar et al. [5] of scrub typhus studies in last 10 years across India showed absence of study from West Bengal. Only one reported literature from Darjeeling by Tulshi Pramanik et al. [6] is on scrub typhus.

Classically it is acute febrile illness with an eschar. Complications can include any system which is usually after first week of illness and common one includes- jaundice, renal failure, pneumonitis, acute respiratory distress syndrome (ARDS), septic shock, myocarditis and meningoencephalitis [7,8]. Weil Felix is still used as most commonly used test although ELISA for immunoglobulin M (IgM) of *O. tsutsugamushi* derived recombinant antigen mixture has come up as better test [9].

We report a case of scrub typhus infection with pneumonia and AKI, which is currently under recognized scenario in West Bengal.

Case Presentation

A 34 years old man presented to us with complaints of high grade fever for 7 days, associated with generalized myalgia specially calf muscles and thighs along with reddening of both eyes. There was progressive, mild productive and persistent cough and chest pain after

3 days. Examination showed pallor, bilateral conjunctiva suffusion, blood pressure of 87/53 mmHg, pulse 108/min regular and feeble, respiratory rate of 34/min, distress. Chest showed B/L crepitations more on right side and adequate air entry (Figure 1). Rest all other systems were within normal limit.

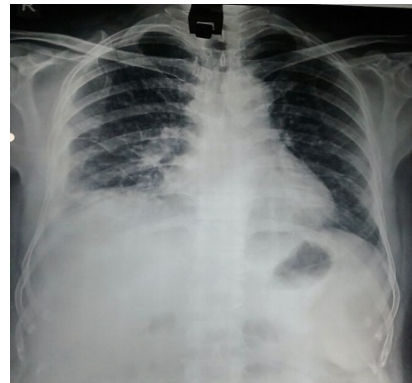


Figure 1: Chest X-ray showing right side pneumonitic changes.

He was started on ceftriaxzone injections and Azithromycin and investigations were sent on first day. Hb was 6.8 g/dl, microcytic hypochromic; Total Leukocyte count (TLC) was $1.3 \times 10^9/L$ with 81% polymorphs, normal platelet count. Serum alanine aminotransferase and serum aspartate aminotransferase were 73 and 146, creatinine=1.2 mg/dl, normal albumin, globulin, bilirubin, urea, and alkaline phosphatase. He came negative for leptospirosis, dengue, enteric fever, viral hepatitis A, B, C, E, HIV and malaria. After two days he had developed acute kidney injury of AKIN stage 1 with urea, creatinine of 39 mg/dl and 1.7 mg/dl respectively. Day 3 patient was still febrile and cough and respiratory distress significantly increased so shifted to ICU. He was started on injection meropenem and next 3 days fever reduced in intensity but not in frequency also and cough persisted. On 7th day he came positive for immunoglobulin (Ig) M ELISA for scrub typhus

with a dilution of $>1:100$. He was given tablet doxycycline (100 mg, twice daily) and over next 4 days he completely improved in terms of fever, cough, appetite and urinary symptom. After 7 days all blood parameters came normal and he was discharged with iron supplementation and investigation for iron deficiency anemia. Patient came for follow up after 2 weeks and was perfectly fine.

Discussion

Pulmonary complications are among commonest in scrub typhus. It may range from uncomplicated pneumonia to ARDS. It is generally interstitial type and has a lower zone predilection. The central pathology is pulmonary vasculature endothelial damage and increased vascular permeability. Strickman et al. and Park et al. suggested systemic vasculitis and immunological mechanism respectively [10,11]. Multiple studies from different states have determined occurrences of pneumonia like Vikrant et al. showed pneumonia and ARDS were in 10.9% and 11.5% patients of scrub typhus respectively [12].

AKI was defined as per Acute Kidney Injury Network (AKIN) classification and definition [13]. AKI was one of important presentation and it frequently complicates the course of the disease. Study by Attur et al. and Vivek et al. showed AKI was present in about 40% and 53% of cases respectively [14,15]. Our patient had AKIN stage 1 AKI and completely recovered after treatment. Kumar et al. had 29% patients with Stage 1 AKI. A striking finding is that Indian studies have shown a much higher prevalence of AKI in comparison to other literature. Jaundice, oliguria, ARDS and AKI were associated with mortality in study by Vivek et al. [15].

Our patient had received Azithromycin but was incompletely relieved of symptoms and complete response was to oral doxycycline indicating it as most effective medication for scrub typhus infection as mentioned by the literature [9].

Conclusion

In monsoon season any short duration fever with pneumonia, AKI with leukocytosis scrub typhus should always be ruled out because it is a fairly treatable condition and significantly under diagnosed.

References

1. Mahajan SK, Rolain JM, Kashyap R, Bakshi D, Sharma V, et al. (2006) Scrub typhus in Himalayas. *Emerg Infect Dis* 12: 1590-1592.
2. Chrispal A, Boorugu H, Gopinath KG, Prakash JA, Chandy S, et al. (2010) Scrub typhus: an unrecognized threat in South India- Clinical profile and predictors of mortality. *Trop Doc* 40: 129-133.
3. Mahajan SK, Kashyap R, Kanga A, Sharma V, Prasher BS, et al. (2006) Relevance of Weil-Felix test in diagnosis of scrub typhus in India. *J Assoc Physicians India* 54: 619-621.
4. Batra HV (2007) Spotted fevers and typhus fevers in Tamil Nadu. *Indian J Med Res* 126: 101-103.
5. Laskar AR, Suri S, Acharya AS (2015) Scrub typhus: Remerging public health problem in India. *J Commun Dis* 47: 19-25. <https://www.wbhealth.gov.in>
6. Mathai E, Rolain JM, Verghese GM, Abraham OC, Mathai D, et al. (2003) Outbreak of scrub typhus in southern India during cooler months. *Ann N Y Acad Sci* 990: 359-364.
7. Paris DH, Shelite TR, Day NP, Walker DH (2013) Review article: Unresolved problems related to scrub typhus: A seriously neglected life-threatening disease. *Am J Trop Med Hyg* 89: 301-307.
8. Ramasubramanian V, SenthurNambi P, Muruganathan A (2013) The association of physicians of India (1st edn). *Medicine Update*. pp: 19-22.
9. Park JS, Jee YK, Lee KY, Kim KY, Myong NH, et al. (2000) Acute respiratory distress syndrome associated with scrub typhus: Diffuse alveolar damage without pulmonary vasculitis. *J Korean Med Sci* 15: 3433-345.
10. Strickman D, Smith CD, Corcoran KD, Ngampochjana M, Watcharapichat P, et al. (1994) Pathology of Rickettsia tsutsugamushi infection in Bandicotasavilei, a natural host in Thailand. *Am J Trop Med Hyg* 51: 416-423.
11. Vikrant S, Dheer SK, Parashar A, Gupta D, Thakur S, et al. (2013) Scrub typhus associated acute kidney injury--a study from a tertiary care hospital from western Himalayan State of India. *Ren Fail* 35: 1338-1343.
12. Mehta RL, Kellum JA, Shah SV, Molitoris BA, Ronco C, et al. (2007) Acute kidney injury network. Acute kidney injury network: report of an initiative to improve outcomes in acute kidney injury. *Crit Care* 11: R31.
13. Attur RP, Kuppasamy S, Bairy M, Nagaraju SP, Pammidi NR, et al. Acute kidney injury in scrubtyphus. *Clin Exp Nephrol* 17: 725-729.
14. Vivek K, Kumar V, Yadav AK, Iyengar S, Bhalla A, et al. (2014) Scrub typhus is an under-recognized cause of acute febrile illness with acute kidney injury in India. *PLoS Negl Trop Dis* 8: e2605.