

Severe Diabetic Ketoacidosis and Acute Pancreatitis Precipitated by Olanzapine in a Nondiabetic Patient

Vikash Singh¹, Pradipta Bhakta^{1*}, Sabir Saeed², Rajesh Kumar Jain³

¹Department of Anaesthesia and Intensive care, Our Lady of Lourdes Hospital, Drogheda, Ireland

²Department of Anesthesiology and Perioperative Medicine and Pain Management, University of Saskatchewan, Moose Jaw Union Hospital, 455 Fairford Street E S6H 1H3, Canada

³Locum Consultant, Adelaide and Meath Hospital, Department of Anaesthesia and Intensive Care, AMCNH, Tallaght, Dublin, Ireland

Abstract

Olanzapine, a second generation or atypical antipsychotic, is one of the commonly prescribed antipsychotics and has lower incidence of extrapyramidal side effects, sedation and anticholinergic side effects. Atypical antipsychotics like olanzapine are now widely prescribed for treatment of schizophrenia as well as for schizoaffective disorder, bipolar affective disorder, depression and dementia. Olanzapine, has been reported to cause metabolic dysregulation like weight gain, type II diabetes mellitus and hyperlipidemia as compared to conventional antipsychotics. Sometimes patient taking olanzapine may present in acute deterioration like diabetic ketoacidosis complicated with acute pancreatitis. Hereby we are reporting a young patient who presented with life threatening severe diabetic ketoacidosis complicated with acute pancreatitis and acute kidney injury which resolved after withdrawal of olanzapine and with supportive care and Insulin. Combination of diabetic ketoacidosis, acute pancreatitis and acute kidney injury induced by olanzapine is very rarely reported.

Keywords: Olanzapine; Diabetic ketoacidosis; Acute pancreatitis; Acute kidney injury

Introduction

Olanzapine, a second generation or atypical antipsychotic (AAP), is one of the commonly prescribed antipsychotics as it is effective on both positive and negative symptoms of schizophrenia and has lower incidence of extrapyramidal side effects, sedation and anticholinergic side effects, thus is well tolerated by the patients [1-6]. Olanzapine is a thienobenzodiazepine derivative which is structurally related to clozapine [4,6-9] but is not associated with agranulocytosis [5,6]. Along with dopamine (D_1 , D_2 , D_4) receptor blockade, which is lesser than first generation antipsychotics, second generation antipsychotics also block histaminergic (H_1), muscarinic (M_3), adrenergic (α_1 , α_2 and β_3) and serotonergic (5-HT_{2A}, 5-HT_{2C}) receptors which results in lesser extrapyramidal side effects, but in addition brings problem like metabolic dysregulation [4,8,9]. AAP like olanzapine are now widely prescribed for treatment of schizophrenia as well as for schizoaffective disorder, bipolar affective disorder, depression and dementia [5,6,10]. Somnolence, orthostatic hypotension, agitation, insomnia, headache, dizziness, hyperprolactinemia and weight gain are commonly reported side effect of olanzapine [4,5,8,9]. Olanzapine, has been reported to cause metabolic dysregulation like weight gain, type II diabetes mellitus and hyperlipidemia as compared to conventional antipsychotics [1-3,5,6,10-12]. Sometimes patient taking olanzapine may present in acute deterioration like diabetic ketoacidosis (DKA) complicated with acute pancreatitis [7,9,11,12]. Hereby we are reporting a young patient who presented with life threatening severe DKA complicated with acute pancreatitis and acute kidney injury (AKI).

Case Report

A thirty-four year old man diagnosed with depression presented to our emergency department with low Glasgow Coma Scale (GCS) score of 4/15 complicated with hypotension (systolic blood pressure <80 mmHg), hyperglycemia (70 mmol/L, urine glucose: 3+), acidosis (pH: 7.001, base excess: -25.6, bicarbonate: 6.3), hypocarbia (PaCO₂: 2.2 kPa), hyperkalemia (Potassium: 6.4 mmol/L) and ketonuria (6 mmol/L, urine ketone: 3+). His electrocardiogram showed sinus tachycardia with tall peaked T waves (Figure 1). His toxicology screen was negative for any addictive substance. He had complains of abdominal pain for one

day, nausea and vomiting, polyuria and was unwell for last one week. On examination he was found to be obtunded with gross dehydration and his abdomen was distended and rigid. He was a diagnosed case of depression, childhood asthma and had his right arm amputated since birth (phocomelia). He was not obese and he did not have any history of diabetes mellitus (DM) though he had positive family history of diabetes from his father's side. He was non smoker and was not a regular alcoholic. He was on olanzapine (10 mg once daily) and esitalopram (10 mg once daily) for depression for last eighteen months. Though we do not have his blood sugar level before starting olanzapine, but according to the patient he was never detected diabetic before this episode. Patient was managed in the emergency department with resuscitative measures. He was intubated and ventilated and then transferred to the intensive care unit (ICU) where he was diagnosed to have DKA complicated with AKI based on his laboratory parameters (Table 1) and was managed as per institute's DKA protocol with intensive rehydration and insulin infusion. His blood investigations showed high level of serum amylase (402), urea (15.6 mmol/L), creatinine (377 mmol/L), and HbA1c (146 mmol/mol) (Table 1). Serum triglyceride was elevated, but serum calcium was within normal limit (Table 1). Computed tomographic scan of abdomen showed features of acute pancreatitis (small fluid collection around head of pancreas, no pseudocyst, no calcification, no liver enlargement, mild splenomegaly, small pleural effusion, bilateral basal lung consolidation) (Figure 2). There was no evidence of any infection or gall stone. Unfortunately serum lipase which is more specific for acute pancreatitis was not done in our case. Considering olanzapine as the most probable offending agent, it was discontinued. His AKI and

***Corresponding author:** Pradipta Bhakta, Department of Anaesthesia and Intensive care, Our Lady of Lourdes Hospital, Drogheda, Ireland, Tel: 00353-894137596; E-mail: bhaktadr@hotmail.com

Received February 22, 2015; **Accepted** March 27, 2015; **Published** March 29, 2015

Citation: Singh V, Bhakta P, Saeed S, Jain RK (2015) Severe Diabetic Ketoacidosis and Acute Pancreatitis Precipitated by Olanzapine in a Nondiabetic Patient. J Clin Case Rep 5: 501. doi:10.4172/2165-7920.1000501

Copyright: © 2015 Singh V, et al. This is an open-access article distributed under the terms of the Creative Commons Attribution License, which permits unrestricted use, distribution, and reproduction in any medium, provided the original author and source are credited.

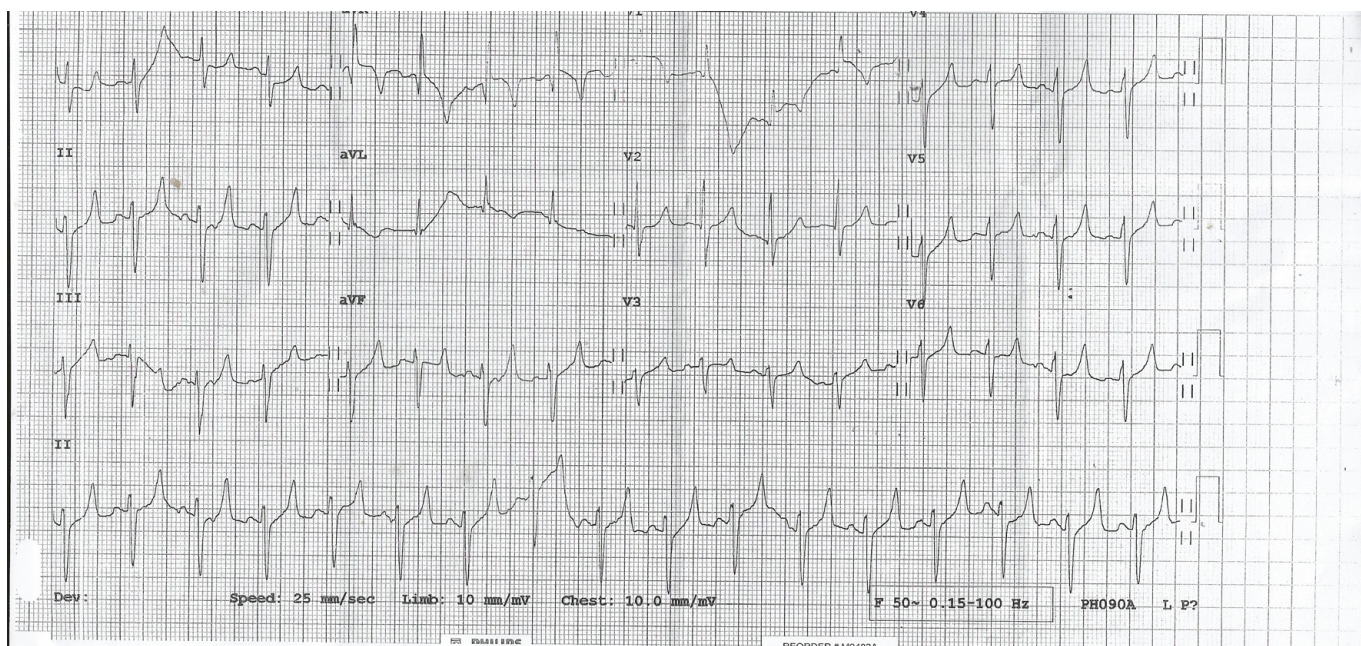


Figure 1: Electrocardiogram showed sinus tachycardia with tall peaked T waves.

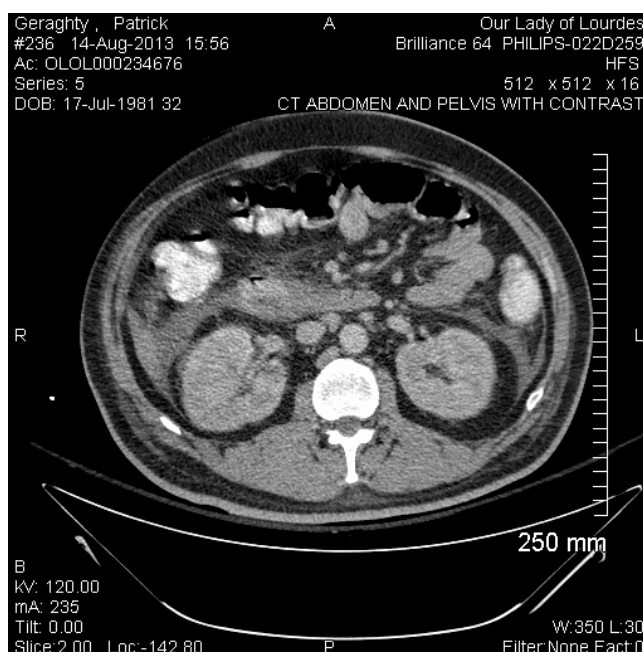


Figure 2: Computed tomographic scan of abdomen showed features of acute pancreatitis.

pancreatitis resolved with supportive management after discontinuing olanzapine and he did not require any dialysis. He was weaned off the ventilator and was extubated after two days. He was discharged to medical ward after two more days. During his stay in the ICU and subsequently in the medical ward, his blood sugar was monitored and he was treated with insulin. After his sugar was controlled with DKA regimen he was put on regular insulin. The patient's insulin requirement subsequently came down. He was diagnosed to have new onset type II DM. He was prescribed haloperidol for his depression and

was discharged home on dietary advice, haloperidol and insulin after one week. In spite of discontinuation of olanzapine he was requiring insulin for control of his blood sugar eight months after discharge. His depression is currently controlled with ecitalopram and haloperidol.

Discussion

Our case once again proved that use of olanzapine in psychiatric patient can lead to life threatening complications like DKA and acute pancreatitis. His AKI was most probably induced by hypotension

Investigation parameters (Normal Range)	On Admission	On ICU admission	On ICU discharge	On Hospital discharge	8 months after
Haemoglobin (gm/dL)	14.6	13	10	10.4	14
White Blood Cells ($3.5-12 \times 10^9/L$)	18.9	12.5	6.0		5.2
Platelet ($150-400 \times 10^9/L$)	247	224	120		212
PT (Sec)	15.2	15.3	14		
INR	1.2	1.2	1.1		
C-Reactive Protein (<10 mg/L)	131	243	108.4		
Blood Urea (2.5-7.1 mmol/L)	15.6	14	3.5		5.6
Serum Creatinine (50-110 $\mu\text{mol/L}$)	377	306	70		82
Serum Sodium (mmol/L)	132	143.7	141		138
Serum Potassium (mmol/L)	6.5	4.53	3.6		4.6
Lactate (0.5-1.6 mmol/L)	1.8	1.1			
Blood Glucose (mmol/L)	73	>30	17.4	9.8	
Ketone (mmol/L)	6	4			
pH (7.35-7.45)	7.001	6.915			
PaCO ₂ (4.6-6 kPa)	2.2	3.77			
PaO ₂ (12-13 kPa)	28.43	30.16			
HCO ₃ (23-29 mmol/L)	6.5	6.5			
Serum Amylase (26-102 units/L)		402	35		
HbA1C (4-6%)			15.5		5.3
Serum Cholesterol (<5.2 mmol/L)		5.18			4.3
Serum Triglyceride (0.45-1.71 mmol/L)		3.38			1.16
HDL Cholesterol (>0.91 mmol/L)					0.78
LDL Cholesterol (<3.4 mmol/L)					2.87

Table 1: Serial laboratory investigations.

associated with acute pancreatitis. The reported incidence of hyperglycemia and DM with olanzapine is between 0.1-1% [8]. Occurrence of olanzapine-induced pancreatitis is further rare (<0.01%) [4]. In majority of reports new onset olanzapine-induced DM were reported to occur within days to months of starting treatment [2]. The mechanism of new onset diabetes with use of atypical antipsychotic drug like olanzapine is not clear [2,8-10]. Possible reported mechanisms are insulin resistance due to weight gain induced by blockade of H₁ and 5-HT_{2C} receptors [1,2,6,10], induction of insulin resistance by increasing hepatic glucose production and decreasing glucose uptake [1,6], insulin resistance due to direct effect on transcellular glucose transporter [2], central dysregulation of blood glucose by hypothalamus due to dopamine blockade [11], decrease in the pancreatic beta cell responsiveness to hyperglycemia induced by dopamine and serotonin antagonism (5-HT_{1A}), [2] direct toxic effect on pancreatic islet β cells [1,2,6,7,9], involvement of hepatocyte nuclear factor 1 α (HNF1 α), a transcription factor involved in glucose dysregulation [7], decrease in insulin secretion due to inhibition of M₃ and 5-HT_{2A} receptors [1,10], dysregulation of sympathetic nervous system [1,9], insulin resistance induced by increased serum prolactin level [12,13], leptin resistance [6] caused by olanzapine. Similarly mechanism of olanzapine-induced pancreatitis is still not clear [5,12]. Our patient did not have any history of diabetes and was never detected diabetic before this episode. But he had positive family history of diabetic with possible subclinical insulin resistance or prediabetic state which was unmasked by use of olanzapine [14,15]. Pancreatitis induced by olanzapine may be related to glucose dysregulation caused by the drug [4,5,7]. Metabolites of olanzapine as direct toxic effect on pancreas have been proposed as the cause of pancreatitis [4,7,9]. This hypothesis was proved in our case by resolution of DM and pancreatitis after withdrawal of olanzapine [5,9,11]. Hypertriglyceridemia has also been blamed to cause olanzapine induced pancreatitis [5,11]. Elevated triglyceride has been blamed to cause damage to pancreas by accumulation of noxious free fatty acids and lysolecithins in the pancreatic acinar cells [11,12]. Free fatty acids have been proved to be toxic to acinar cells as well as

capillary endothelium [11,12]. Our patient was detected to have high triglyceride level at the time of diagnosis. This proves that in our case both direct toxic effect and triglyceride induced damage were the reason for acute pancreatitis. Our patient was not a diagnosed case of DM, neither he was obese, though he had family history of DM. In our case olanzapine is the most probable precipitating cause (based on Naranjo probability scale score of 6 out of 10) [16] as it is already mentioned in literature to cause DM, DKA and acute pancreatitis [7,9,11,12]. This was proved by normalization of hyperglycemia after discontinuation of olanzapine and managed with insulin which has been reported in literature [3,11]. There are many case reports of normalization of DM after discontinuation of olanzapine [2,8,9,11], but our patient was requiring diet control and insulin for control of blood sugar even after discontinuation of olanzapine. The issue of normalization of DM after discontinuation of offending olanzapine still has been a matter of debate [2]. Our case report once again stresses that physician should remain vigilant about the occurrence of DKA and acute pancreatitis in patients taking olanzapine [7,9,11,12]. Weight, body mass index (BMI), plasma glucose and lipid level should be regularly monitored in patient receiving AAP, especially with risk factor for diabetes mellitus [2,3,6,11]. It is also advised that pancreatic enzymes should be monitored in presence hypertriglyceridemia and other risk factors for pancreatitis [5]. It is advised to monitor weight, BMI, and fasting blood sugar and lipid levels every monthly during first 3 months of starting or switching AAP, then every 3 monthly and afterwards every yearly till the patient is on treatment of AAP [2]. In case of elevated sugar level, patient should have an oral glucose tolerance test (OGTT), HbA1c estimation and patient should be referred to endocrinologist [2,3]. Also the offending AAP should be stopped and replaced with a safer alternative (aripiprazole or ziprasidone) with fewer propensities to cause hyperglycemia [2,3]. If the switching is not possible due to the primary psychiatric disorder, the DM should be aggressively treated with non-drug (diet restriction and lifestyle modification) and or drug treatment (OHA and or insulin) [3]. People taking AAP should be educated to lead a healthy life style with diet regulation and regular exercise [2,3].

They also should be taught to recognise the symptoms of hyperglycemia and report to doctor for urgent treatment [2]. Physicians should also consider risk factors of DM in psychiatric patients like obesity, race and positive family history before selecting AAP [2,3,8,10,11].

Olanzapine may have been responsible for DKA and acute pancreatitis in this patient with other contributing factors like sedentary life style, weight gain with elevated HbA1c on admission and family history of diabetes. Our case report once again confirmed that if not used in properly selected patient and not monitored carefully use of olanzapine can cause life threatening DKA complicated with acute pancreatitis and AKI in a nondiabetic and non schizophrenic patient. This combination occurrence is also very rarely reported [9,11].

Conclusion

Olanzapine has been known to be associated glucose dysregulation causing hyperglycemia. Sometimes their use may be complicated with life threatening diabetic ketoacidosis and acute pancreatitis.

References

1. Chiu CC, Chen KP, Liu HC, Lu ML (2006) The early effect of olanzapine and risperidone on insulin secretion in atypical-naïve schizophrenic patients. *J Clin Psychopharmacol* 26: 504-507.
2. Cohen D (2004) Atypical antipsychotics and new onset diabetes mellitus. An overview of the literature. *Pharmacopsychiatry* 37: 1-11.
3. De Hert M, van Eyck D, De Nayer A (2006) Metabolic abnormalities associated with second generation antipsychotics: fact or fiction? Development of guidelines for screening and monitoring. *Int Clin Psychopharmacol* 21(suppl 2):S11-15.
4. Doucette DE, Grenier JP, Robertson PS (2000) Olanzapine-induced acute pancreatitis. *Ann Pharmacother* 34: 1128-1131.
5. Kerr TA, Jonnalagadda S, Prakash C, Azar R (2007) Pancreatitis following Olanzapine Therapy: A Report of Three Cases. *Case Rep Gastroenterol* 1: 15-20.
6. Melkersson KI, Hulting AL, Brismar KE (2000) Elevated levels of insulin, leptin, and blood lipids in olanzapine-treated patients with schizophrenia or related psychoses. *J Clin Psychiatry* 61: 742-749.
7. Avella J, Wetli CV, Wilson JC, Katz M, Hahn T (2004) Fatal olanzapine-induced hyperglycemic ketoacidosis. *Am J Forensic Med Pathol* 25: 172-175.
8. Fertig MK, Brooks VG, Shelton PS, English CW (1998) Hyperglycemia associated with olanzapine. *J Clin Psychiatry* 59: 687-689.
9. Waage C, Carlsson H, Nielsen EW (2004) Olanzapine-induced pancreatitis: a case report. *JOP* 5: 388-391.
10. Lipscombe LL, Lévesque LE, Gruneir A, Fischer HD, Juurlink DN, et al. (2011) Antipsychotic drugs and the risk of hyperglycemia in older adults without diabetes: a population-based observational study. *Am J Geriatr Psychiatry* 19: 1026-1033.
11. Kahn D, Bourgeois JA (2007) Acute pancreatitis and diabetic ketoacidosis in a schizophrenic patient taking olanzapine. *J Clin Psychopharmacol* 27: 397-400.
12. Nair S, Yadav D, Pitchumoni CS (2000) Association of diabetic ketoacidosis and acute pancreatitis: observations in 100 consecutive episodes of DKA. *Am J Gastroenterol* 95: 2795-2800.
13. Foss MC, Paula FJ, Paccola GM, Piccinato CE (1995) Peripheral glucose metabolism in human hyperprolactinaemia. *Clin Endocrinol (Oxf)* 43: 721-726.
14. Ciccone MM, Scicchitano P, Cameli M, Cecere A, Cortese F, et al. (2014) Endothelial function in pre-diabetes, diabetes and diabetic cardiomyopathy: a review. *J Diabetes Metab* 5: 364.
15. Pannaciuoli N, De Pergola G, Ciccone M, Rizzon P, Giorgino F, et al. (2003) Effect of family history of type 2 diabetes on the intima-media thickness of the common carotid artery in normal-weight, overweight, and obese glucose-tolerant young adults. *Diabetes Care* 26:1230-1234.
16. Naranjo CA, Busto U, Sellers EM, Sandor P, Ruiz I, et al. (1981) A method for estimating the probability of adverse drug reactions. *Clin Pharmacol Ther* 30: 239-245.