

Severe Methanol Poisoning Survived with Locally made Oral Ethanol: A Case Report

Md Robed Amin*, Md Tofazzel Hossain, Md Dildar Hossain Badal, Shafikul Islam Khan, Khan Fariduddin Mohamad Ayaz and Md Billal Alam

Department of Medicine, Dhaka Medical College, Dhaka, Bangladesh

*Corresponding author: Dr. Md. Robed Amin, Associate Professor of Medicine, Department of Medicine, Dhaka Medical College, Dhaka, Bangladesh, House no-76, Road no-5, Block-F, Banani, Dhaka, Bangladesh, E-mail: robedamin@yahoo.com

Received date: January 17, 2016; Accepted date: March 2, 2016; Published date: March 9, 2016

Copyright: © 2016 Amin MR, et al. This is an open-access article distributed under the terms of the Creative Commons Attribution License, which permits unrestricted use, distribution, and reproduction in any medium, provided the original author and source are credited.

Introduction

Methanol is methyl alcohol commonly used in many home chemicals, duplicating fluids, varnishes, stains, paint thinners and dyes. Methylated spirit is very cheap and frequently available; hence it is easily adulterated and used as country liquor [1]. It becomes highly toxic when it is mixed with ethyl alcohol as it is adulterated. When taken with ethyl alcohol, it is metabolized only after complete metabolism of ethyl alcohol. In course of oxidation, formaldehyde and finally formic acid are formed which are highly toxic [1,2]; even as small amount as 10 ml can cause permanent blindness. Methanol poisoning typically induces nausea, vomiting, abdominal pain, and mild central nervous system depression. There is then a latent period lasting approximately 12-24 hours following which an uncompensated metabolic acidosis develops and visual function becomes impaired, ranging from blurred vision and altered visual fields to complete blindness [2]. Generation of toxic metabolite should be blocked by the administration of fomepizole or ethanol and formic acid metabolism should be enhanced by the administration of intravenous folic acid [3]. The metabolic acidosis should be managed by giving intravenous sodium bicarbonate. There are disadvantages associated with ethanol ingestions. These include complex dosing, difficulties with maintaining therapeutic concentrations, the need for clinical and laboratory monitoring, and adverse effects [2,3]. That's why fomepizole is chosen antidote although the superiority data is lacking [2,4]. Currently in Bangladesh fomepizole is not available and it is also expensive. The absolute ethanol is also out of reach and available only in chemical laboratory. The oral ethanol is available at regulated registered bar and big hotels. Although the oral ethyl alcohol of foreign country has proven percentage with appropriate volume, the Kerow Company of Bangladesh although produced ethyl alcohol and named premium whisky, it does not provide percentage of ethyl alcohol or constant volume in their bottles. In Bangladesh previously only few cases of methanol poisoning survived by using foreign ethyl alcohol and given in constant rate for 5 to 7 days [1]. The locally produce ethanol was never used as antidote for methanol before. Here is a case report of severe methanol poisoning who was rescued and recovered with locally available ethyl alcohol given as an antidote.

Case Report

Mr B, a 35 years old chronic alcoholic chef, with permanent residence at Geneva Camp, Mohammadpur, Dhaka, admitted in Dhaka Medical College Hospital (DMCH) on 10th April, 2015 presented with the complaints of vomiting with upper abdominal pain for 2 days, severe breathlessness for same duration, blurring of vision for same duration. His abdominal pain was sudden in onset, stabbing in nature, non-radiating, and no aggravating factor but relieves after vomiting.

There was no haematemesis or melaena. On query he addressed that he was alcoholic for 9 years and used to drink 1-2 bottles (one bottle consist about 500ml of alcohol) of locally made alcohol (Popularly known as Bangla Modh) per day. But for last 5 days he took 4-5 bottles daily with 8-9 bottles on the previous day of his illness and having mixed it with locally available spirit. His bowel and bladder habit was normal. There was no history of diabetes, asthma, hypertension. His blurring of vision was also associated with decreased visual acuity, photophobia, and "feeling of being in a snow field."

On general examination, we found his pulse was 74 beats/min, BP-110/60 mmHg, not anaemic, non-icteric and not cyanosed. On nervous system examination the patient was conscious, memory was intact, orientation in time, place and person was intact. His visual acuity was markedly diminished, field of vision intact but colour vision impaired. His light reflex was lost but accommodation reflex was intact, pupil was mid-dilated, fixed and non-reacting to light. His motor and sensory functions were intact. Indirect ophthalmoscopy revealed hyperemia of the optic disc and reduced pupillary responses to light. Peripapillary retinal edema and edema of the optic disc with loss of physiological cupping develop 6 hours after the hyperemia of the optic disc His respiratory rate was 10 breaths per min but it was deep and slow. Auscultation of lung was normal and there was acidotic breath mixed up with alcoholic breath. Examination of other systems revealed no significant abnormality. He was clinically suspected as a case of methanol poisoning and metabolic acidosis.

The patient's airway was secured with mouth gag and breathing was supported with high flow oxygen. Intravenous (IV) channel was ensued and IV normal saline was started immediately. Due to unavailability of bed in ICU, we started treatment the patient in general ward. Patient was treated with ethanol (whisky, made by kerow and Company, Bangladesh) 90 ml stat and then 10 ml every hourly from 10th to 12th April. Later 10 ml 2 hourly from 13th to 14th and 15th 10 ml 4 hourly. Total 800 ml locally available whisky was ingested by the patient (as absolute alcohol from laboratory was not available to the patient). He was also treated with inj ceftriaxone 2 gm iv daily for 5 days, Inj sodi bicarbonate (7.5%) 50 ml twice daily for 2 days and Omeprazole IV 4 days followed by oral. With suspected ocular toxicity patient was also immediately treated with inj Leukovurin (folic acid) 50 mg/5 ml⁻¹ vial iv 6 hourly for 7 days and Inj Methylprednisolone 1 gm iv daily 5 days and inj. Cynomim (Vit B12) 1000 microgram 1 amp intramuscular daily from 15th to 3 to 20th April. He was given IV fluids and nutritional support.

Blood analysis of complete blood count showed: HB-12.7 gm/dl, total count of WBC was 8.3 K/ μ L, differential count revealed - neutrophil 82.6% lymphocyte 10.4%. Arterial blood gas analysis showed pH-7.44, pO₂-107.6 mm Hg, pCO₂-30.1 mm Hg, HCO₃⁻-20.7 mmol/L, TCO₂-21.6 mmol/L, Base Excess-1.6 mmol/L, O₂

saturation-98.5%. Serum electrolytes revealed Na-143 mmol/L, K-3 mmol/L, Cl-108.0 mmol/L, serum creatinine 0.98 mg/dl, fasting blood sugar was 5.0 mmol/L, SGPT -36.0 U/L and SGOT -21.0 U/L Routine microscopic examination of urine was normal. Although patient was taking alcohol as binge drinking, immediate blood sample for alcohol (ethanol) was found- <10 mg/dl (Normal). A chest x-ray was done as his respiratory distress increases and found normal. MRI of brain showed subcortical increased density revealing features of toxic encephalopathy (Figures 1a and 1b). Fundal photography and indirect ophthalmoscopy revealed findings consists of initial hyperemia followed by toxic induced complete optic atrophy (Figures 2a and 2b).

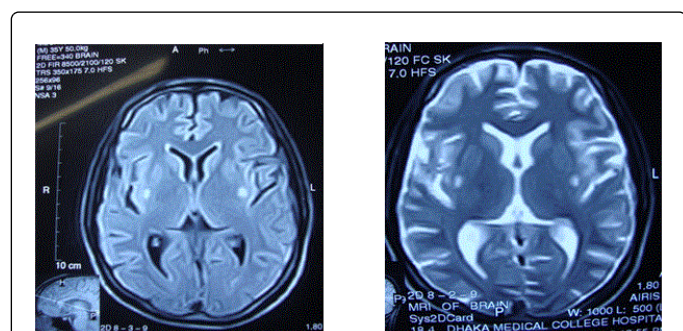


Figure 1a and 1b: MRI of brain showing features of toxic encephalopathy.

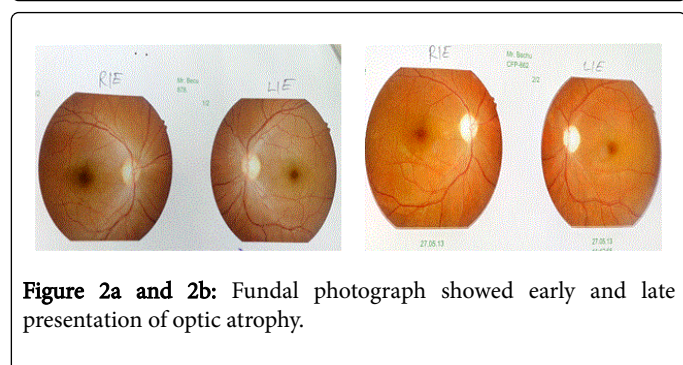


Figure 2a and 2b: Fundal photograph showed early and late presentation of optic atrophy.

After getting the locally available whisky (made by Kerow Company, Bangladesh) patient start feeling better and his respiratory distress subsided within 24 hours. Although he initially was able to see but as times goes, he become totally blind even to light perception. He recovered gradually within next week and all his drugs were stopped expect oral folic acid. Repeat serum alcohol concentration was above 100 mg/l up to the completion of locally made ethanol ingestion. The patient had complete recovery except his vision. Consultation with ophthalmologist was done and treatment was given with Inj erythropoietin (Epoitin) 5000 IU PFI injection IV bid-3 dose and Inj methyl cobalamin 500 µg 1 amp IM 2 times/week for 3 month, tab. vitamin B1, B6 and B12 1 tab Thrice daily for 3 month, Cap omeprazole and tab Folison-1 tab thrice daily for 3 months. On follow up after two weeks visual dimness improved but patient could see only the hand movement, sometimes the fingers can be counted but mistaken frequently. He was diagnosed as a case of Methanol Poisoning with Metabolic acidosis and Toxic Optic atrophy.

Discussion

Methanol itself is nontoxic but the intermediary metabolites are responsible for its toxicity. Methanol is metabolized to formaldehyde and then to formic acid. Formaldehyde is potentially a toxic molecule but due to its rapid metabolism to formic acid, it has not been detected in body fluids after toxic methanol ingestions [5]. Formic acid is metabolized slowly and, therefore, accumulates as the generation of formic acid exceeds the capacity to eliminate it. Thereby it has a direct relationship with its concentration and mortality and morbidity [4,6]. There is no facility in Bangladesh to measure methanol or formic acid and so the biochemical severity could not be measured in this case.

Methanol metabolic products are toxic and either managing these products or not permitting the formation of metabolic product is the strategy for treatment of humans with methanol ingestion. Production of methanol metabolic product is possible by blocking/inhibiting the cytosolic alcohol dehydrogenase enzyme by fomepizol or by providing ethanol which is preferentially metabolized by alcohol dehydrogenase thus sparing methanol from metabolism [1,2,5].

The magnitude of the acidosis correlates well with formic acid accumulation [7] and the accumulation has inverse relation with decrease in plasma bicarbonate, [8-10] suggesting that the acidosis seen early in the clinical course is caused directly by formic acid production. In this case patient the anion gap was 18 mmol/l and was having acidotic breathing and his lungs was clear clinically and radio logically to justify the statement. Unfortunately the blood sample was taken after the management and so the arterial blood gas analysis was not seems to be severe. After getting the antidote and bicarbonate, his metabolic acidosis was corrected. The early acidosis observed in methanol poisoning may be due to the accumulation of formate, with lactate accumulation occurring in the later stages of poisoning from tissue hypoxia and inhibition of cellular respiration by formic acid [8].

The characteristics feature of the index case was his ocular toxicity. Undissociated formic acid specifically targets the optic disc and retrolaminar section of the optic nerve, causing optic disc edema, breakdown of the myelin sheaths and optic nerve lesions [11,12]. The presence of blurred vision with a relatively clear sensorium strongly suggests the diagnosis of methanol poisoning [7]. The co-ingestion of ethanol typically delays the onset of symptoms beyond 24 hours. In a series of 323 patients ingesting methanol-420 AACT contaminated bootleg whiskey, the latent period averaged about 24 hours with a range of 40 minutes to 72 hours [7]. This is consistent with the index case as he was chronic alcoholic and during the previous week he took binge drinking with local alcohol in large amount and adulteration occurs about 24 hours back of his presentation. The presence of an unresponsive, dilated pupil was observed in our patient which actually indicates either major brain injury or dysfunction of the major visual pathways with a high risk of permanent loss of vision [11] and it was observed that there was gradual complete loss of vision. It is described in many papers that permanent visual sequelae occur in up to 25-33% of patients in epidemics of methanol intoxication [13] Permanent ocular sequelae of methanol intoxication include diminished pupillary reactions to light, optic atrophy, optic cupping, peripheral constriction of the visual fields, central scotoma, reduced visual acuity, loss of color vision, and blindness [7,11]. In our patient we started methyl-prednisolone and folic acid to combat the eye changes and as per advice from the ophthalmologist Inj Erythropoietin and inj Vit B12 was also given. But unfortunately there was incomplete response and during second week follow up only hand movement was perceived by

the patient. But there is report of delayed recovery and we are following the patient regularly to see the affect.

The use of ethanol as antidote is life saving for methanol poisoning and it should be started as soon as possible. Although the best antidote would be fomepizole which is specific alcohol dehydrogenase (ADH) having 20 times affinity for ethanol than methanol [1]. But unfortunately fomepizole is not available in the local market. Although the delivery of oral ethanol is cumbersome and need intense monitoring and it is not having regulatory authority registration to be used for antidote, the clinical experience by physicians still make it a logical choice where the fomepizole is not available. The loading dose of ethanol is 600-800 mg/kg (0.6-0.8 g/kg). Initially the serum ethanol concentration should be monitored every 1-2 hours in order to ensure that the serum concentration remains in the recommended therapeutic range of approximately 100-150 mg/dL [1]. The loading dose is 1.8 ml/kg body weight and followed by 0.2 ml/kg body wt every hour until the patient settles clinically and maintaining serum ethyl alcohol level above 100 mg/dl [1]. These are for 80 proofs solution of ethanol having 40% alcohol. The whisky, dry gean or vodka of quality products maintains the composition with standard. The Keru company of Bangladesh although produces different liquors for consumers, the label is missing and the amount of 80 proofs solution with 40% alcohol and 0.79 g/ml specific gravity is hardly maintained. But there is belief in consumer that the local product is heavy to drink and possibly the content is having more than 45% alcohol. That's why we choose to give the maintenance as 0.2 ml/kg/hr and as he was having constant ethyl alcohol for last 7 days. Ideal maintenance of ethanol for drinker is 0.46 m/kg/hr [1]. There are also options for haemodialysis for the removal of toxic formate from the body. The haemodialysis is to be carried out in patient who is nonresponding to antidote and persistence of refractory metabolic acidosis [2]. In our case, the appropriate timely provision of ethanol leads to improvement and dialysis was not dimmed necessary. The patient recovers well with complete correction of acidosis and respiratory distress but he developed permanent visual complication like optic atrophy. The patient used to be regular drinker for 9 years and it has effect on his intellectual ability. The involvement of liver was searched and it was normal in biochemical and radiological investigations. The chronic effect of central nervous system including irritability, restlessness, occasional drowsiness and talkativeness was stated by his wife is consistent with literatures [1,4,5]. The local ethyl alcohol is perhaps effective with percent and specific gravity ingredients, it need to be label appropriately for easy understanding.

Conclusion

Methanol poisoning is one of the severe form of poisoning with high mortality if not properly diagnosed and treated immediately. There is lack of diagnostic tool like serum methanol label, formic acid label, dynamic folate value etc for monitoring in treatment process. We strongly recommend to make available fomepizole to manage the severe cases as it has long lasting actions and delivery is simple. The absolute IV ethanol should also be available for immediate antidote effect. Every physician should follow the national guideline on poisoning for active management of methanol poisoning which is happened to be occasional cluster of outbreaks in Bangladesh due to adulteration. A quick uniform response with active management tool can save valuable life of methanol poisoning.

Consent

Written informed consent was obtained from the patient for publication of this case report.

Competing interests

The authors declare that they have no competing interests.

Authors' contributions

MRA, KFMA, MBA have participated in designing, article search, information coding and writing of the manuscript. They were also responsible for the clinical care of the patients. DHB, SIK and MTH were responsible for the clinical care of the patient. All authors have read and approved the final manuscript.

Authors' information

MBA is Medical officer in Internal Medicine of Dhaka Medical College Hospital of Bangladesh. SIK is assistant Registrar and DHB is the registrar of same working unit. MRA (MBBS, FCPS) is Associate Professor of Ward 112, Dhaka Medical College Hospital Bangladesh. MBA is the professor and KFMA is the Assistant Professor of same ward.

References

1. Md. Abul Faiz, Md. Mizanul Hoque, Shakil Ahmed, Md. Robed Amin, Aniruddha Ghose (2008) Training manual of Poisoning (National Guideline of poisoning). World Health Organization (WHO).
2. Barceloux DG, Bond GR, Krenzelok EP, Cooper H, Vale JA; American Academy of Clinical Toxicology Ad Hoc Committee on the Treatment Guidelines for Methanol Poisoning (2002) American Academy of Clinical Toxicology practice guidelines on the treatment of methanol poisoning. *J Toxicol Clin Toxicol* 40: 415-446.
3. Anon, Calcium L (2001) AHFS Drug Information 2001; American Society of Health-System Pharmacists: Bethesda, 3615-3618.
4. Brent J, McMartin K, Phillips S, Aaron C, Kulig K; Methylpyrazole for Toxic Alcohols Study Group (2001) Fomepizole for the treatment of methanol poisoning. *N Engl J Med* 344: 424-429.
5. McMartin KE, Martin-Amat G, Noker PE, Tephly TR (1979) Lack of a role for formaldehyde in methanol poisoning in the monkey. *Biochem Pharmacol* 28: 645-649.
6. Tephly TR (1991) The toxicity of methanol. *Life Sci* 48: 1031-1041.
7. Hantson P, Haufroid V, Mahieu P (2000) Determination of formic acid tissue and fluid concentrations in three fatalities due to methanol poisoning. *Am J Forensic Med Pathol* 21: 335-338.
8. Bennett JL, Cary FH, Mitchell GL, Cooper MN (1953) Acute methyl alcohol poisoning: a review based on experiences in an outbreak of 323 cases. *Medicine (Baltimore)* 32: 431-463.
9. Sejersted OM, Jacobsen D, Ovrebø S, Jansen H (1983) Formate concentrations in plasma from patients poisoned with methanol. *Acta Med Scand* 213: 105-110.
10. Clay KL, Murphy RC, Watkins WD (1975) Experimental methanol toxicity in the primate: analysis of metabolic acidosis. *Toxicol Appl Pharmacol* 34: 49-61.
11. Benton CD, Calhoun FP (1952) The Ocular Effects of Methyl Alcohol Poisoning. Report of a Catastrophe Involving 320 Persons. *Am J Ophthalmol* 36: 1677-1685.
12. Hayreh MS, Hayreh SS, Baumbach GL, Cancilla P, Martin-Amat G, et al. (1977) Methyl alcohol poisoning III. Ocular toxicity. *Arch Ophthalmol* 95: 1851-1858.

13. Naraqi S, Dethlefs RF, Slobodniuk RA, Sairere JS (1979) An outbreak of acute methyl alcohol intoxication. Aust N Z J Med 9: 65-68.