

Spectrum of Abnormal Movement in a Cohort of Neuro-Wilson Patients with Radiological Associations

Moumita Bagchi¹, Neelanjana Paul², Soumitra Ghosh³, Suchitra Majumdar⁴, Santa Saha⁵, Arijit Roy⁶ and Shyamal K Das^{7*}

¹Department of Neurology, Columbia Asia Hospital, Kolkata, India

²Department of Psychiatry, I Care Medical College, Haldia, WB, India

³Department of Radiology Presently, Malda Medical College, Malda, WB, India

⁴Department of Ophthalmology, Institute of Post Graduate Medical Education and Research, Kolkata, India

⁵Department of Biochemistry, Bankura Medical College, Bankura, WB, India

⁶Department of Neurology, Bangur Institute of Neuroscience, and IPGMER, Kolkata, India

⁷Department of Neurology and Neurogenetics, Bangur Institute of Neuroscience and Institute of Post Graduate Medical Education and Research, Kolkata, India

*Corresponding author: Das SK, Professor and Head, Department of Neurology and Neurogenetics, Bangur Institute of Neuroscience and Institute of Post Graduate Medical Education and Research, Kolkata, WB, India, Tel: 913322230003; E-mail: das_sk70@hotmail.com

Rec date: Dec 07, 2015; Acc date: Feb 05, 2016; Pub date: Feb 08, 2016

Copyright: © 2016 Bagchi M, et al. This is an open-access article distributed under the terms of the Creative Commons Attribution License, which permits unrestricted use, distribution, and reproduction in any medium, provided the original author and source are credited.

Abstract

Background: Disorders of movement are important features of Neuro-Wilson's disease (NWD) and their recognition helps in early diagnosis. We studied the various types of movement disorders including any novel phenomenology found in our cohort of NWD, along with radiological correlations.

Method: A total of 129 consecutive patients of WD (M:F) were examined in Movement Disorders clinic of a tertiary care neurological institute at Kolkata, India. A semi-structured interview and examination determined the various types of movement disorders detected, after proper informed consent. Neuro-imaging (MRI of 1.5 Tesla system) was carried out whenever possible.

Results: The common movement disorders were dystonia (91.8%), Parkinsonism (83.72%), and tremor (53.49%). Others were movement induced focal myoclonus (12.4%), ataxia (11.63%), choreo-athetosis (15.5%). The less frequent movement disorders were akathisia (5.2%) and tics disorder (5.42%) and oromandibular dyskinesias (2.33%). MRI lesions were found to be associated with jaw opening dystonia (caudate), neck dystonia (putamen and pons), truncal dystonia (caudate, globus pallidus and cortical atrophy), appendicular dystonia (caudate and putamen), Parkinsonism (mid-brain), postural tremor (caudate and putamen), tics and akathisia (mid-brain and pons in both).

Conclusion: WD is associated with a variety of common movement disorders such as dystonia, Parkinsonism and tremor. The less frequent movement disorders were focal myoclonus, stereotypes, tics disorders and orofacial dyskinesia. Radiological lesions can be found in association with majority of the movement disorders except in few cases where functional imaging studies may help.

Keywords: Neuro-wilson's disease; Movement disorders; Neuroimaging

Abbreviation

CPM: Central pontine Myelinolysis

Introduction

Wilson's disease (WD) is a hereditary disorder of copper metabolism, characterized by reduced biliary excretion of copper [1], leading to copper deposition in liver, brain, kidney and Descemet's membrane of the cornea. The majority of patients of WD present with either hepatic involvement (Hepatic Wilson) or neuropsychiatric manifestations known as Neuro-Wilson Disease (NWD). In NWD symptoms onset is most commonly in the second to third decade and majority becoming symptomatic before the age of fifty years [2], but

has been reported as late as 72 years [3]. NWD can mimic other neurological disorders and is frequently subjected to diagnostic errors [4]. Thus, a high index of suspicion is needed to achieve a diagnosis.

Movement disorders have been recognized to be important clinical features of WD since the original description given by Wilson [5]. Comprehensive studies on the full spectrum of movement disorders in NWD are few in literature. Although diagnosis of NWD is based on clinical and biochemical criteria, imaging of brain is helpful in corroboration of diagnosis.

Genetic testing is useful in confirming the diagnosis. However, the large number of mutations (near about 400) occurring in WD makes it cumbersome and expensive, as sequencing of the whole gene is frequently required and may not be available at all centers [6]. It is commonly carried out from DNA extracted from patient and parent's blood followed by sequencing of all the twenty exons of WD gene.

In this context, we planned to study the types of movement disorders as observed in our cohort of NWD patients and compared with similar studies globally. We also made an attempt to correlate movement disorder's phenomenology and radiological findings in relation to probable localization as observed in our patients as well as explain pathophysiology based on available literatures.

Methods

Consecutive patients diagnosed as NWD in the Movement Disorders Clinic of Bangur Institute of Neuroscience, Kolkata from June, 1996 to March, 2010 were included in this study. This included 129 cases. This is both a retrospective (28 cases) and a prospective study (101 cases). Cases were examined by two neurologists and diagnosis was reached by consensus opinion. One of them was a movement disorder specialist (SKD).

Inclusion criteria were all patients who were attending the Movement Disorders Clinic under 50 years of age irrespective of past or family history of jaundice. They were investigated based on Sternlieb's criteria [7]. Those who had the presence of Kayser Fleischer (KF) ring; low serum ceruloplasmin and high base-line urinary copper excretion levels were included in the study. Neuroimaging studies, preferably MRI of brain (1.5 Tesla system), were performed whenever possible. The reporting radiologist was blind to the diagnosis. Exclusion criteria for considering NWD was those subjects who had negative KF ring but serum ceruloplasmin level was lower or urinary 24 hour copper excretion level higher than normal.

Patients underwent detail clinical history and examination and necessary investigations. These were recorded in a semistructured proforma. Relevant information was also collected from patients and guardians, if patients were unable to provide history. Information was obtained on i) Parkinsonism characterized by bradykinesia, rigidity, rest tremor with or without postural abnormality; ii) dystonia, including various axial and appendicular dystonias such as jaw opening dystonia, oromandibular dyskinesias, cervical dystonias, truncal dystonia and limb dystonia ; iii) tremors such as rest, postural, intention, wing beating type; iv) chorea, v) athetosis, vi) ataxia, vii) myoclonus, viii) tics, ix) stereotypies, x) akathisia and any other novel phenomenology. Standard criteria for each were followed [8]. Most of the abnormal movements were video recorded after written permission was obtained. All patients underwent blood testing such as haemogram, liver function test, renal function test, serum ceruloplasmin, routine urine examination, 24 hr. urinary copper excretion and slit lamp examination by an experienced ophthalmologist. Genetic testing was not performed in our patients as it was not routinely available in our institute and also because of prohibitive cost and lack of health insurance among our patients. The study was approved by the ethical committee of the institute and written informed consent was obtained from the patients or their guardians.

Statistical Analysis

Data was analyzed utilizing appropriate statistical tools. Chi square and Fisher's exact test were applied to compare between categorical variables, using statistical software SPSS Version 10.1. P value of < 0.05 was considered to be significant.

Results

This study evaluated a total of 129 WD (males- 83: females- 46; Hindus 96: Muslims 33) patients from 123 unrelated families. The mean age of onset of the disease was 14.52 years (range 7-50 years). The mean time till diagnosis was 18.09 months (range 0 to 120 months). A total of 80 (62.01%) patients were from rural background, 30 (23.26%) from urban and 19 (14.73%) from semi-urban background.

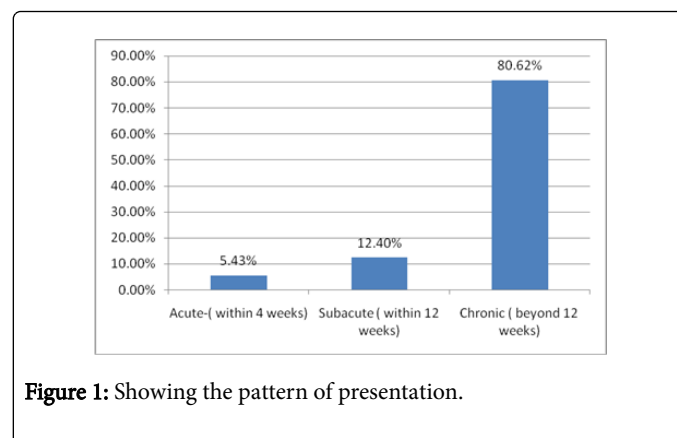


Figure 1: Showing the pattern of presentation.

The presentation of WD was acute (within 4 weeks) in 7(5.43%), sub-acute (within 3 months) in 16 (12.40%) and chronic (beyond three months) in 104 (80.62%) and in 2 cases the onset was not clear (Figure 1). Family history of WD was present in 30 patients (23.26%). History of consanguinity was present in 12 (9.30%), all of them being Muslims. History of jaundice was present in 63 (48.84%). A total of 59 (45.74%) patients had evidence of associated hepatic disease.

The age of onset of the disease was as follows: 43 (33.33%) in the first decade; 63 (48.84%) in second decade, 16 (12.40%) in third decade, 5 (3.88%) in fourth decade and 2 (1.55%) in fifth decade (Figure 2).

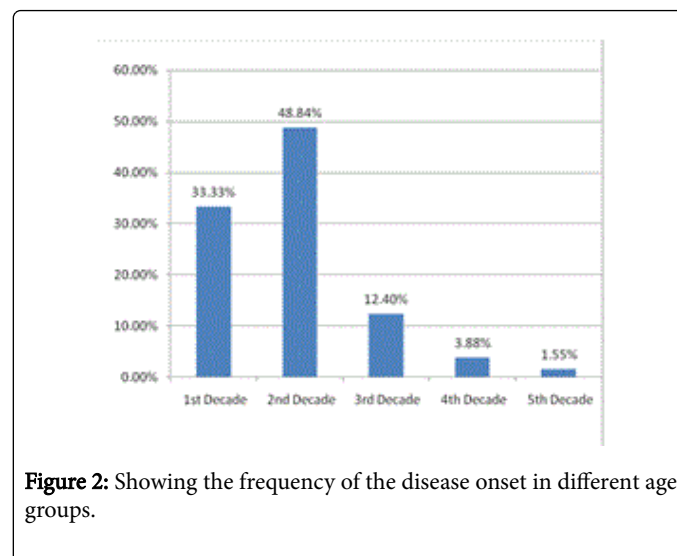
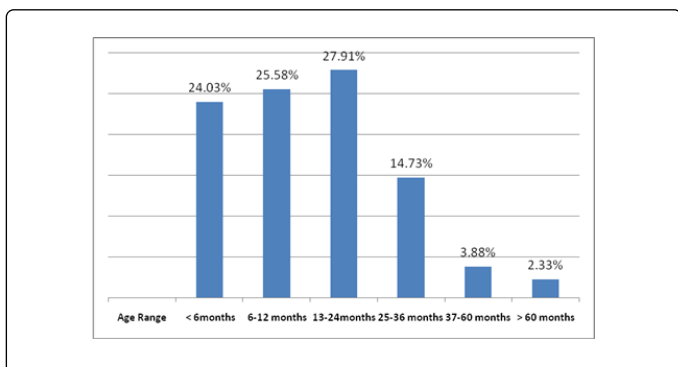


Figure 2: Showing the frequency of the disease onset in different age groups.

The time interval between onset of symptoms and presentation to the doctors were 31 (24.03%) patients within six months of onset, 33 subjects (25.58%) within seven to twelve months, 36 subjects (27.91%) within one to two years, 19 subjects (14.73%) within two to three years,

5 subjects (3.88%) within three to five years and 3 subjects (2.33%) beyond five years of onset (Figure 3).



We have excluded KF ring negative cases to maintain the homogeneity of cases. The mean values of serum ceruloplasmin were 12.61mg% (range 0.08-69 mg%) and twenty-four hour urinary copper levels was 287.77µg/dl (range 18.9-1408 µg/dl). The serum ceruloplasmin was normal in 11 patients, but their excretion of increased twenty-four hour urinary copper level was high. Similarly the twenty four hour urinary copper levels were normal in 6 patients, though they had low serum ceruloplasmin levels.

Types of movement disorders (N=129)	Frequency (IN %)
A) Parkinsonism	108 (83.72)
i) Rigidity	108 (83.72)
ii) Bradykinesia	98 (75.97)
iii) Rest tremors with Parkinsonism	30 (23.26%)
iv) Camptocormia	11 (8.53)
B) Dystonia	91.8%
i) Frontalis	12 (9.30)
ii) Lingual	48 (37.20)
iii) Jaw opening	93 (72.09)
iv) Jaw closing	3 (2.33)
v) Oro-mandibular	3 (2.33)
vi) Neck	65 (50.39)
a) torticollis	56 (43.41)
b) antecollis	25 (19.38)
c) retrocollis	13 (10.08)
vii) Truncal	41 (31.78)

a) laterocorpus	39 (30.23)
b) antecorpus	11 (8.53)
c) retrocorpus	5 (3.88)
viii) Appendicular	118 (91.47)
C) Tremors	69 (53.49)
i) Postural tremor	65 (50.39)
ii) Resting tremor	35 (27.13)
iii) Intention tremor	33 (25.58)
iv) Wing-beating tremor	12 (9.30)
D) Chorea (all generalized)	18 (13.95)
E) Athetosis	2 (1.55)
F) Ataxia	15 (11.63)
G) Tics	7 (5.42)
H) Stereotypies	11 (8.52)
I) Akathisia	7 (5.42)
J) Focal Myoclonus	16 (12.40)
L) Bruxism	1 (0.78)

Table 1: Frequencies of various movement disorders observed in NWD* in the patients cohort. *Some patients have more than one movement disorders.

Predominant initial presentations were dystonia in 20.1%, Parkinsonian features in 17.9%, tremor in 9%, ataxia in 3%, chorea in 9.7%, pure psychiatric in 2.2%, osseo-muscular in 2.2 % and mixed type of presentation in 35.9%.

The frequencies of the various types of movement disorders observed in our cohort of patients are summarized in Table 1.

Parkinsonian features including cogwheel rigidity and bradykinesia were present in about 83.72% of patients. The manifestations were commonly bilaterally symmetrical and associated with resting tremor in 27.13% of patients. Most patients also had gait disturbances and postural instability. Among dystonias, commonest pattern was appendicular (91.47%) followed by jaw opening (72.09%) and cervical regions (50.39%).

Among tremors, commonest type was postural (50.39%) followed by rest (27.13%) and intention variety (25.58%). Other movement disorders were provided in Table 1.

In Table 2, a comparison of different movement disorders from three large studies has been provided.

Clinical feature	Taly et al. (n=282)	Walshe, et al (n=136)	Machado, et al. (n=119)
Country	India	UK	Brazil
M:F	2.3:1	0.94: 1	1.5:1
Mean age of onset	15.93 years	16.2 years	19.6 years

Mean duration before diagnosis	28 months	13 months	1.1 years
Dystonia	35.4%	41.17%	69%
Dystonic smile		15%	72%
Dysarthria		58.1%	91%
Tremors		51.4%	resting-5%, postural 60%
Bradykinesia / parkinsonism	62.3%	33.1%	58%
Ataxia	27.9%		28%
Seizures	7.7%		4.20%
Myoclonus	3.4%		0.84%
Chorea	8.9%	11%	16%
Athetoid movements	2.2%		14%
Gait abnormalities		13.9%	75%

Table 2: Comparisons of clinical features of previous studies with Wilson disease.

Neuroimaging Studies

Neuroimaging studies were available in a total of 93 patients (72.1%). The MRI plates were examined by the radiologist and their results were discussed with the study neurologist to arrive at a consensus opinion. The results of MRI were provided in Table 3. Result of analysis with different MRI findings and diverse movement disorders was presented in Table 4.

MRI (n=93)	Frequency (in %)
A) Normal	7 (7.5)
B) Basal ganglia T2 hyperintensities	
i) Caudate	66 (71.0)
ii) Putamen	73 (78.5)
iii) Globus Pallidus	44 (47.3)
iv) Bright claustrum sign	2 (2.2)
C) Brainstem T2 hyperintensities	
i) Midbrain	41 (44.1)
ii) Giant Panda Sign	19 (20.4)
iii) Pons	24 (25.8)
iv) CPM* like lesions	3 (3.2)
v) Medulla	4 (4.26)
D) Thalamus T2 hyperintensities	41 (44.1)

E) Cerebellar T2 hyperintensities	3 (3.2)
F) Lobar T2 hyperintensities	
i) Temporal lobe	2 (2.2)
ii) Frontoparietal lobe	9 (9.7)
iii) Occipital lobe	1 (1.1)
G) Periventricular white matter T2 hyperintensities	9 (9.7)
H) T1 hyperintensities in basal ganglia	7 (7.5)
I) Atrophy	
i) Cortical atrophy	45 (48.4)
ii) Caudate head atrophy	5 (5.4)
iii) Cerebellar atrophy	8 (8.6)
J) Ventricular dilatation	
i) Supratentorial ventricles dilated	34 (36.6)
ii) All ventricles dilated	1 (1.1)
I) Others	3 (3.23)

Table 3: Imaging studies: MRI findings in NWD in the present study. (*CPM: Central Pontine Myelinolysis).

Types of movement disorders (n=129)	Radiological association (p value)
A) Parkinsonism	Giant Panda Sign (p = 0.035)
B) Dystonia	

Frontalis	none
2) Lingual	none
3) Jaw Opening	caudate (p = 0.004)
4) Jaw Closing	none
5) Neck	putamen (p = 0.023), CPM like (p = 0.053)
6) Truncal	caudate (p = 0.054), globus pallidus (p = 0.049), cortical atrophy (p = 0.054)
7) Appendicular	caudate (p = 0.043), putamen (p = 0.011)
8) Oro-mandibular Dyskinesias	none
C) Tremors	caudate (p = 0.022), putamen (p = 0.046)
Resting	putamen (p = 0.001)
Postural	none
3) Intention	none
4) Wing-beating	Midbrain (p = 0.020), pons (p = 0.003), brainstem (p = 0.019), thalamus (p = 0.020), cerebellum (p = 0.019)
D) Chorea	none
E) Athetosis	none
F) Ataxia	none
G) Tics	Midbrain (p = 0.006), pons (p = 0.037)
H) Stereotypies	none
I) Akathisia	Giant Panda Sign (p = 0.029), pons (p = 0.047)
J) Myoclonus	none

Table 4: Correlation of clinico-imaging (MRI) association.

Discussion

This study has shown the clinical features of 129 NWD subjects and its neuroimaging correlation. All the cases have been evaluated in Movement Disorder Clinic under the expertise of movement disorder specialist. Thus it has been possible to pick up less frequent movement disorders. In developing countries, genetic study is not commonly available except in research setting and costly too. Thus NWD diagnosis is based on various neurological features, the commonest being movement disorders, including Parkinsonism, dystonia, tremors and ataxia (Table 1) associated with biochemical and imaging abnormalities.

Interestingly 62% of our NWD patients were from rural areas and it follows the pattern of rural and urban population distribution in the ratio of 2:1 throughout the nation and also in our state. In our case series, all the patients with consanguinity were from Muslim community since consanguineous marriage is common in this faith.

In the past WD was sub classified in various ways. Denny Brown [9] first classified neurological WD patients into two groups- a) "pseudosclerotic" characterized by dysarthria and flapping "wing-beating" tremors where the patients were over 19 years of age and b) progressive lenticular degeneration with predominant dystonia seen between 7 and 15 years of age. Walshe et al., [10] further classified WD

patients into four main clinical subtypes- i) Parkinsonian showing a paucity of movements; ii) "pseudosclerotic" with predominant tremor; iii) dystonia and iv) chorea. The Parkinsonian presentation was found to be the commonest in both adults and children, pseudosclerotic was more common in adults and dystonic type was most commonly in juveniles. Oder et al., [11] identified three sub-groups on the basis of clinical findings and MRI changes- i) patients with bradykinesia, rigidity, cognitive impairment and depressed mood with MRI showing dilatation of the third ventricle; ii) patients with ataxia, tremor, reduced functional capacity and focal thalamic lesions; iii) patients with dyskinesia, dysarthria, personality disturbances and focal lesions in the putamen and pallidum. In our study, we found that it was often very difficult to subclassify NWD patients according to recognized sub-groups as they frequently presented with overlapping clinical picture.

Dystonias

In our series, dystonia was present in about 91.8% of patients, making it the commonest manifestation. One of the reasons for the high frequency in our series may be related to predominant juvenile patients. Underlying explanation may be due to higher copper content in the Indian diet [12]. It is postulated that the basal ganglia in younger patients may be more vulnerable to insults due to copper deposition.

The other reason could be ethnically related since patients with homozygous for 3402Cdel had an earlier onset of neurological disease with increased dystonia, Parkinsonism and unusual neurological manifestations [13]. Modifier genes also have a function in delaying or hastening the onset and may have a role in phenotypic presentation [2]. Whether such modifier genes are responsible for the higher frequency of dystonia needs to be further studied.

In this series, radiological lesions have been observed in overlapping manner. The commonest form of dystonia was appendicular dystonia, which was associated with lesions in caudate and putamen. Neck dystonia was associated with putaminal and central pontine lesions. Truncal dystonia was associated with caudate and globus pallidus lesions and cortical atrophy. Interstitial nucleus of Cajal in the midbrain has been reported to function as a neural integrator for head posture [14] and bilateral imbalance has been reported to result in torticollis. Recent studies based on functional and metabolic imaging have shown that dystonia is a circuit disorder involving basal ganglia-thalamo-cortical and cerebellothalamic-cortical pathways and in NWD underlying basis may be related to wide spread involvement of basal ganglia and brainstem [15].

The characteristic vacuous smile seen in WD, also called jaw opening dystonia was found to be associated with caudate lesions. In previous studies, Oder et al., [11] found putamen and pallidal lesions to correlate with dystonia and Barbosa et al., [16] found only putaminal lesions to correlate with dystonia. Sinha et al., [17] found focal pallidal lesions in dystonia. Thus the previous and the present studies emphasized the role of neural network in basal ganglia for anatomical localization of dystonia rather than single lesion as has been recently emphasized based on circuit disorder hypothesis [15].

Parkinsonism

Previous studies have documented Parkinsonian features in the range between 45% and 81.8% [10,18-21] as compared to about 83% in this study. In some series Parkinsonian features were the commonest presentation in NWD [10,21]. Previously Oder et al., [11] found that the sub-group of patients with Parkinsonism had more dilatation of the third ventricle on MRI. In our series, there was an association between clinical symptoms of Parkinsonism and MRI changes in the mid-brain, more specifically the Giant Panda Sign (GPS). This GPS was present in 20.4% of patients and all of them had features of Parkinsonism. However NWD patients with tremor and dystonia have also shown this characteristic imaging finding [22]. Barbosa et al., [16] in a previous study had reported Parkinsonism with involvement of the striatum and/ or substantia nigra. This probably reflects the implication of substantia nigra and the nigro-striatal pathway in generating features of Parkinsonism. In local homozygous patients with Cys271stop mutation, neurological features characterized by Parkinsonism at 2nd decade (17-19 years) have been observed [6].

Tremor

Tremor is considered as a commonest movement disorder in some series [23] and postural tremor was the commonest subtype reported in other series [20]. In our series, tremor was present in about 53.49% of which the commonest was postural tremor (50.39%) and third commonest abnormal movement. In previous literature, Oder et al., [11] had reported ataxia and tremor with thalamic lesions and in another study, action tremor was found to correlate with lesions in globus pallidus, substantia nigra and head of the caudate nucleus [23].

Postural and action tremor arise from spontaneous firing of the inferior olivary nucleus which drives the cerebellum and its outflow pathways via the thalamus to the cerebral cortex and then to spinal cord [24-26]. Additionally subthalamic nuclei, globus pallidus externa are also capable of inducing tremor [27]. However recent report based on MRI has also confirmed implication of basal ganglia in inducing tremor [28]. In our series, the characteristic "wing beating" tremor of WD was present in only about 9.0% of patients as compared to 33% in other study [10]). This type of tremor was associated with lesions of thalamus and brainstem such as mid-brain, pons, medulla, and cerebellum, possibly reflecting the anatomical sites of origin of this type of tremor. Tremor, as a whole, in our series was correlated with caudate, putaminal lesions and brain stem, while resting tremors were associated with putaminal lesions. Thus tremor in NWD had many sites of lesion predominantly involving basal ganglia nuclei and brainstem.

Ataxia

Ataxia and other cerebellar symptoms were seen in only 11.63% of patients. In the other series from India [16], the frequency of ataxia was found to be similarly low. Few series have noted ataxia to be in the range of 28-58% [19,23,28,29]. One of the causes of the smaller number of patients with ataxia may be the large number of juvenile patients in our series as ataxia is usually found in older patients. In younger patients, possibly, significant dystonia often prevents ataxia from being manifested.

Choreoathetosis

The number of patients with choreo-athetosis was seen in 15.5%, which is comparable to other series [20] (Table 3). No particular type of lesion on imaging was correlated. To the best of our knowledge, no radiological correlation was found in the published literature.

Other less frequent movement disorders

Interestingly, we have found stereotyped movement amongst 8.52% and akathisia in 5.2% of patients, unrelated to any psychiatric medications. These two movement disorders have been reported rarely. They were reported as unusual features in the other major series [20] reporting stereotypies. Stereotypic behaviors are thought to reflect basal ganglia disorders, although which circuits are involved is not known [30]. No radiological correlation was however found in our subjects. Akathisia, is thought to result from inhibition of ventral tegmental dopaminergic projections to the mesolimbic or mesocortical areas, and showed an association with pontine and mid-brain lesions in our patients [31]. In three of our patients, akathisia started after starting d-penicillamine, probably due to excess mobilization of copper from stores leading to inhibition of above mentioned pathways.

Tics in NWD occurred in 5.42% of our patients and have not been previously reported in other series. In our study, they were found to correlate with pontine and mid-brain lesions. In previous PET studies tics were associated with increased metabolic activity in the lateral premotor, supplementary motor association areas and mid-brain corresponding to a reduction of activity in the indirect pathway [32]. No association with pons was reported in previous studies. Functional studies need to be done to determine the underlying metabolic activity in basal ganglia.

Orobuccolingual dyskinesias, separate from the common oromandibular or jaw opening dystonia, in the absence of any anti-

psychotics or levodopa were seen in 2.33% of patients. Only isolated tongue dystonia has been reported in NWD earlier [33], though tongue abnormality had been observed in 22.05% of cases in the series by Walshe et al., [10]. The resulting dyskinesia may be consequence of basal ganglia disinhibition.

We also noticed focal myoclonus (12.4%) induced by movements or at the start of movements at a higher frequency as compared to previous studies. Most myoclonus reported in WD is focal, except for anecdotal reports of generalized myoclonus [13]. Myoclonus, usually reported to be extremely rare in other studies [18] was noted to be 3.4% in a study from India [17]. The exact cause for myoclonus is not known, but may be genetically related since one study from Brazil has recorded the homozygous genotype 3402delC/3402delC associated with myoclonus [13]. This mutation has not been identified among Indians [34], and needs to be studied further.

There were a few unusual manifestations in some of the patients such as bruxism seen in one patient and eyelid apraxia noticed in two patients. We did not encounter any paroxysmal disorders such as kinesogenic or non-kinesogenic dyskinesias.

Over the years since WD was described, the different movement disorders in WD are being documented and clarified. The previous studies have shown the frequency of major movement disorders, but less common disorders have been infrequently described. The exact pathophysiology of these movement disorders is not clear yet, though copper has been documented to be deposited all over the brain in the cortex and basal ganglia of brain [7]. Efforts have been made to localize the anatomical sites of the lesions based on MRI and recently on functional imaging which has documented the abnormal movement of dystonia as neural circuit disorders involving basal ganglia, thalamus and cortex. Genotype-phenotype correlation has also failed to establish any relation [34].

Limitations

This study has few limitations. Moreover, since this is a tertiary care centre, we usually receive referrals of complicated cases, and thus this data may not reflect the true picture of NWD in the community. For logistic reason, we could not perform genetic study, though previous study has shown lack of phenotypic-genotypic correlation among local NWD population [6]. In our study we have excluded few cases of KF ring negative (about four) which had low ceruloplasmin and increase of 24 hour urinary excretion, to maintain homogeneity. Lower age of inclusion criteria may have caused missing cases, since upper age limit of Wd cases have been described upto 72 years.

Conclusion

In conclusion WD may present with a wide variety of movement disorders of hypokinetic and hyperkinetic types, the commonest being dystonia followed by Parkinsonism and tremor. Ataxia, chorea, myoclonus, stereotypies and other types of movement disorders are less commonly seen. Some movement disorders, which have previously been noted infrequently, such as tics and akathisia, were observed in higher frequency indicating better observation capacity of movement disorder specialist. Imaging showed a few correlations not previously described, such as correlation of caudate lesions with jaw opening and truncal dystonia, putaminal lesions with resting tremors, pontine and mid-brain lesions in akathisia and tics. As the presentations of NWD may be varied and atypical, these possibilities should always be kept in mind when examining a young and adult patient presenting with

movement disorders. NWD is a disorder of considerable interest to treating doctor and patients since it is potentially treatable. Exact anatomical localization and clinical features is not fully revealing on imaging as well as genetic studies. This remains a future challenge in WD.

Acknowledgement

We are grateful to Dr. Oksana Suchowersky, Professor of Medicine and Medical Genetics, Toupin Research Chair in Neurology, University of Alberta, Edmonton, Canada for reviewing this manuscript and providing useful suggestions. I am obliged to Mr Siddhartha Das, MS for literary support. We are also indebted to families of patients with WD who have given permission for investigation, subsequent treatment and publication.

References

1. Loudianos G, Gitlin JD (2000) Wilson's disease. *Semin Liver Dis* 20: 353-364.
2. Das SK, Roy K (2006) Wilson's disease: an update. *Nature Clinical Practice Neurology* 2: 482-493.
3. Ala A, Borjigin J, Rochwarger A, Schilsky M (2005) Wilson disease in septuagenarian siblings: raising the bar for diagnosis. *Hepatology* 41: 668-670.
4. Prashanth LK, Taly AB, Sinha S, Arunodaya GR, Swamy HS (2004) Wilson's disease: diagnostic errors and clinical implications. *J Neurol Neurosurg Psychiatry* 75: 907-909.
5. Wilson SAK (1912) Progressive lenticular degeneration: A familial nervous disease associated with cirrhosis of the liver. *Brain* 34: 295-509.
6. Gupta A, Aikath D, Neogi R, Datta S, Basu K, et al. (2005) Molecular pathogenesis of Wilson disease: haplotype analysis, detection of prevalent mutations and genotype-phenotype correlation in Indian patients. *Human Genetics* 118: 49-57.
7. Scheinberg IH, Sternlieb I (1984) Wilson's disease. In: Smith LH (ed.), *Major Problems in Internal Medicine*. Philadelphia: WB Saunders Company 23: 1-24.
8. Clinical overview and phenomenology of movement disorders (2008) In *Principles and practice of movement disorders*. In: Jankovic J, Fahn S (eds.) [Istedn], India: Elsevier: Noida (UP), India 1-31.
9. Denny Brown D (1964) Hepatolenticular degeneration (Wilson's disease)-Two different components. *N Engl J Med* 270: 1149-1156.
10. Walshe JM, Yealland M (1992) Wilson's disease: the problem of delayed diagnosis. *J Neurol Neurosurg Psychiatry* 55: 692-696.
11. Oder W, Prayer L, Grimm G, Spatt J, Ferenci P, et al. (1993) Wilson's disease: Evidence of subgroups derived from clinical findings and brain lesions. *Neurology* 43: 120-124.
12. Kalra V, Khurana D, Mittal R (2000) Wilson's disease: early onset and lessons from a pediatric cohort in India. *Indian Pediatr* 37: 595-601.
13. Barbosa ER, Silveira-Moriyama L, Machado AC, Bacheschi LA, Rosemberg S, et al. (2007) Wilson's disease with myoclonus and white matter lesions. *Parkinsonism and Related Disorders* 13: 185-188.
14. Klier EM, Wang HY, Constantin AG, Crawford JD (2002) Midbrain control of three dimensional head orientation. *Science* 295: 1314-1316.
15. Lehericy S, Tissen MAJ, vidailhet M, Kazi R, Meunier S (2013) The anatomical basis of dystonia: current view using neuroimaging. *Movement Disorders* 28: 944-995.
16. Barbosa ER, Caramelli P, Bacheschi LA, Haddad MS, Magalhães AC, et al. (1993) Wilson's disease: magnetic resonance imaging (MRI) with clinical correlation in 16 cases. *Rev Paul Med* 111: 407-11.
17. Sinha S, Taly AB, Ravishankar S, Prashanth LK, Venugopal KS, et al. (2006) Wilson's disease: cranial MRI observations and clinical correlation. *Neuroradiology* 48: 613-21.

18. Sinha S, Jha DK, Sinha KK (2001) Wilson's disease in Eastern India. *Journal of Associated Physician of India* 49: 881-884.
19. Taly AB, Meenakshi-Sundaram S, Sinha S, Swamy HS, Arunodaya GR (2007) Wilson disease. Description of 282 patients evaluated over 3 decades. *Medicine (Baltimore)* 86: 112-121.
20. Machado A, Chien HF, Deguti MM, Cançado E, Azevedo RS, et al. (2006) Neurological manifestations in Wilson's disease: Report of 119 cases. *Movement Disorders* 21: 2192-2196.
21. Jha SK, Behari M, Ahuja GK (1998) Wilson's disease: Clinical and radiological features. *Journal of Associated Physician of India* 1998 46: 602-605.
22. Singh P, Ahluwalia A, Saggar K, Grewal CS (2011) Wilson's disease: MRI features. *J Pediatric Neurosciences* 6: 27-28.
23. Stremmel W, Meyerrose K-W, Niederau C, Hefter H, Kreuzpaintner G, et al. (1991) Wilson's disease: Clinical presentation, treatment and survival. *Annals of Internal Medicine* 115: 720-726.
24. Deuschl G, Elbe RJ (2009) Essential tremor-neurodegenerative or non-degenerative disease towards a working definition of ET. *Movement Disorders* 24: 203-41.
25. Lou JS, Jankovic J (1991) Essential tremor: clinical correlates in 350 patients. *Neurology* 41: 234-238.
26. Plenz D, Kitai S (1999) A basal ganglia pace maker formed by the subthalamic nucleus and external globus pallidus. *Nature* 400: 677-682.
27. Su`dmeyer M, Saleh A, Wojtecki L, Cohnen M, Gross J, et al. (2006) Wilson's disease tremor is associated with Magnetic Resonance Imaging lesions in basal ganglia structures. *Movement Disorders* 21: 2134-9.
28. Panagariya A, Sureka RK, Sharma AK, Amit Dev, Neeraj Agarwal (2007) Wilson's disease: A study of 21 cases from north-west India. *Ann Indian Acad Neurol* 10: 255-8.
29. Starosta-Rubinstein S, Young AB, Kluin K, Hill G, Aisen AM, et al. (1987) Clinical assessment of 31 patients with Wilson's disease. Correlations with structural changes on magnetic resonance imaging. *Arch Neurol*; 44: 365-70.
30. Friedman JH (2007) Stereotypy and catatonia. In: *Parkinson's disease and movement disorders. (5edn)*, (Eds Jankovic J and Tolosa E) Philadelphia: Lippincott Williams and Wilkins 468-80.
31. Sethi KD, Morgan JC (2007) Drug-induced movement disorders. In *Parkinson's disease and movement disorders.(5edn)*, (Eds Jankovic J and Tolosa E) Philadelphia: Lippincott Williams and Wilkins 394-408.
32. Jankovic J (2007) Tics and Tourette's syndrome. In: *Parkinson's disease and movement disorders. In: Jankovic J, Tolosa E (eds.) (5edn)*, Philadelphia: Lippincott Williams and Wilkins 356-75.
33. Lio KK, Wang SY, Kony KW, Wu ZA (1991) Tongue dyskinesia as an early manifestation of Wilson Disease. *Brain Dev* 13: 451-453.
34. Mukherjee S, Dutta smazumder S, Biswas T, Jaiswal P, Sengupta M, et al. (2014) Genetic defects in Indian Wilson disease patients and genotype and phenotype correlation. *Parkinson and related disorders* 20: 75-81.